


The 24th Budapest Nephrology School

Nephrology, Hypertension, Dialysis,
Transplantation, Nephropathology

Under the Auspices of
ISN, ERA-EDTA, RPS, IFKF and ISP

26–31 August 2017

Chronic consequences of kidney ischemia

Prof. Andrzej Wiecek

Department of Nephrology, Transplantation and Internal Medicine
Medical University of Silesia, Katowice, Poland

e-mail: awiecek@sum.edu.pl


The 24th Budapest Nephrology School

Nephrology, Hypertension, Dialysis,
Transplantation, Nephropathology

Under the Auspices of
ISN, ERA-EDTA, RPS, IFKF and **ISP**

26–31 August 2017

I have no relevant financial relationship to disclose

Andrzej Wiecek

Two forms of renal artery leasions

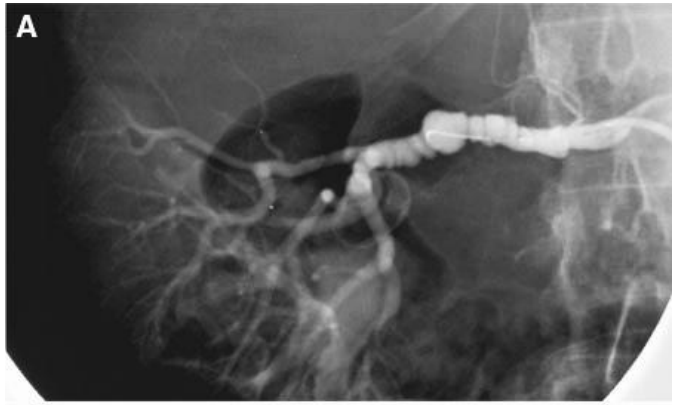

A, Angiogram from a patient with FMD with lesions characteristic of medial fibroplasia. The “string-of-beads” appearance typically develops in the mid portion of the vessel from circumferential webs within the vessel. These lesions may progress, particularly in smokers.

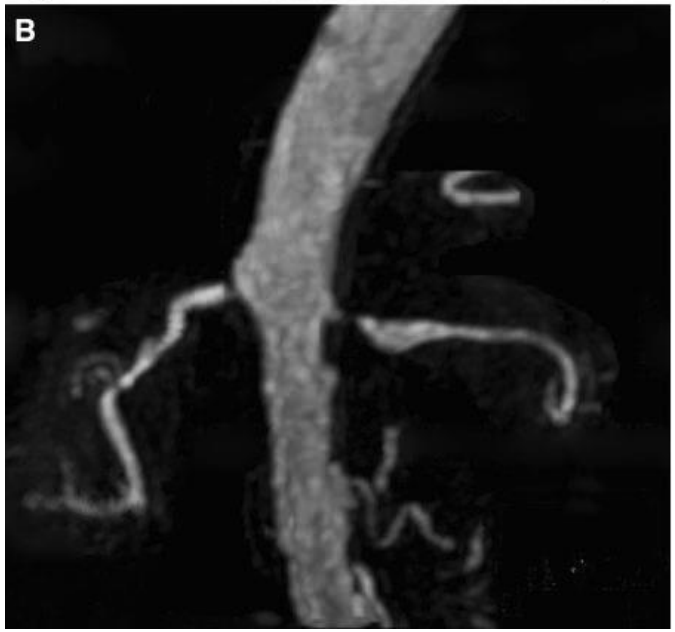

B, MRA from an individual with atherosclerotic disease affecting the renal arteries. These lesions commonly arise near the ostium of the vessel and may be an extension of aortic plaques.

Garovic V.D. and Textor S.C., Circulation. 2005; 112: 1362-1374

Schematic summary of the clinical manifestations of renovascular disease

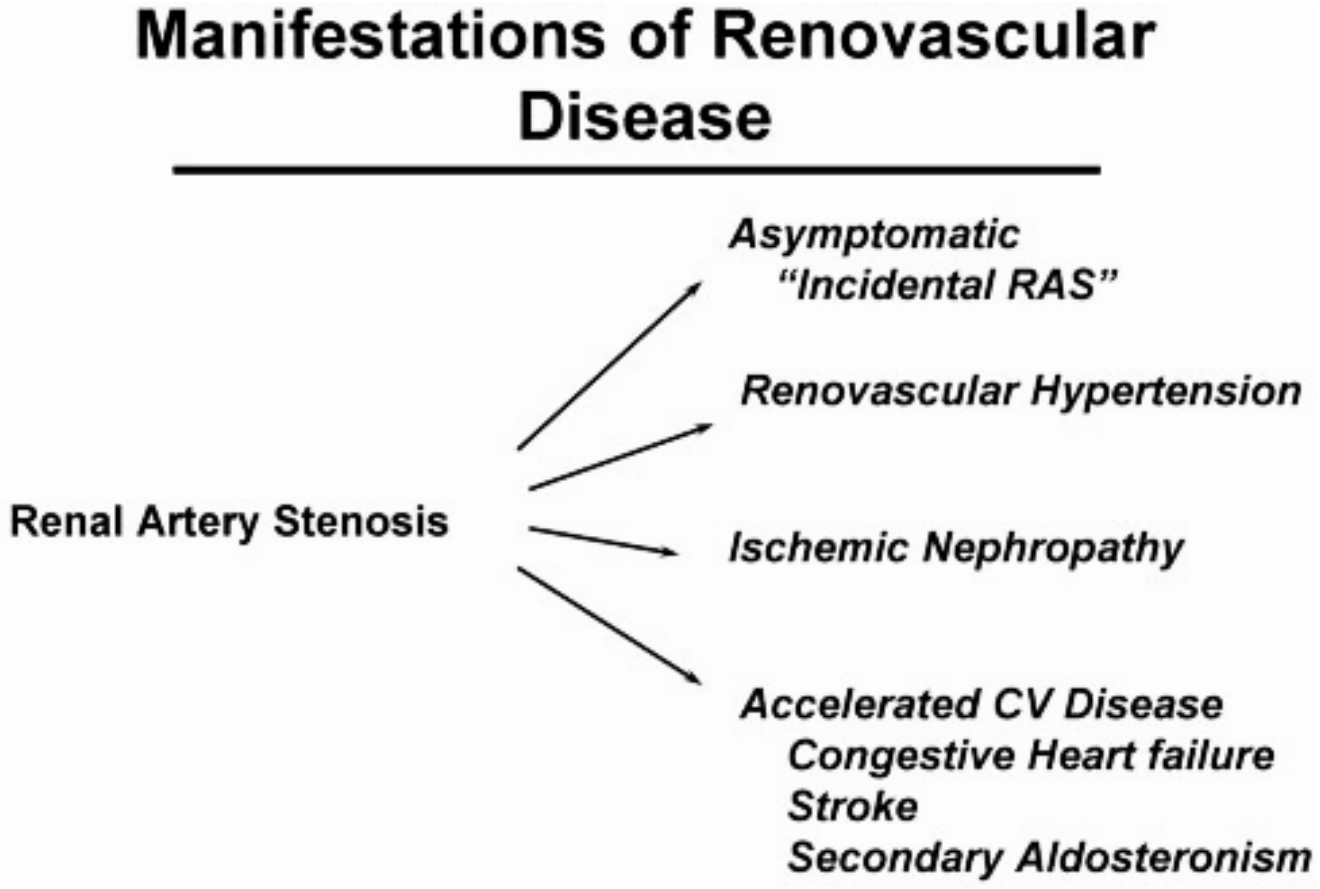

Garovic V.D. and Textor S.C., Circulation. 2005; 112: 1362-1374

Schematic summary of the clinical manifestations of renovascular disease

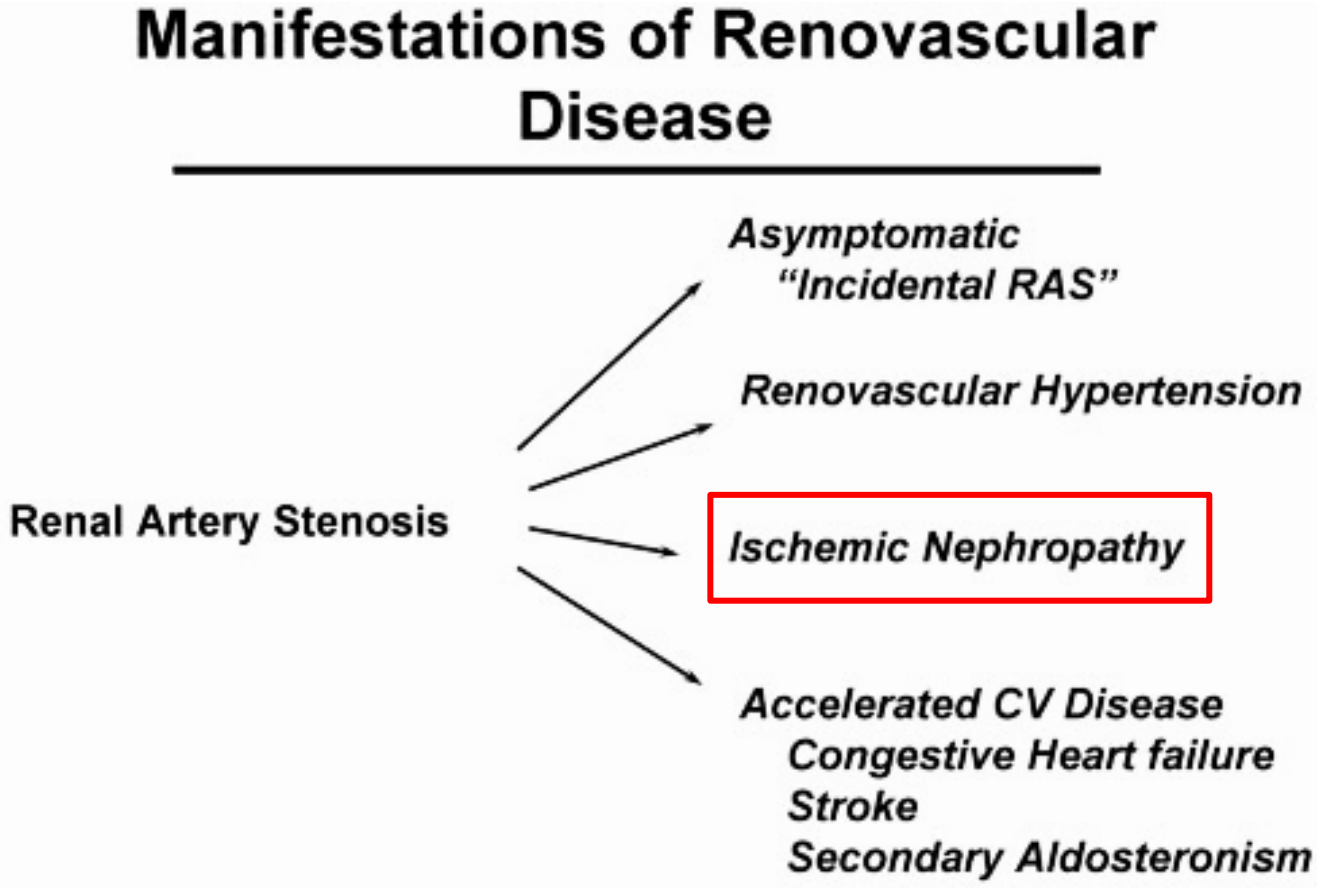

Garovic V.D. and Textor S.C., Circulation. 2005; 112: 1362-1374

Spectrum of renovascular disease manifestations

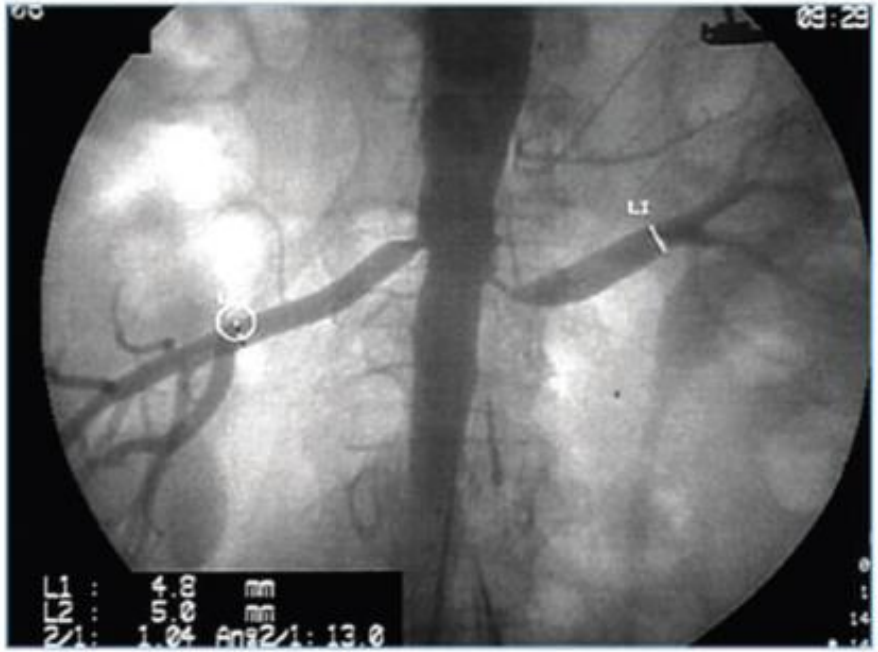

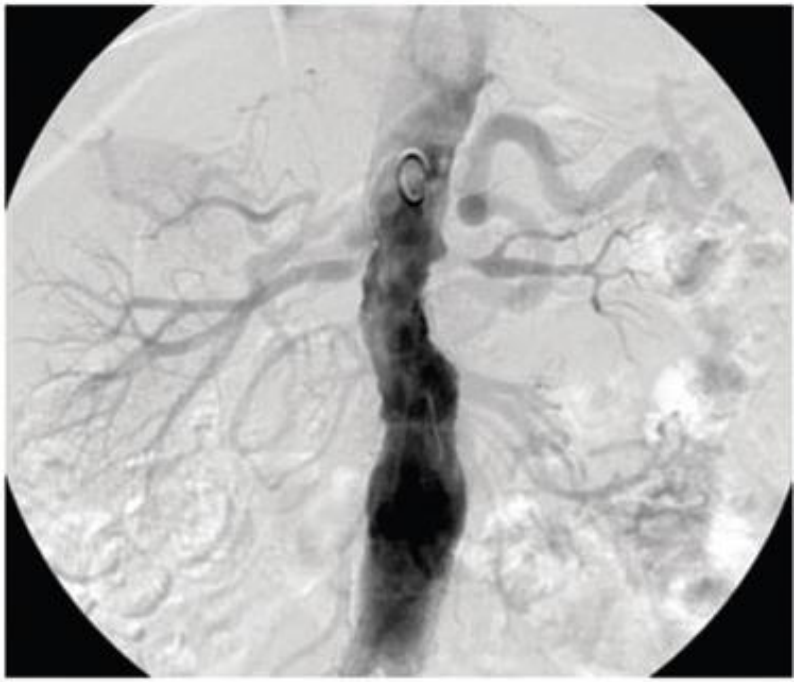

Asymptomatic
"Incidental RAS"

Renovascular
Hypertension

Accelerated CV Disease
Congestive Heart failure
Stroke

Ischemic Nephropathy

Herrmann S.M.S., Saad A., Stephen C. Textor S.C, Nephrol. Dial. Transplant., 2015, 30: 366–375

UNILATERAL RENAL ARTERY STENOSIS

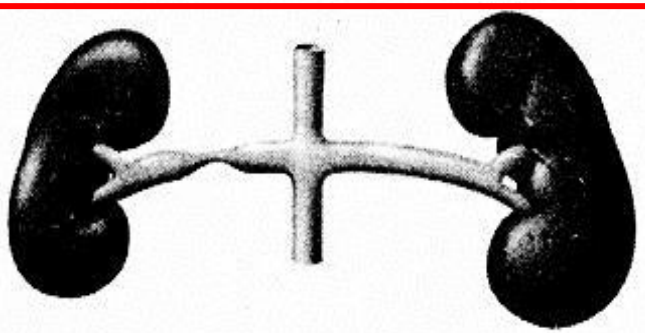

Reduced renal perfusion

↓

↑ Renin-angiotensin system (RAS)
↑ Renin
↑ Angiotensin II
↑ Aldosterone

↓

Angiotensin II–dependent hypertension

Increased renal perfusion

↓ Suppressed RAS

↓ Increased Na^+ excretion (pressure natriuresis)

Effect of blockade of RAS

Reduced arterial pressure

Enhanced lateralization of diagnostic tests

Glomerular filtration rate (GFR) in stenotic kidney may fall

Diagnostic tests

Plasma renin activity elevated

Lateralized features, e.g., renin levels in renal veins, captopril-enhanced renography

Pressor mechanisms identified in renovascular hypertension

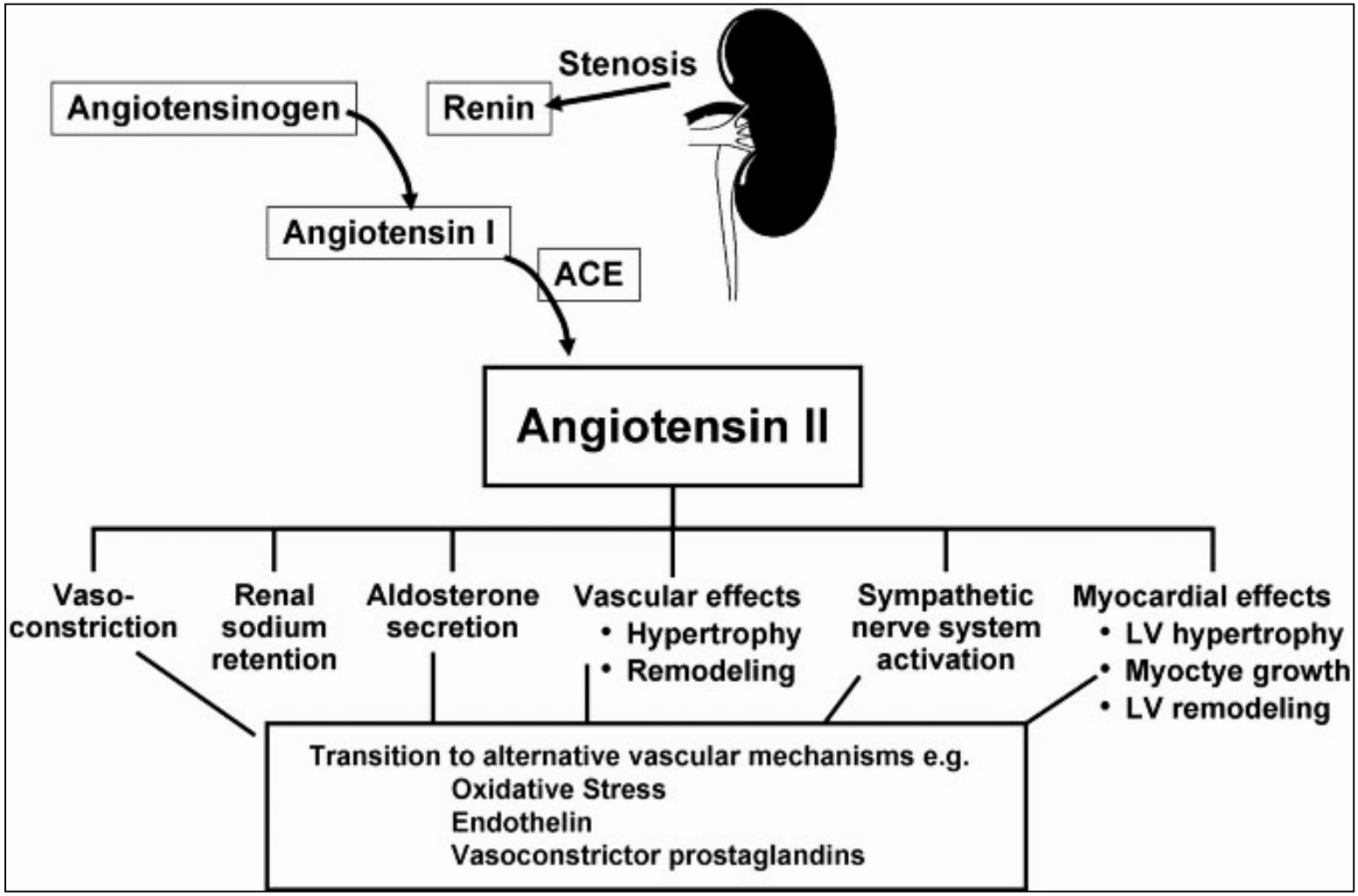

Garovic V.D. and Textor S.C., Circulation. 2005; 112: 1362-1374

BILATERAL RENAL ARTERY STENOSIS

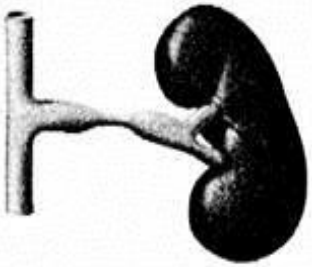

Bilateral

Stenosis of solitary kidney

Reduced renal perfusion

↑ Renin-angiotensin system (RAS)
↑ Renin
↑ Angiotensin II
↑ Aldosterone

Impaired Na^+ and water excretion

Inhibit RAS

Volume expansion

Normal or low angiotensin II

Increased arterial pressure

Effect of blockade of RAS

Reduced arterial pressure only after volume depletion

May lower GFR

Diagnostic tests

Plasma renin activity normal or low

Lateralized features: none

Measured fall in arterial pressure and blood flow across stenotic vascular lesion induced in experimental animals

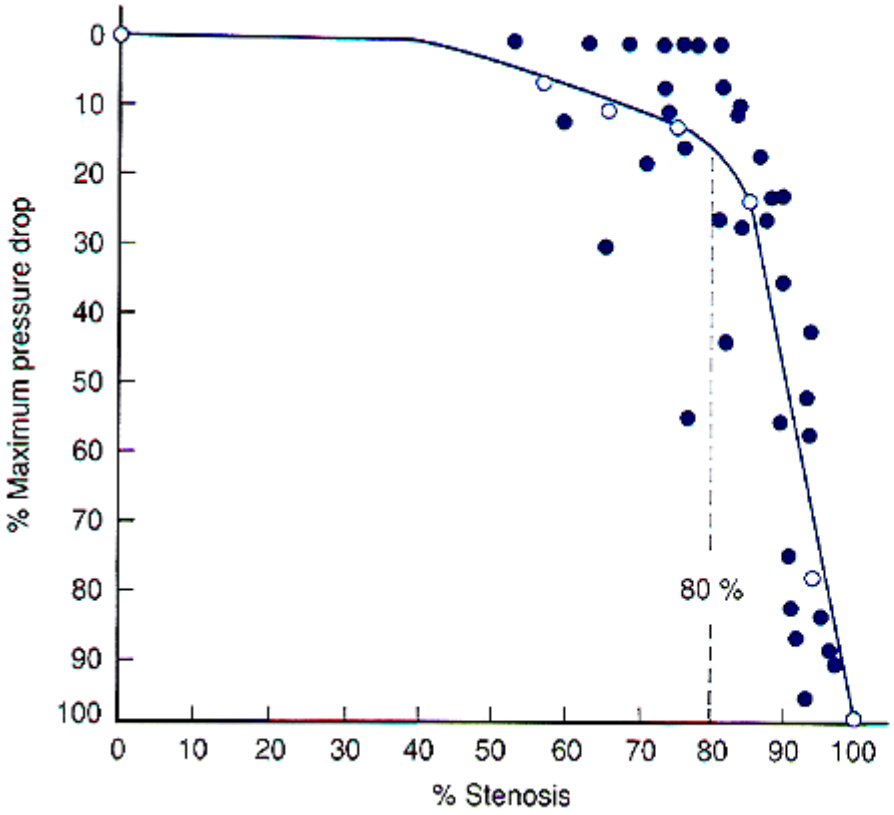

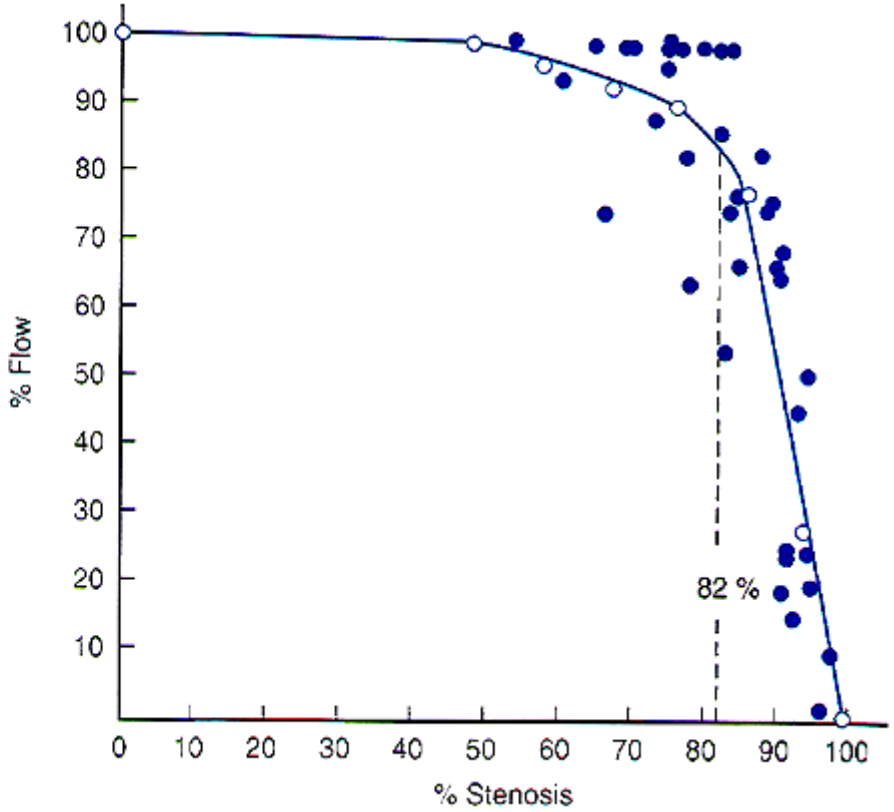

May AG. et al.: Surgery, 1963, 54, 250-259

Measured fall in arterial pressure and blood flow across stenotic vascular lesion induced in experimental animals

These data indicate that „critical" lesions require 70-80% luminal obstruction before hemodynamic effects can be detected

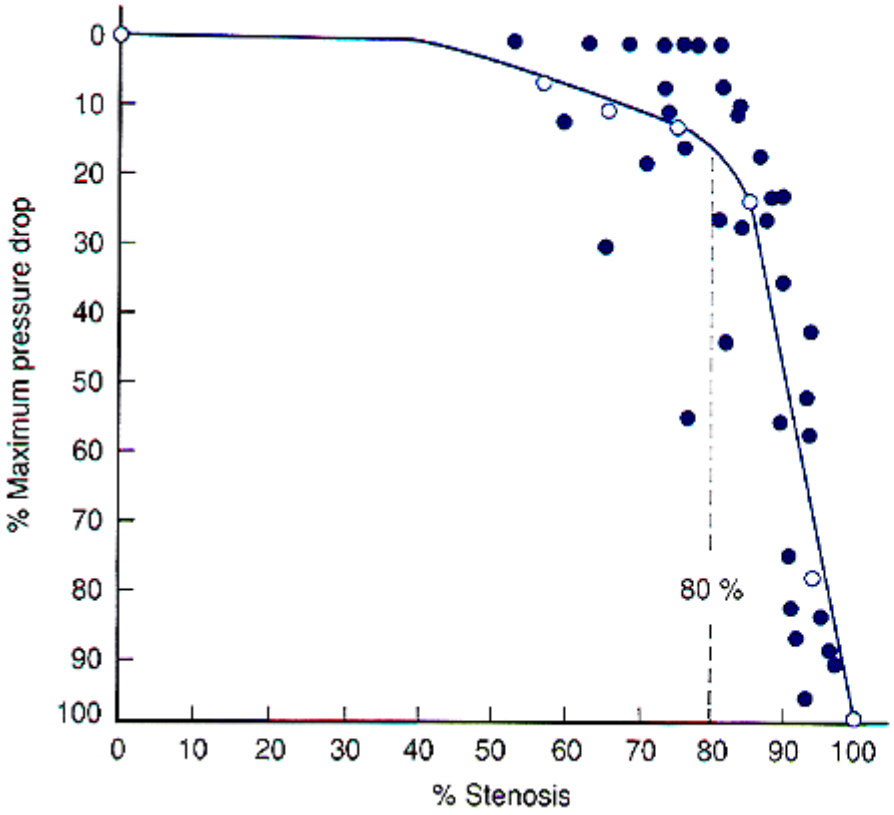

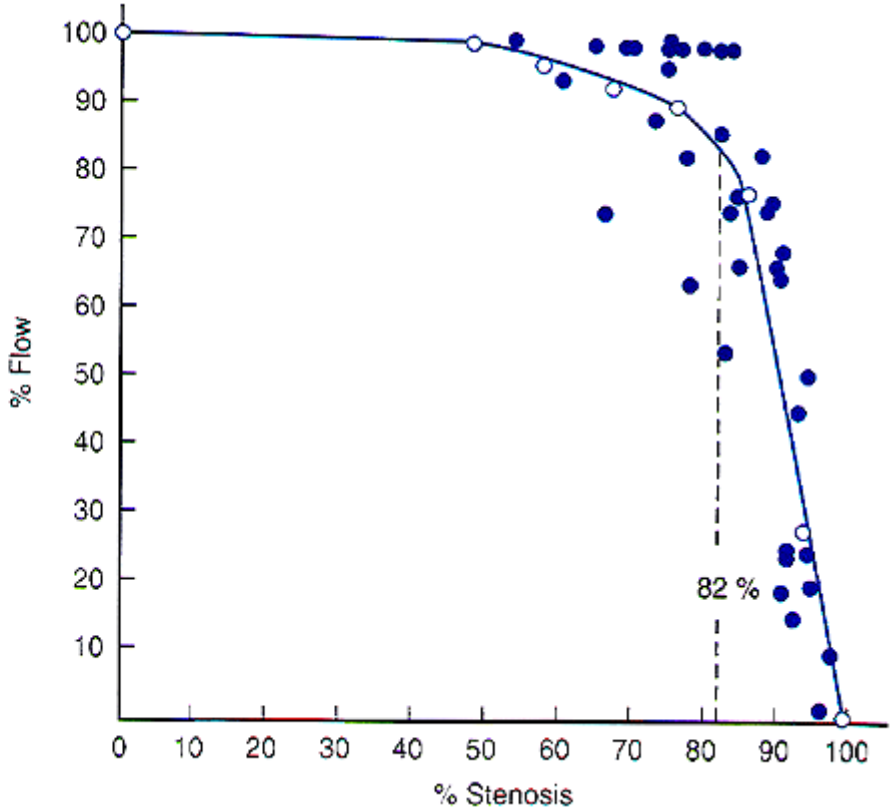

May AG. et al.: Surgery, 1963, 54, 250-259

Hemodynamic consequences of renal artery stenosis (MRI method)

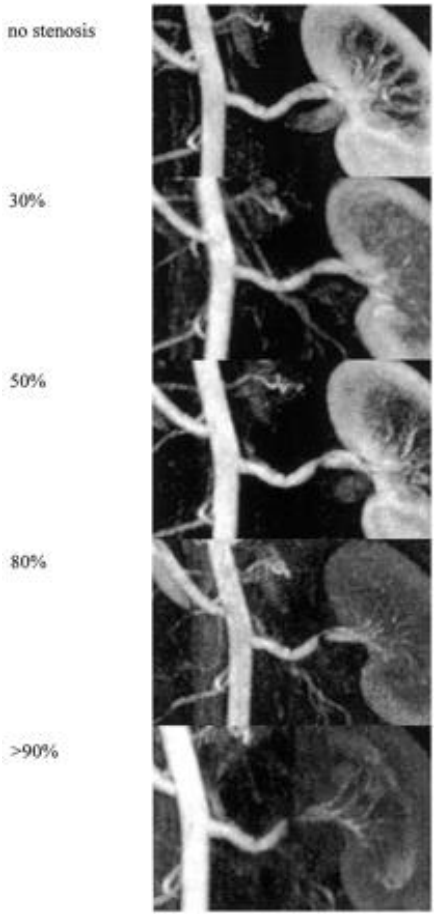

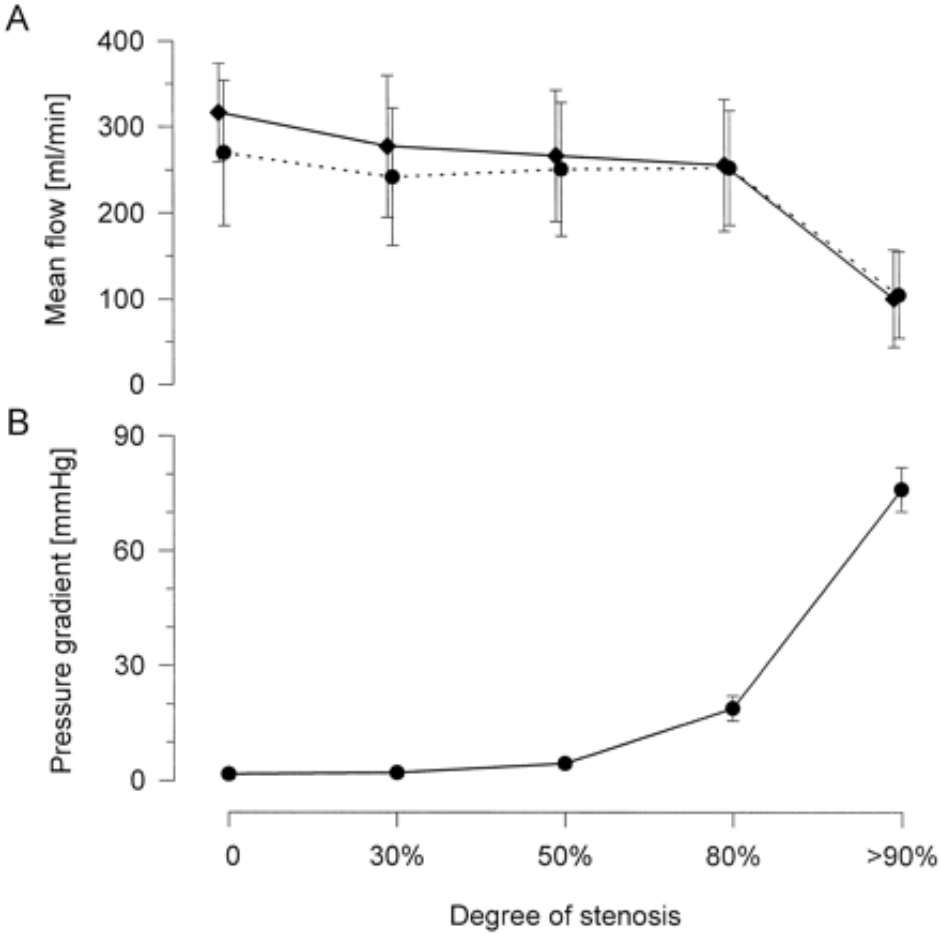

Schoenberg SO, Bock M, Kallinowski F, Just A. J Am Soc Nephrol. 2000 ;12::2190-8

Depiction of phases observed in experimental renovascular hypertension

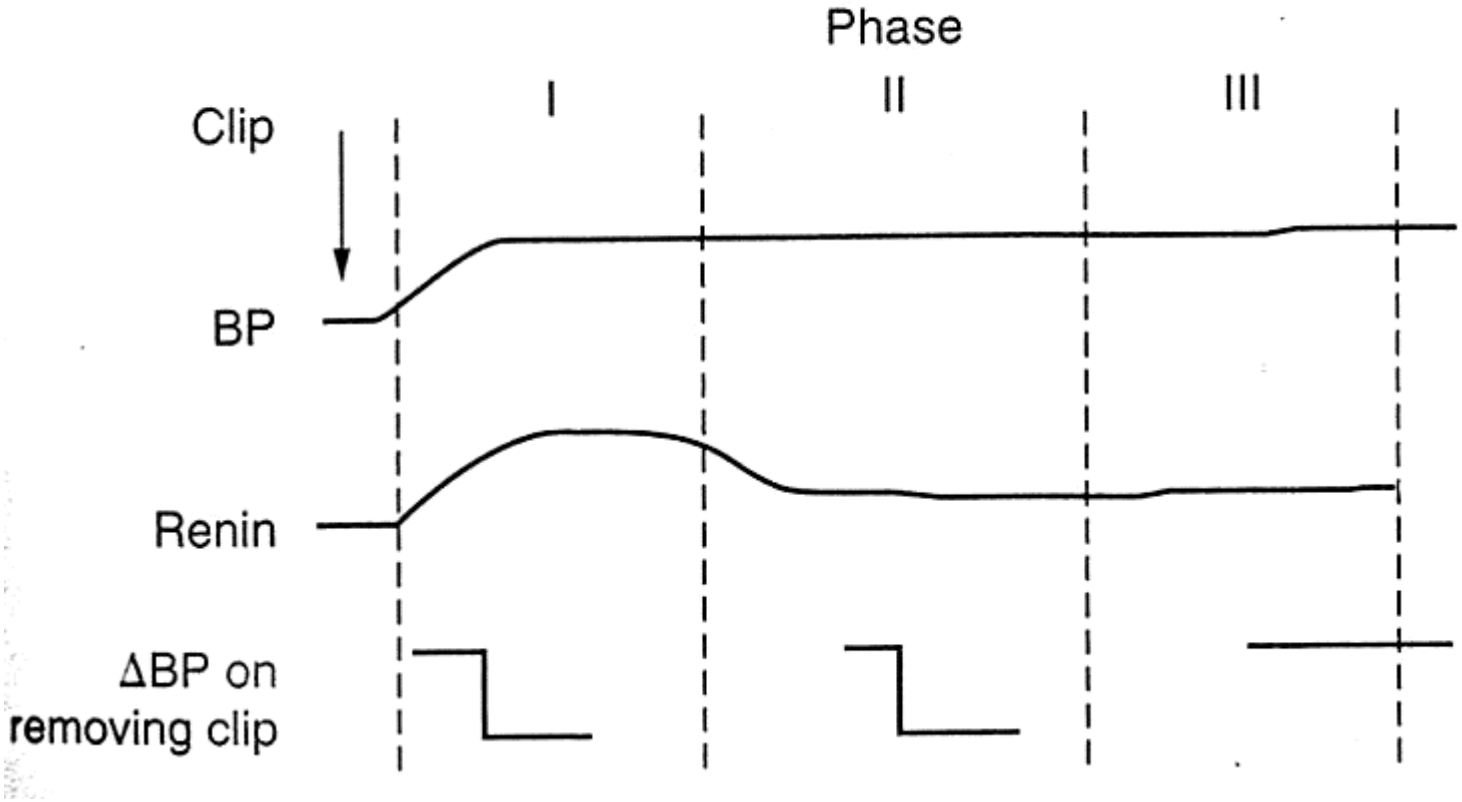

Brown J.J. et al., Lancet, 1976, 1, 1219-1221

Pathogenesis of ischemic nephropathy

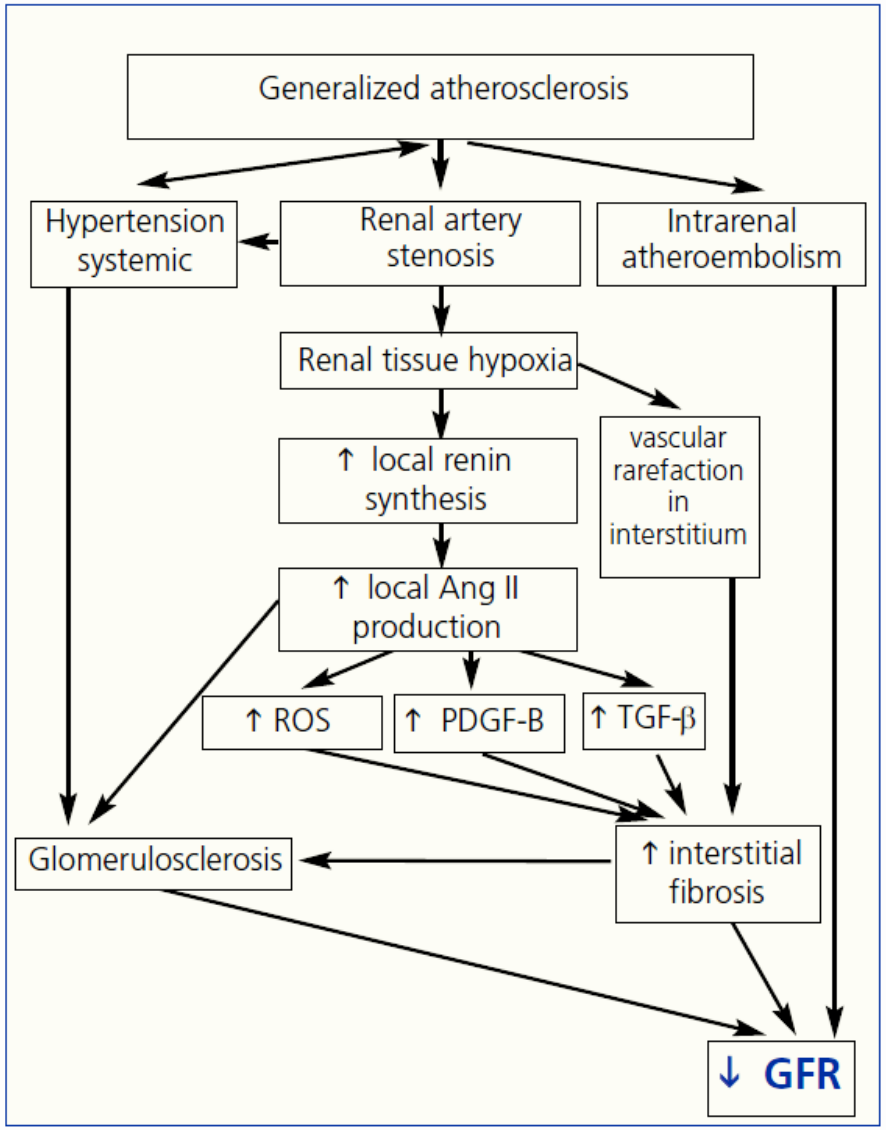

Adamczak M., Wiecek A., Nefrologia, 2012;32:432-438

Leading European Nephrology

At the early stage of renal injury, compensatory mechanisms induce MV proliferation, but abnormal MV structure and function, continuous oxidative stress, and accumulation of extracellular matrix (ECM) subsequently result in MV loss

Chronic renal ischemia

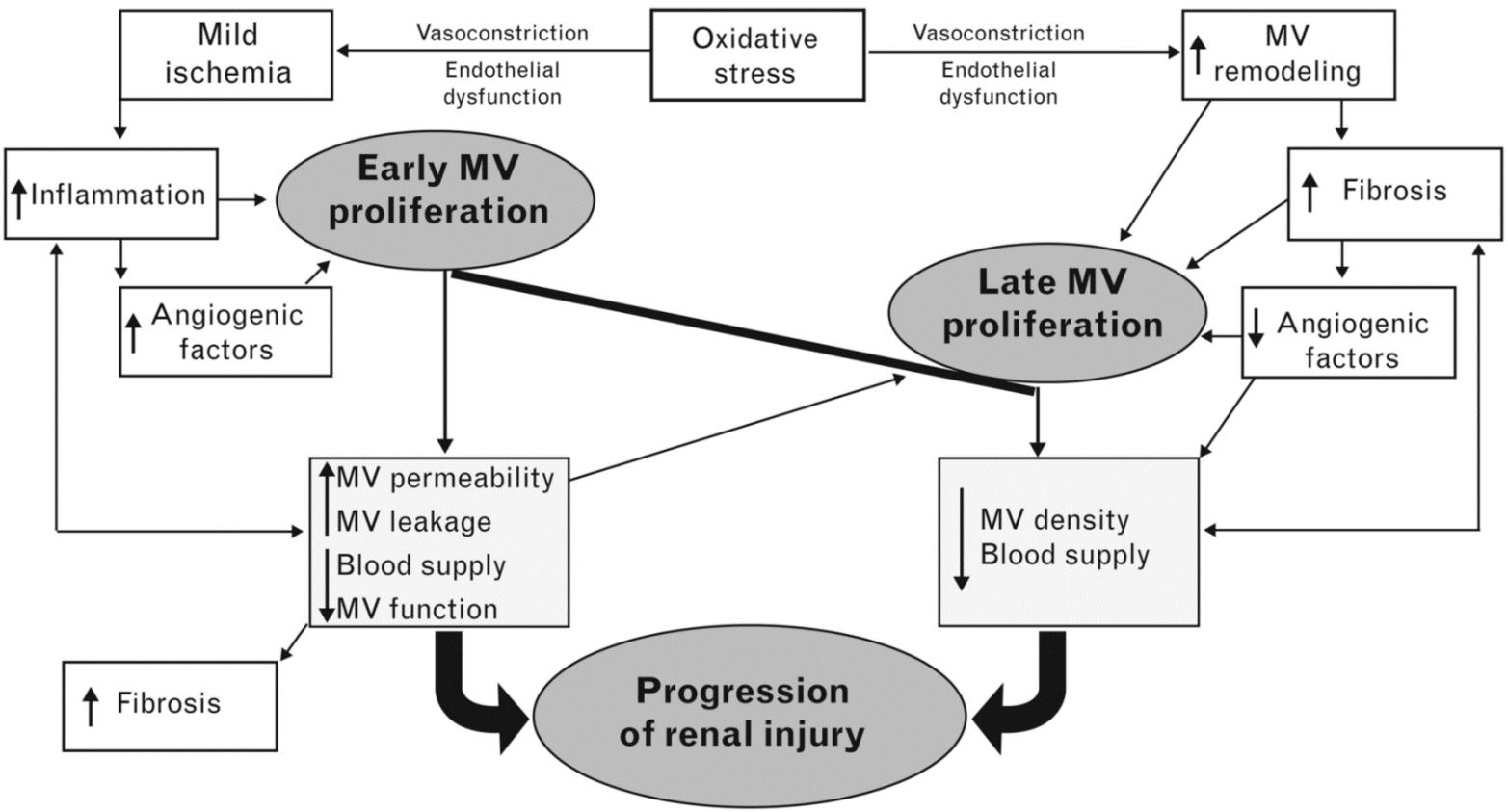

Lerman L.O. and Chade A. R. , Curr. Opin. Nephrol. Hypertens., 2009; 18: 160–165

Three-dimensional tomographic images of the **cortical microcirculation** in sham, RAS, and RAS + PTRA pigs

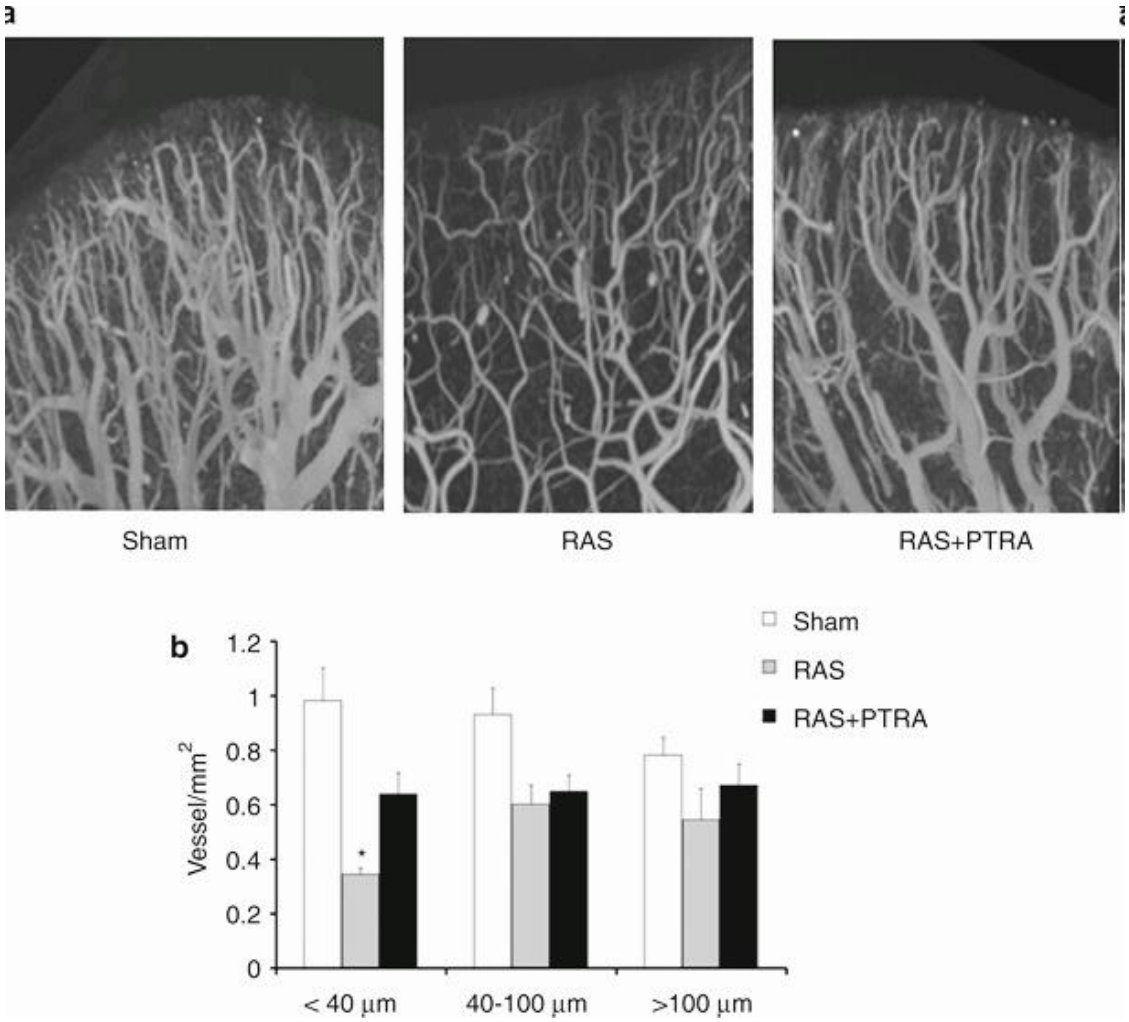

Favreau F.D. et al., Kidney Int.; 2010 78, 1110–1118

Representative three-dimensional reconstruction of the renal microvascular architecture (using microcomputed tomography) and renal morphology (trichrome staining) showing opposing changes in microvascular architecture in early atherosclerosis compared with chronic ischemia

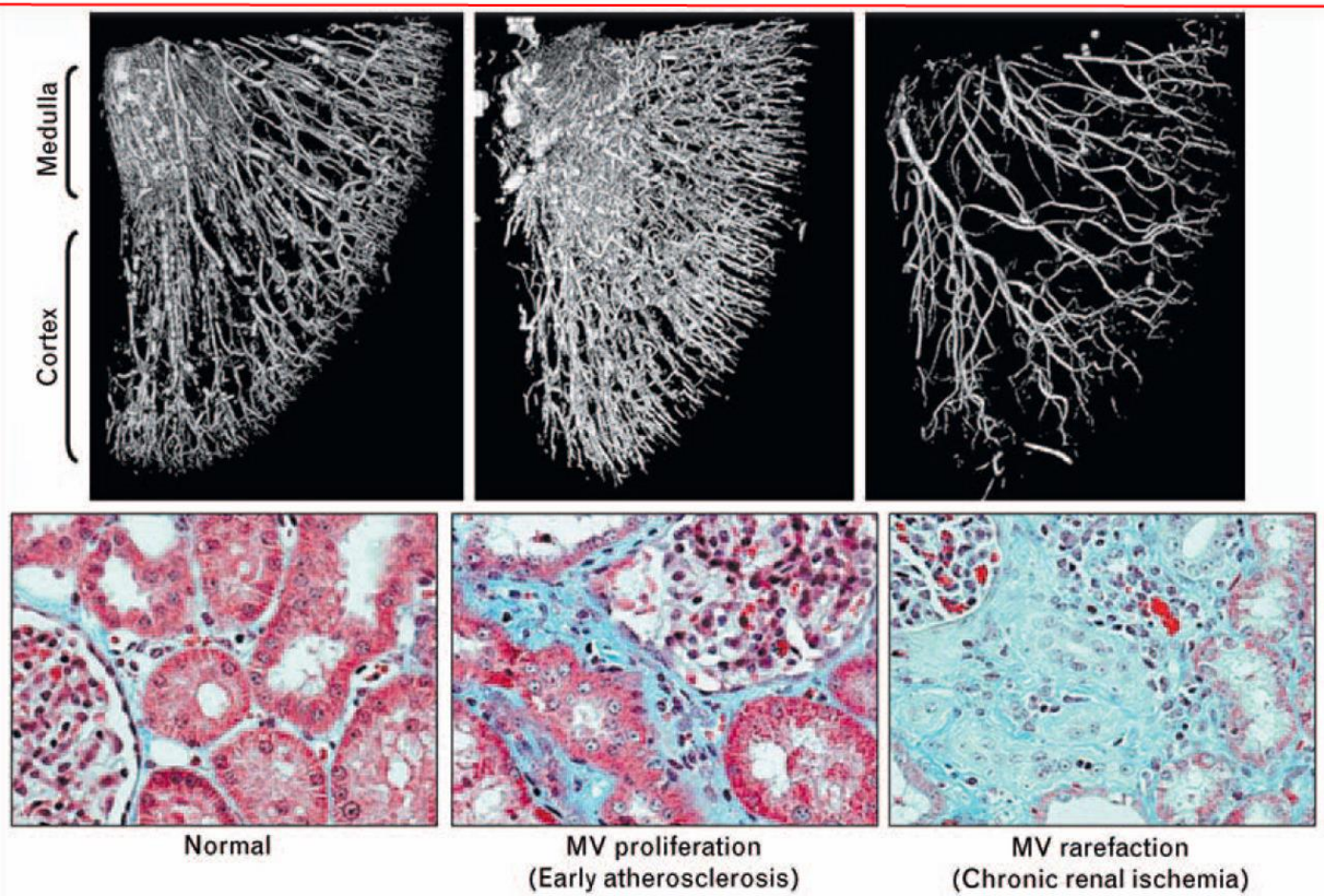

Microvascular rarefaction in particular is accompanied by severe renal fibrosis

Lerman L.O. and Chade A. R. , Curr. Opin. Nephrol. Hypertens., 2009; 18: 160–165

Leading European Nephrology

Representative microcomputed tomography images showing the intrarenal microvasculature in lean, obese, renal artery stenosis (RAS), and obese RAS pigs. Microvascular density is markedly decreased in obese RAS kidneys compared with RAS alone, suggesting aggravated microvascular loss

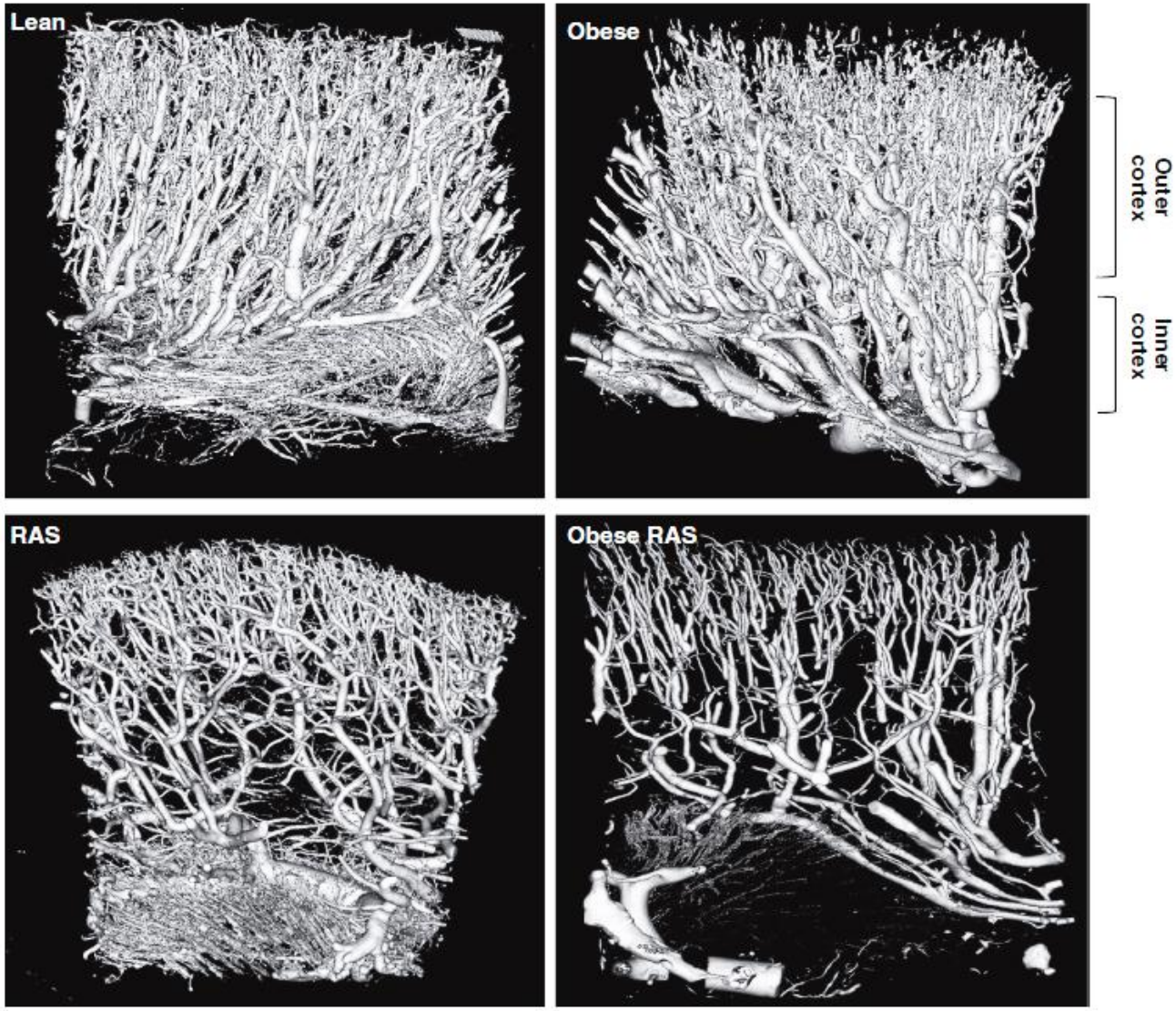

Zhang X. and Lerman L.O., Am. J. Physiol., 2015, 309: F273–F279

Potential mechanisms by which obesity promotes kidney injury in the post-stenotic kidney

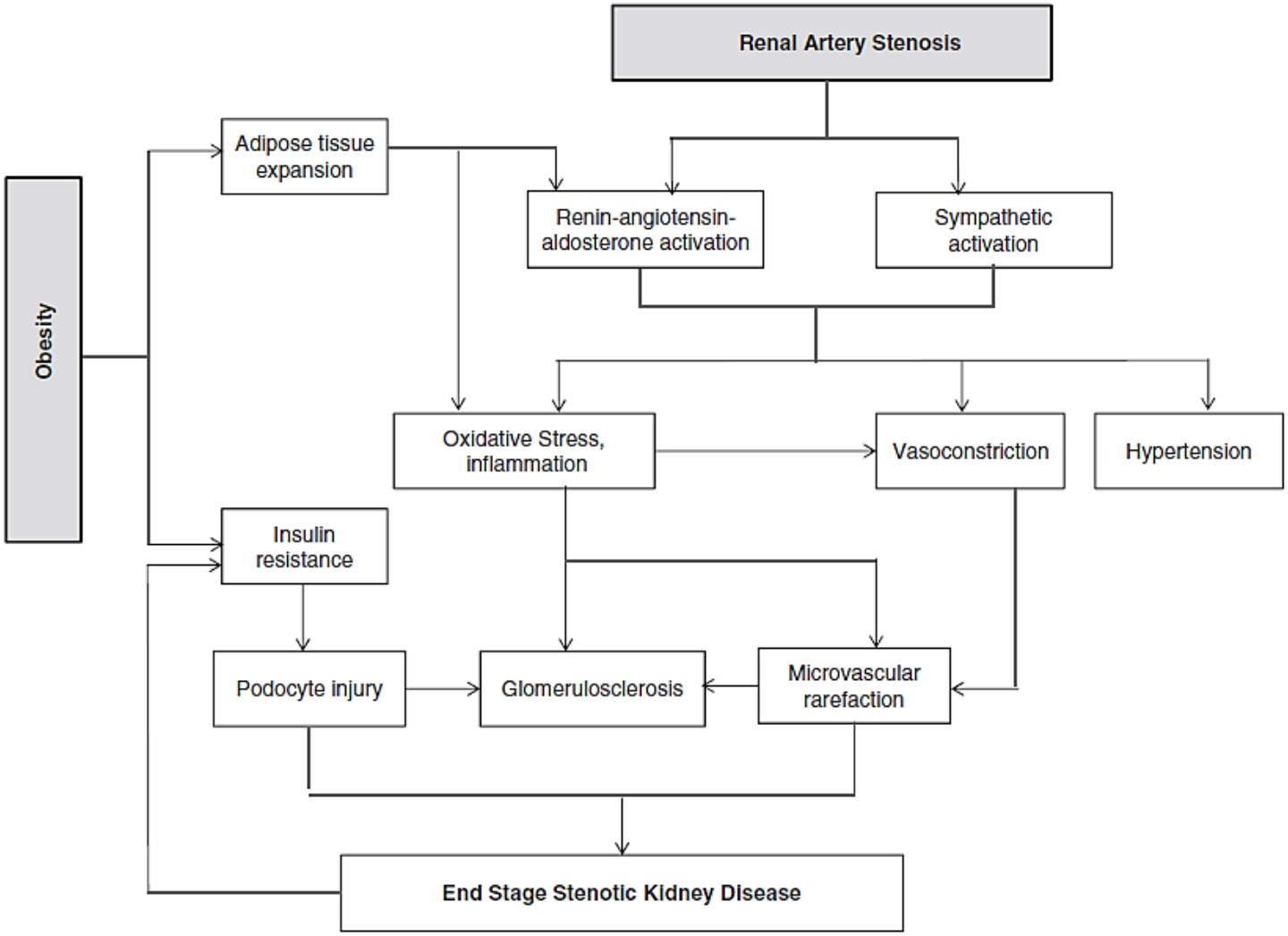

Zhang X. and Lerman L.O., Am. J. Physiol., 2015, 309: F273–F279

Leading European Nephrology

Micro-CT images of the kidney in experimental Atherosclerotic Renal Artery Stenosis (ARAS)

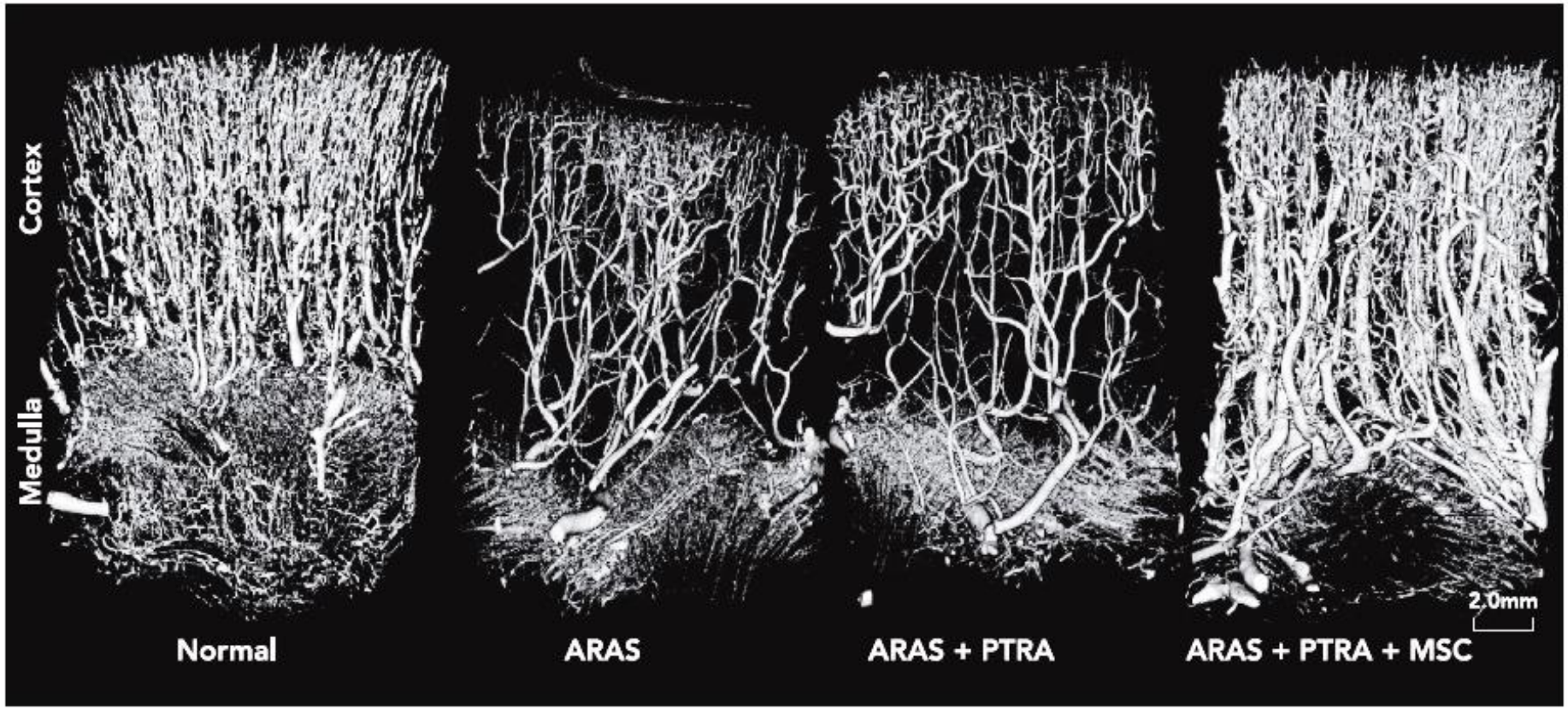

Micro-CT images of the kidney in experimental ARAS showing improved microvascular architecture in post-stenotic kidney treated **with mesenchymal stem cell (MSC)** in addition to renal revascularization.

Saad A et al. Physiology, 2015, 30: 175–182

Multiple mechanisms responsible for renal dysfunction in chronic renal artery stenosis induced by renal artery clipping model and the effects of mesenchymal stem cell (MSC) treatment

CHRONIC RENAL ARTERY STENOSIS (2K-1C)

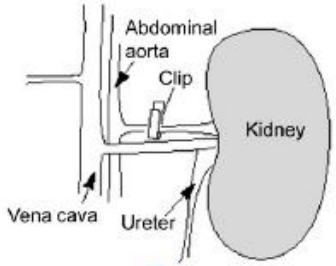

↑ Renin-Angiotensin System

↓

↑ Renal sympathetic nerve activity

↓

Hypertension

Local mechanisms:

- Microvascular loss
- Renal tissue inflammation
- Oxidative stress

↓

Renal fibrosis and dysfunction

MSCs THERAPY (IV)

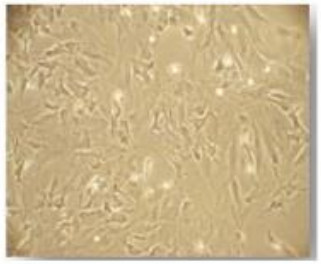

↓ Intrarenal RAS activity in stenotic kidney

↓

↓ Sympathoexcitation

↓

Prevent the progressive increase of arterial blood pressure

↓

↓ Vascular rarefaction in the stenotic kidney

↓

↓ IL-1 and TNF-alfa

↓

↑ IL-10

↓

↓ Renal fibrosis and proteinuria

Oliveira-Sales E.B. and Boim M.A., Am. J. Physiol. 2016, 310: F6–F9

Leading European
http://www.kidney-international.org
basic research

Experimental coronary artery stenosis accelerates kidney damage in renovascular hypertensive swine

Dong Sun[1,2], Alfonso Eirin[1], Xiang-Yang Zhu[1], Xin Zhang[1], John A. Crane[1], John R. Woollard[1], Amir Lerman[3] and Lilach O. Lerman[1,3]

[1]Division of Nephrology and Hypertension, Mayo Clinic, Rochester, Minnesota, USA; [2]Department of Nephrology, The Affiliated Hospital of Xuzhou Medical College, Xuzhou, China and [3]Division Cardiovascular Disease, Mayo Clinic, Rochester, Minnesota, USA

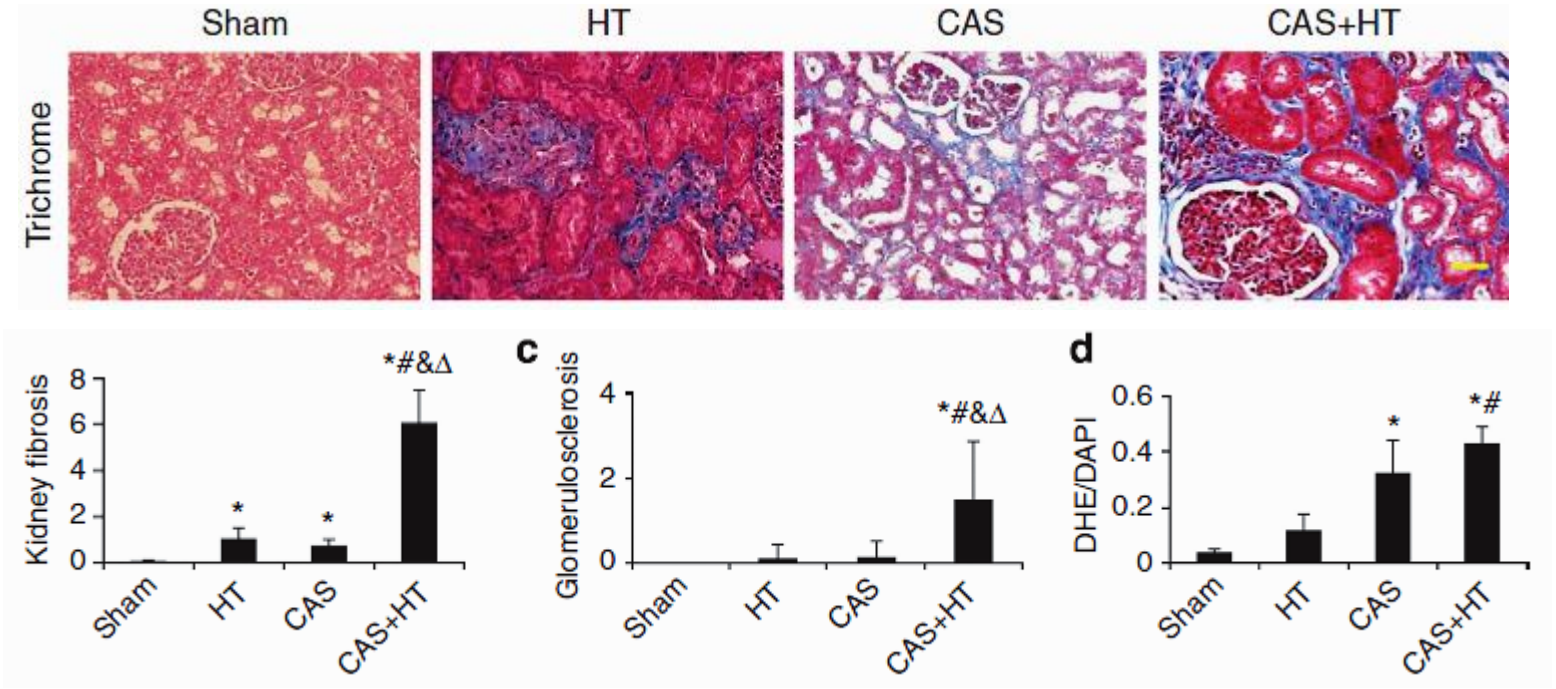

Sun D. et al., Kidney Int., 2015, 87, 719–727

Leading
European
Nephrology

Proposed mechanisms for **CD40/sCD40L signaling** in the proximal tubule contributing to the development of renal injury in atherosclerotic renal artery stenosis

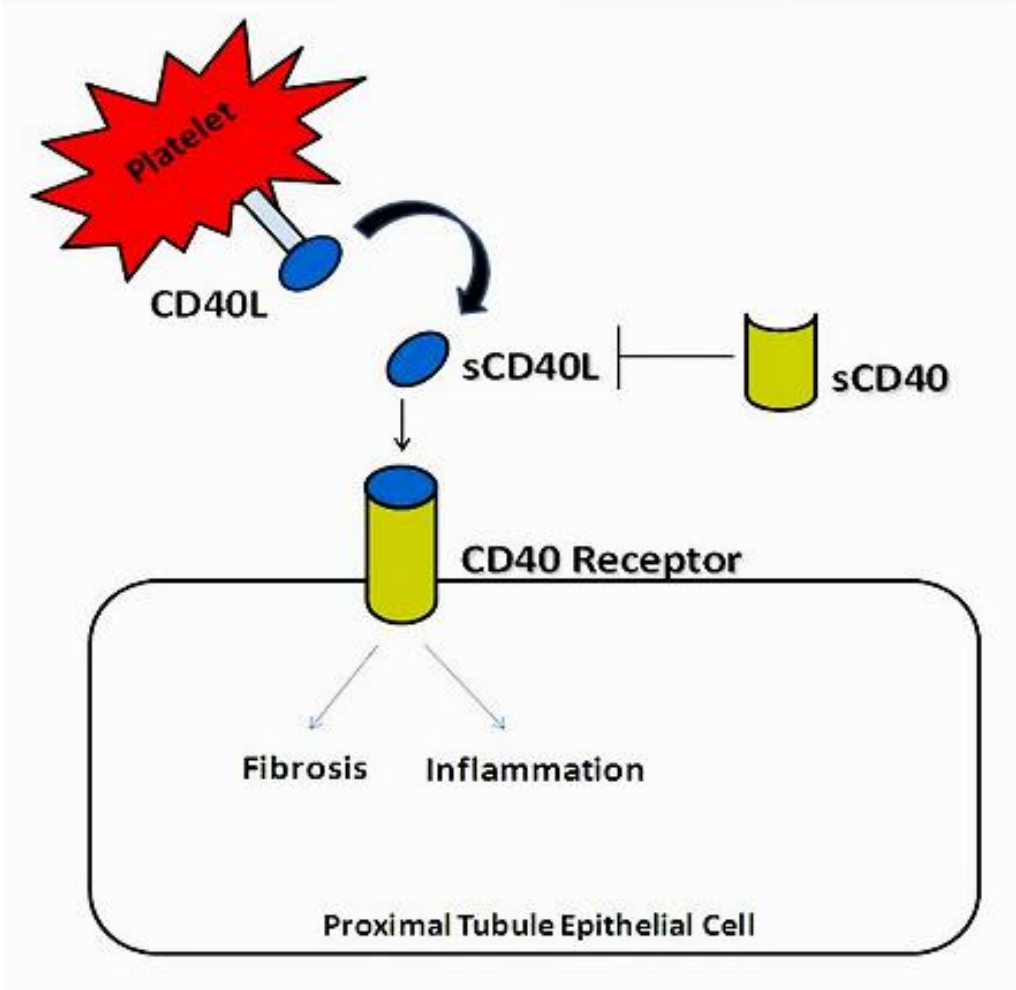

Haller S.T., Discov. Med., 2013, 16: 255-260

Schematic of multiple mechanisms responsible for renal dysfunction in renal artery stenosis

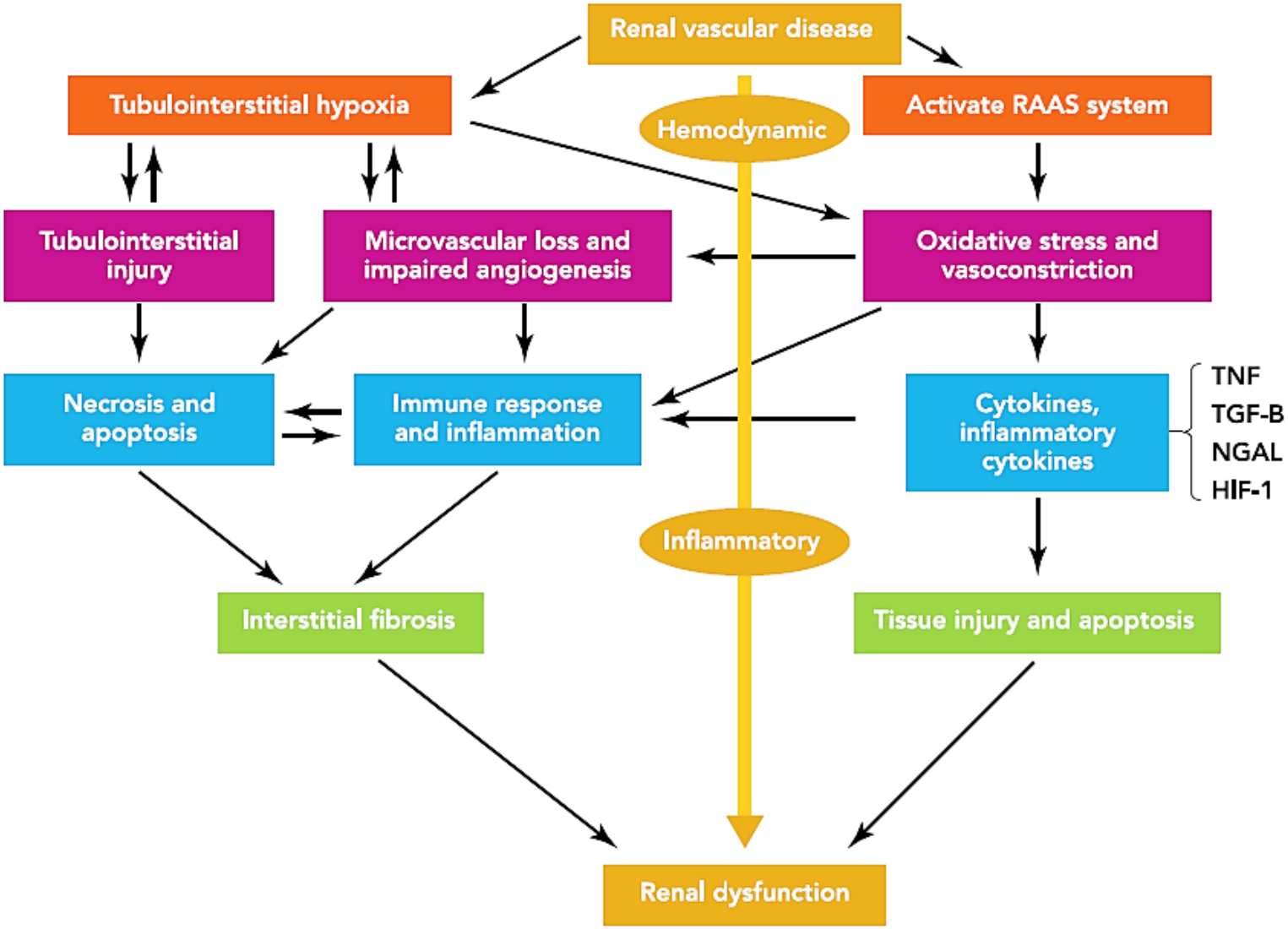

Saad A et al. Physiology, 2015, 30: 175–182

Leading European Nephrology

Oxygenation levels are lower in the stenotic kidney as compared to the nonstenotic contralateral kidney: Representative coronal blood oxygen level-dependent images

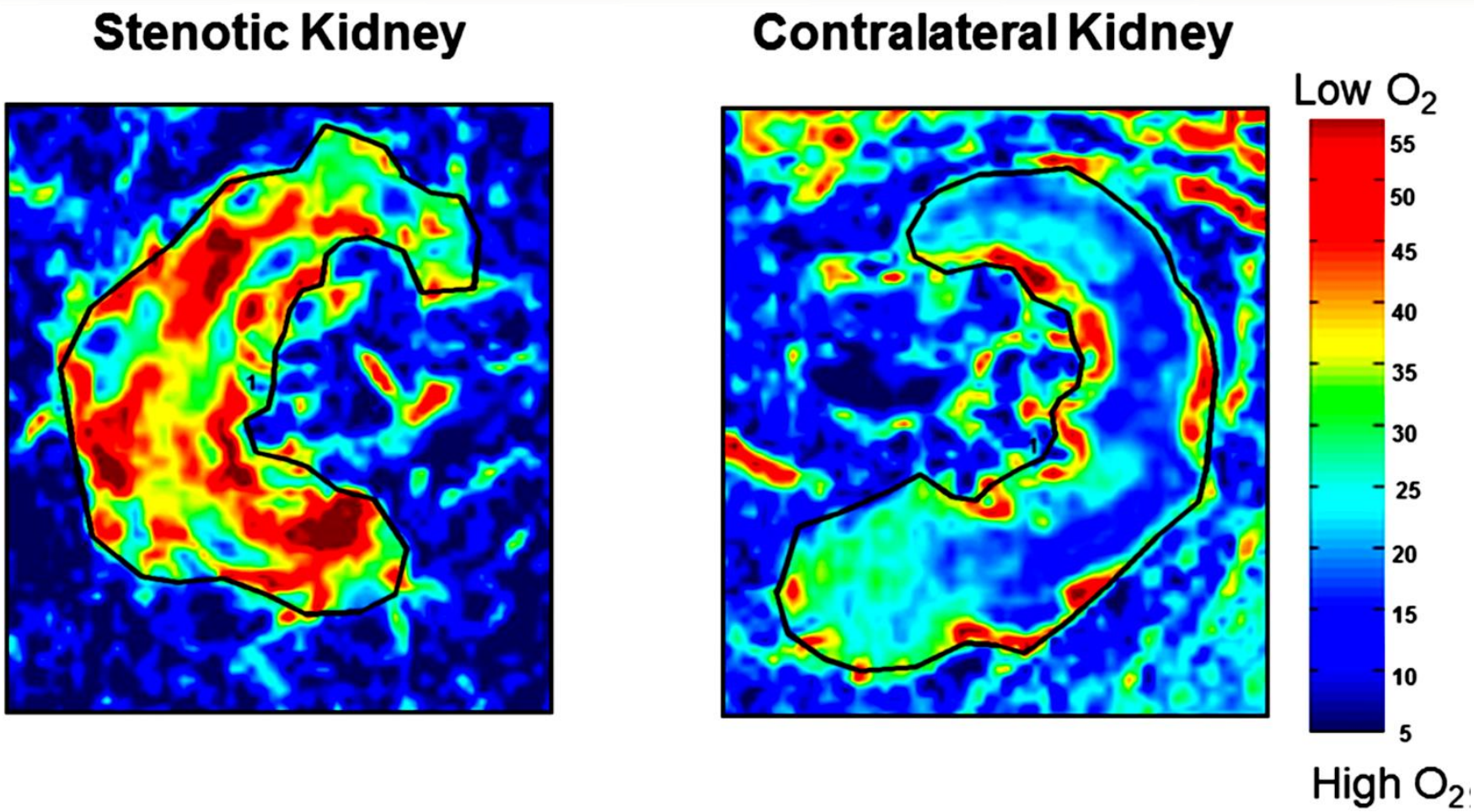

Herrmann S.M.S et al., Clin. J. Am. Soc. Nephrol., 2016, 11: 458–469

Blood Oxygen Level–Dependent (BOLD) magnetic resonance imaging technique

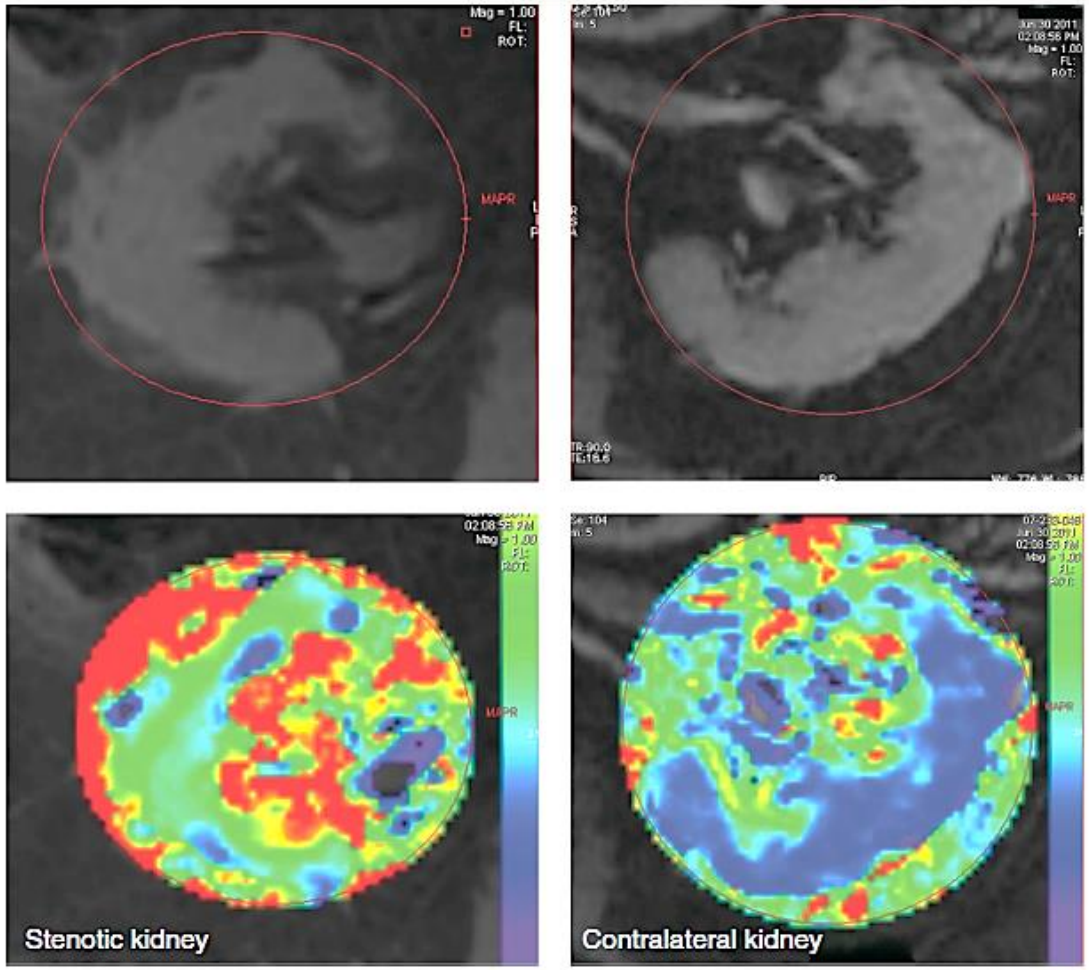

Figure 5 | Blood-oxygen-level-dependent (BOLD) magnetic resonance (MR) images with parametric maps depicting R2* levels that correspond to tissue levels of deoxyhemoglobin in axial images of the kidneys. Both of these kidneys had high-grade renal arterial stenosis with velocities >400 cm/s. Serum creatinine was >3.6 mg/dl, although the patient was treated with angiotensin receptor blockers and diuretics. The larger kidney (right panel, left kidney) has well-preserved cortical oxygenation (blue zone) and a normal corticomedullary oxygen gradient. The smaller kidney (left panels) is developing overt cortical hypoxia with rising R2* levels and expanding zone of medullary hypoxia (inner red zone). These functional imaging tools may assist in defining kidneys that are 'at risk' from critical vascular occlusion, yet remain 'salvageable' from the point of view of restoring renal blood flow (see text).

Textor S.C. et al. Kidney Int., 2012, 83, 28-40

Leading European Nephrology

CT angiographic images of the right kidneys illustrating three patients with *1*) no renal artery stenosis, *2*) moderate renal artery stenosis, and *3*) severe renal artery stenosis. Below each at *bottom* are Blood Oxygen Level-Dependent (BOLD)

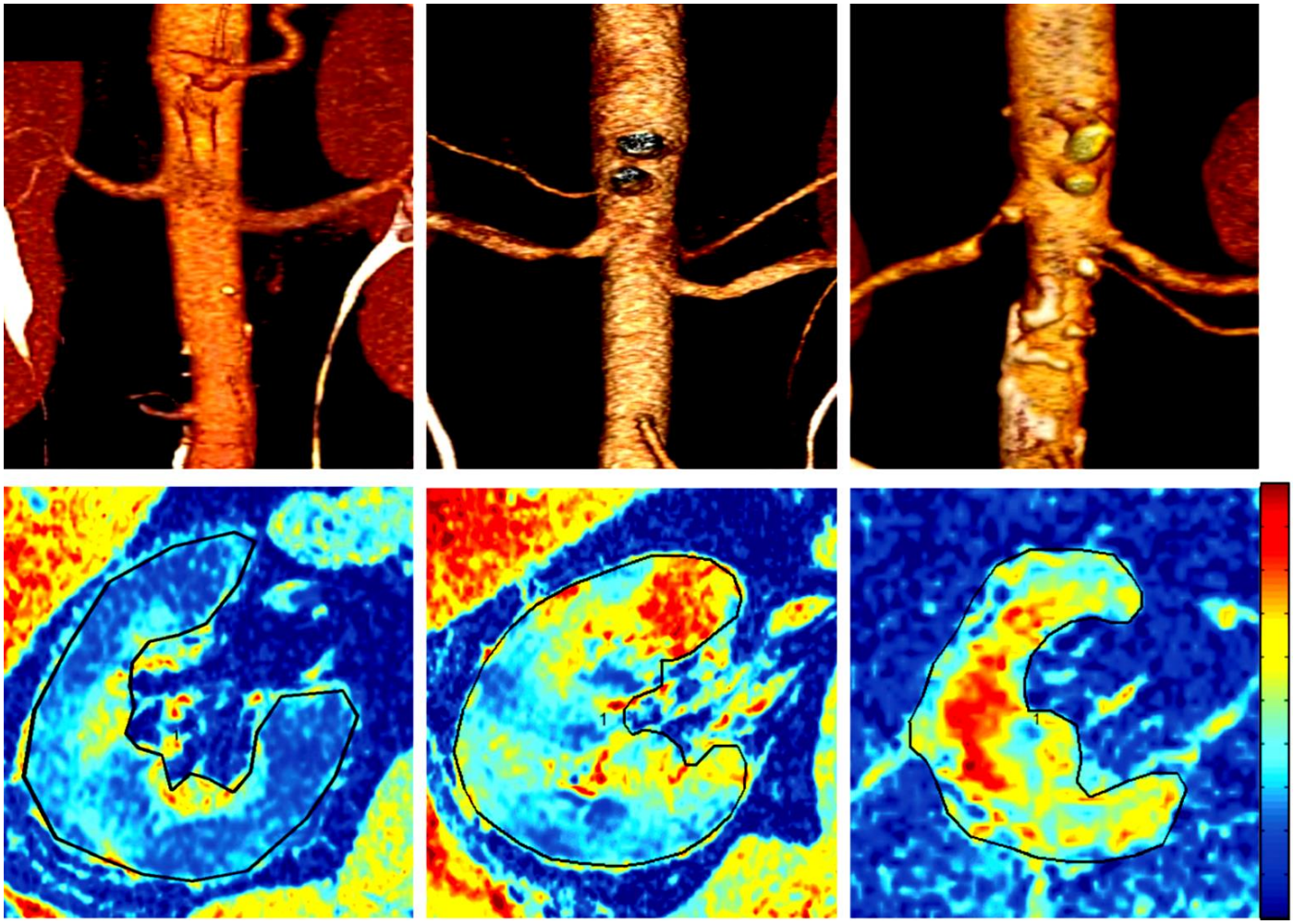

Saad A et al. Physiology, 2015, 30: 175–182

Cortical hypoxia and inflammation develop in severe Atherosclerotic Renovascular Disease (ARVD)

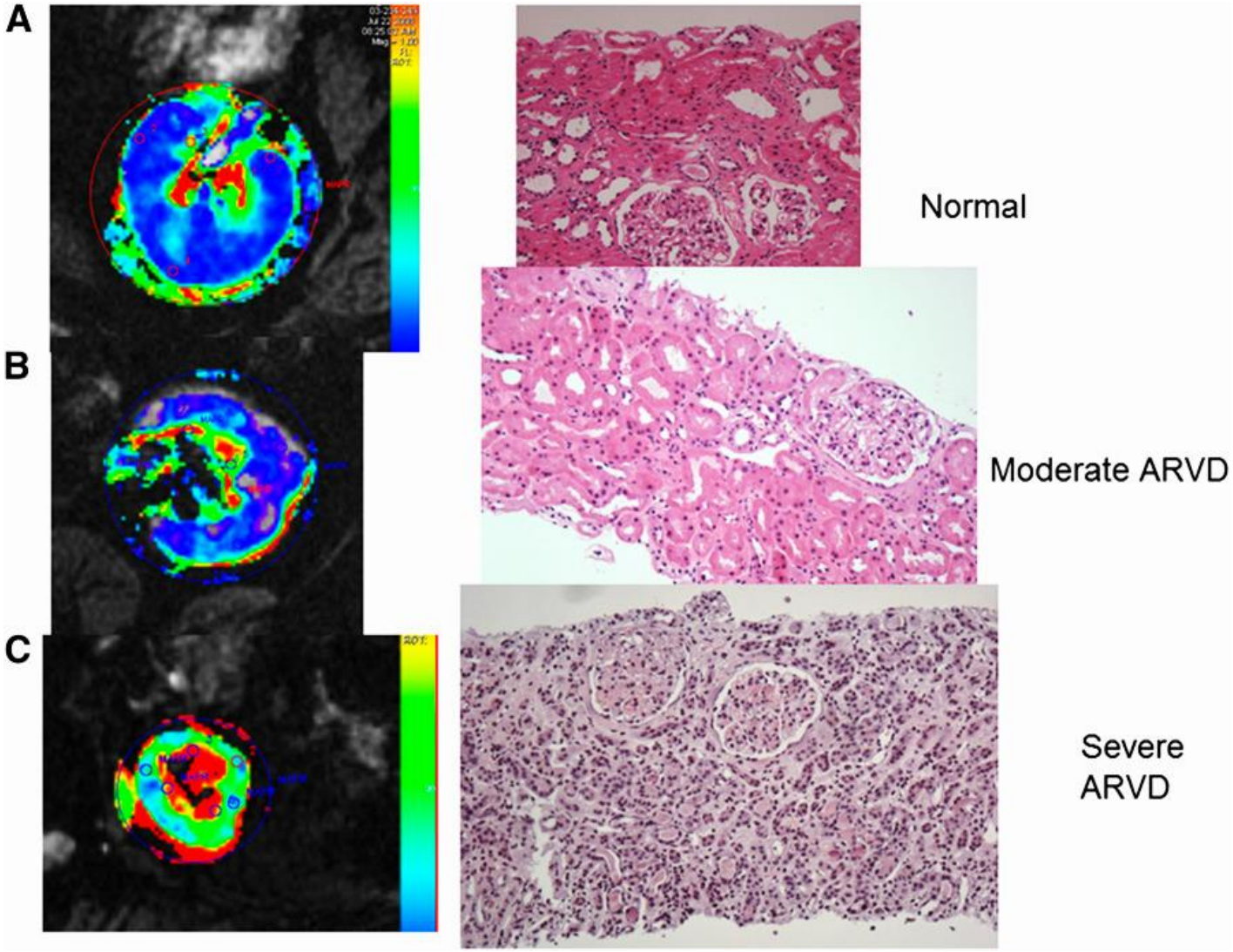

Textor S.C., and Lerman L.O., J. Am. Soc. Nephrol., 2015, 26: 2074–2080

Leading European Nephrology

Table 1. Prevalence of Atherosclerotic Renal Artery Stenosis in Different Subgroups

Subgroups	Prevalence of Atherosclerotic Renal Artery Stenosis (>60% of renal artery lumen)
General population	0.5%
Age > 65 years (Doppler)	7%
Healthy kidney donors	3-5%
Chronic kidney disease	5.5%
Suspicion of renovascular hypertension	14%
Coronary angiography	19%-24% (7% bilateral)
ESRD	12%-14% (2%-5% as cause of CKD)
Peripheral arterial disease	28%-59%
Abdominal aortic aneurysm	33%
Eldery with CHF	34%
Refractory CHF	40%-50%
Diffuse arterial disease	50%

Boehlke M. and Correa Barcellos F., Am. J. Kidney Dis., 2015, 65: 611-622

Intrarenal Doppler measurement

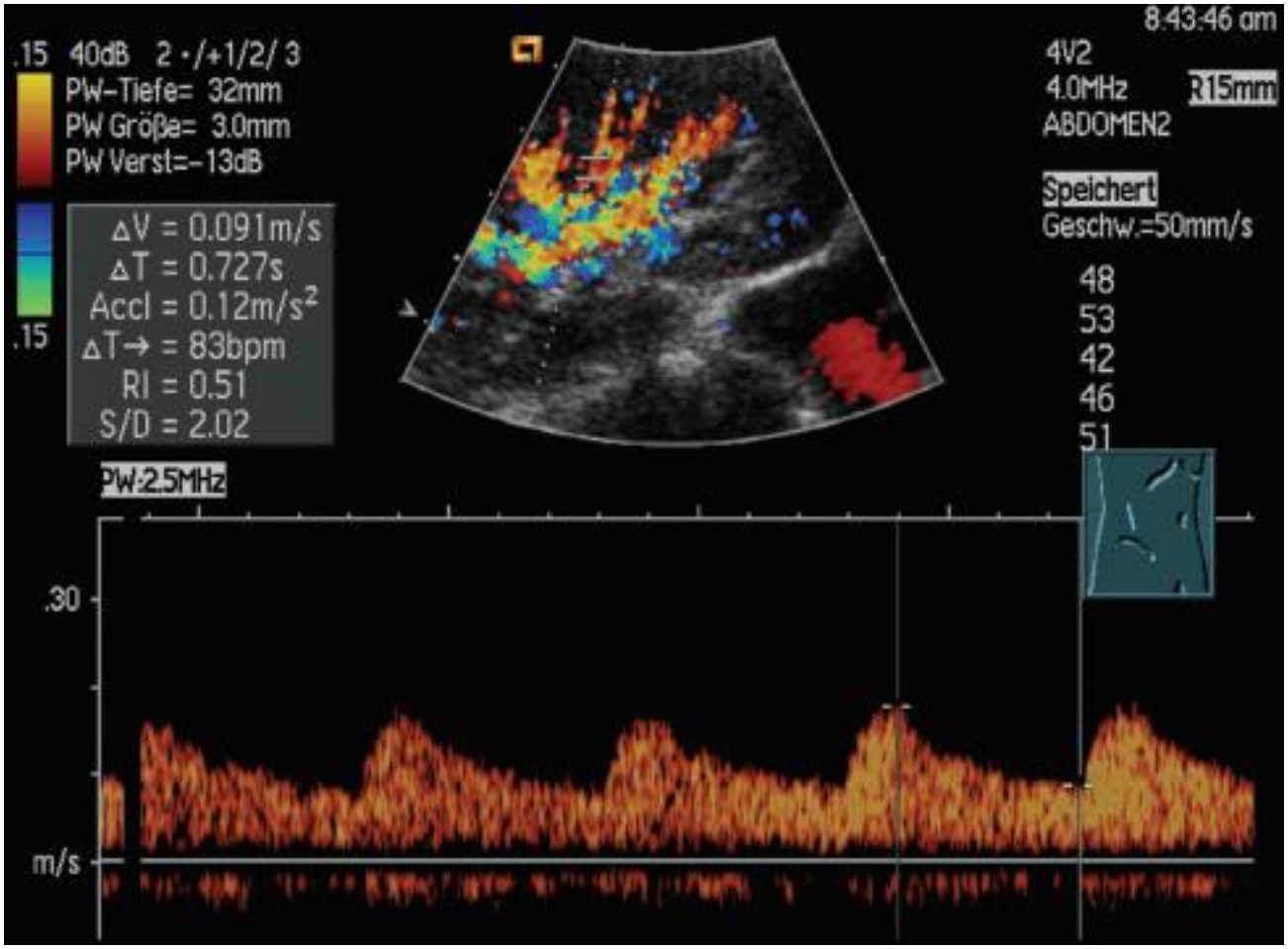

Intrarenal RI of 51 is determined in the Doppler flow pattern of a kidney with proximal RAS. The 'tardus-parvus'-flow pattern reveals low peak systolic and high end diastolic velocity resulting in low RI-values from 42 to 53.

Krumme B. and Hollenbeck M., Nephrol. Dial. Transplant., 2007, 22: 692–696

Diagnostic work up of patients with suspected renal artery stenosis in 2017

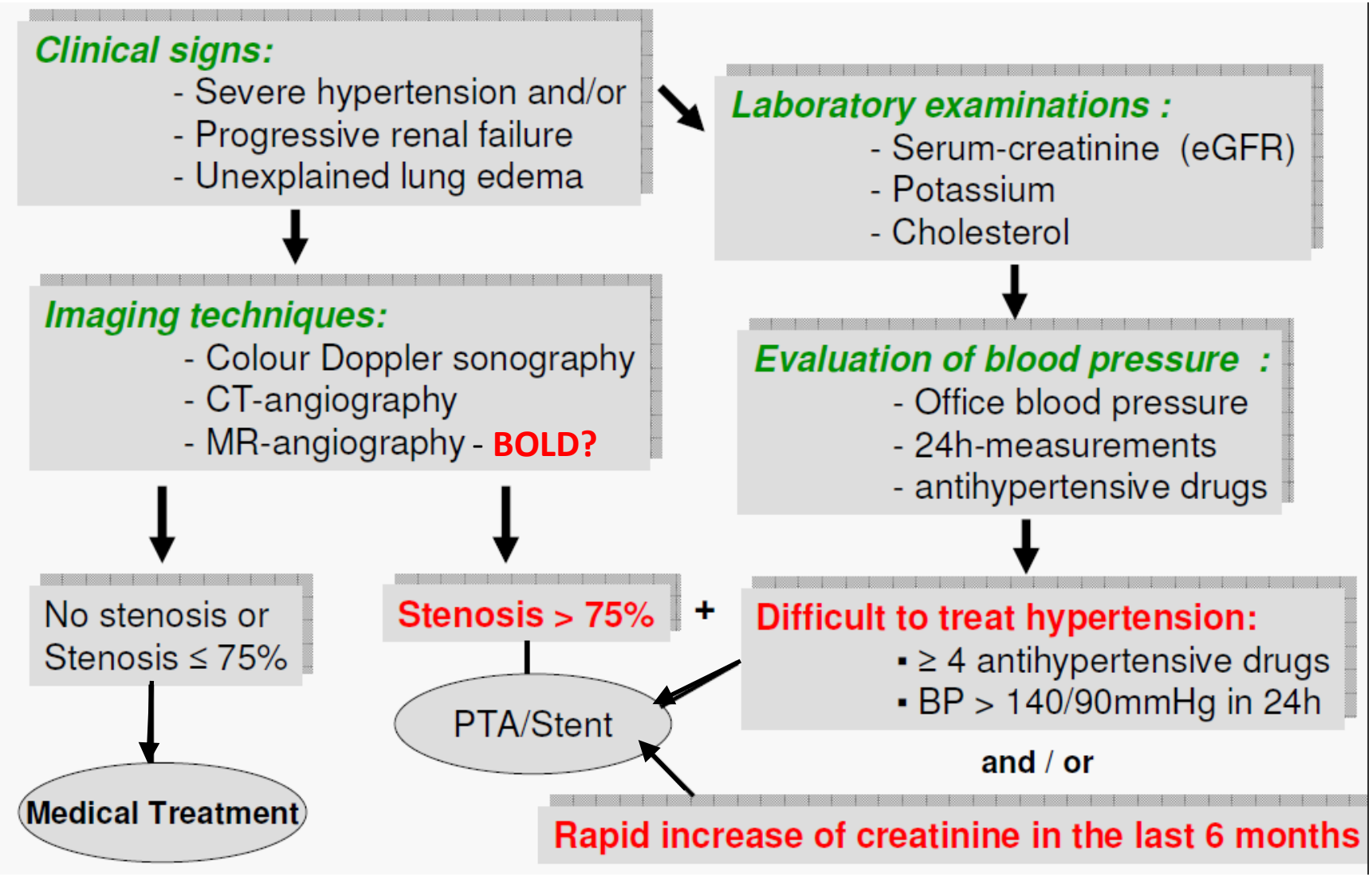

Leading European Nephrology

ASTRAL - Systolic and diastolic blood pressure in patients with renal artery stenosis treated with revascularization or medical therapy alone

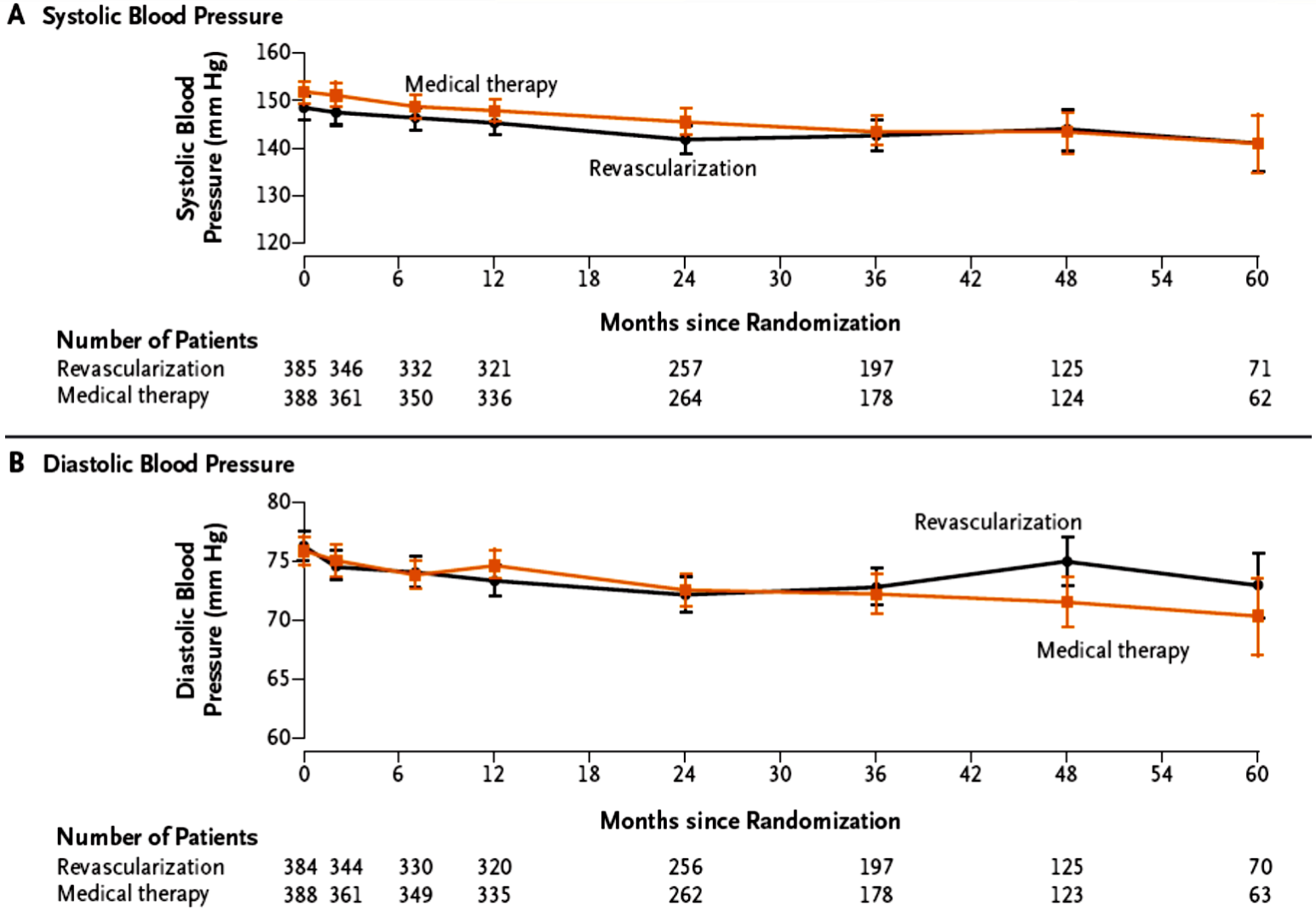

Kalra P. N. Engl. J. Med., 2009, 361,1953-62

Leading European Nephrology

ASTRAL - Renal function in patients with renal-artery stenosis treated with revascularization or medical therapy alone

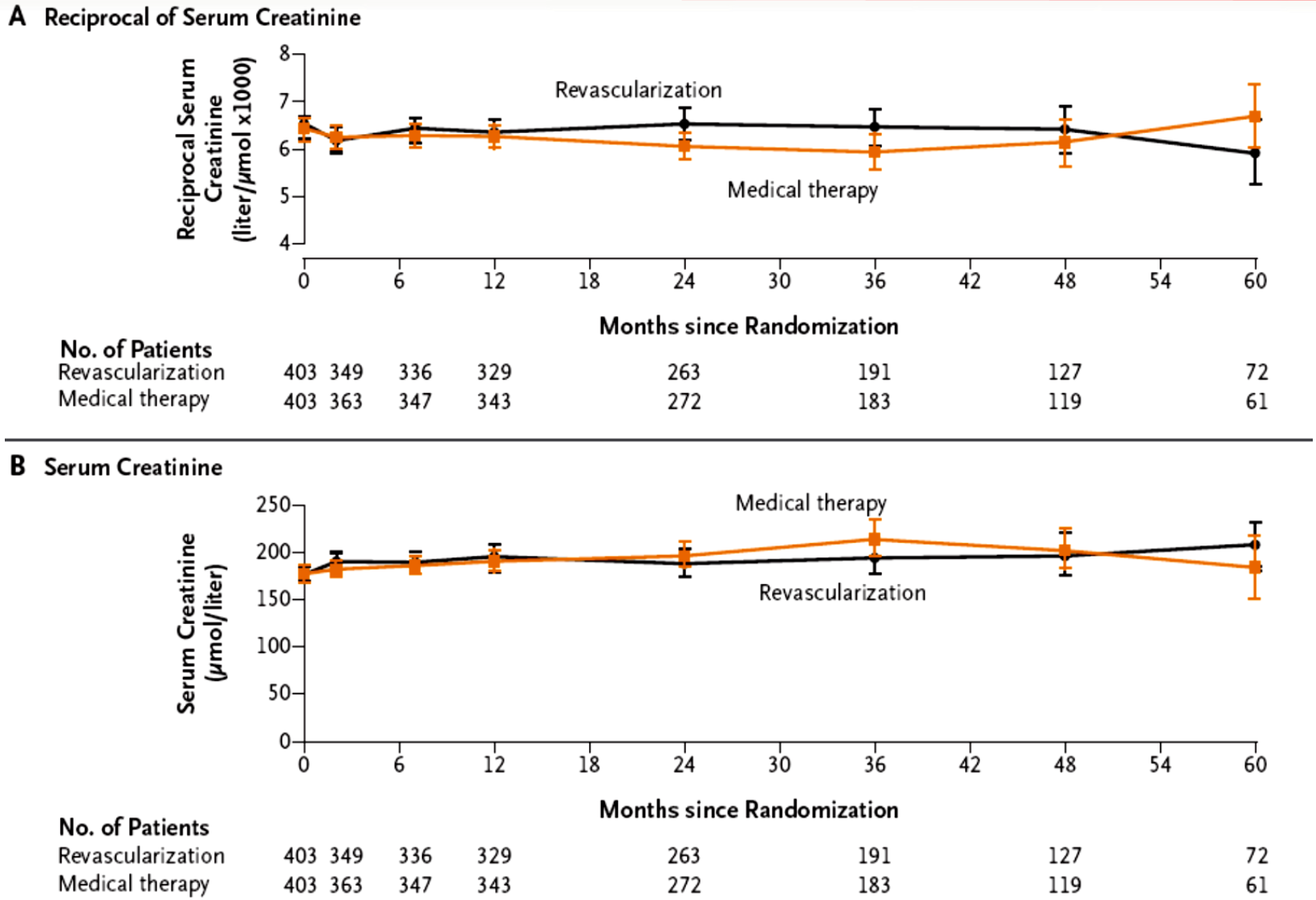

Kalra P. N. Engl. J. Med., 2009, 361,1953-62

ASTRAL - Kaplan–Meier curves for the time to the first renal events

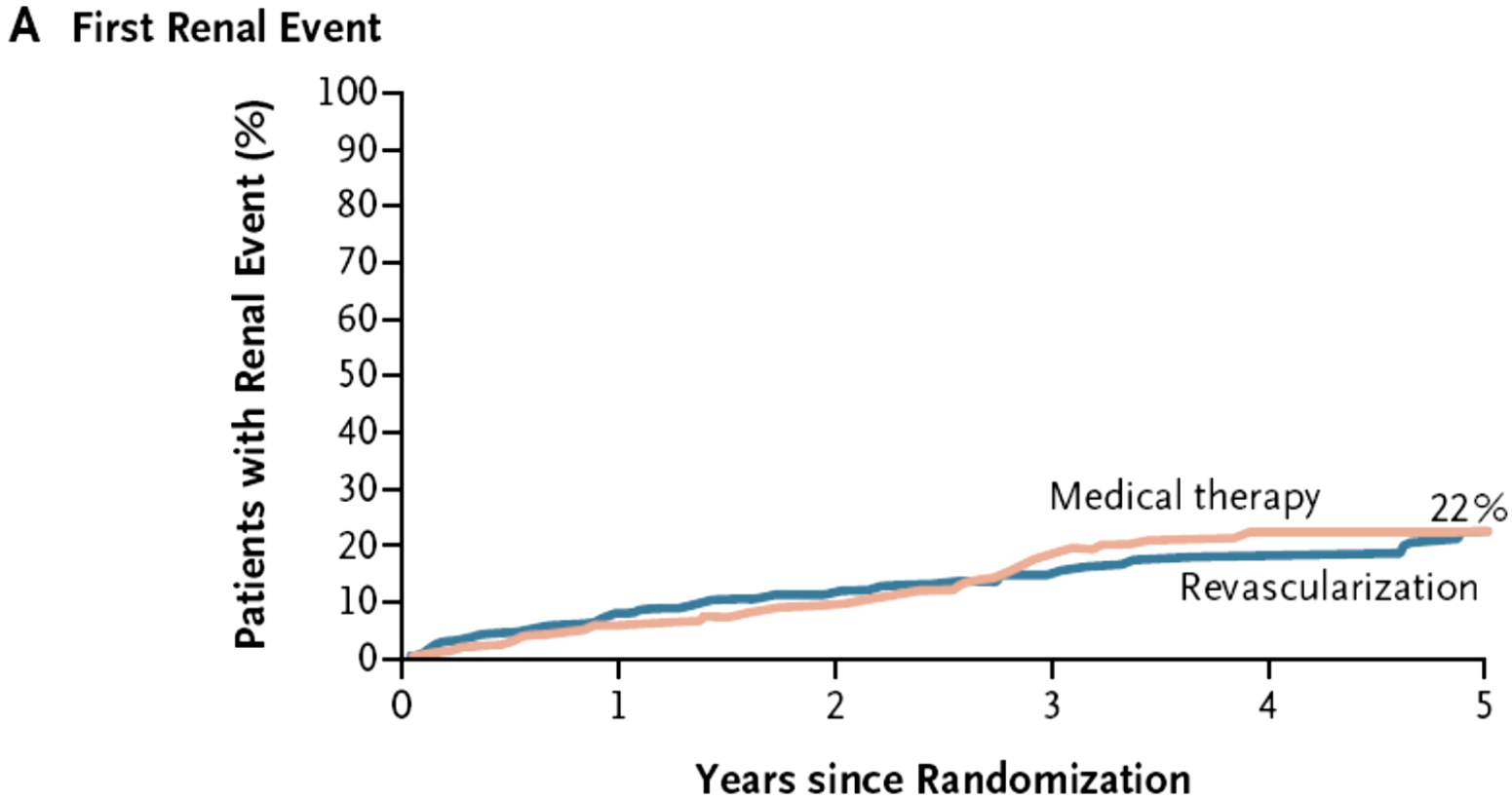

No. at Risk

Revascularization	403	315	236	157	99	39
Medical therapy	403	319	233	145	84	37

Kalra P. N. Engl. J. Med., 2009, 361,1953-62

Leading European Nephrology

CKD-EPI eGFR (ml/min./1.73m2) in randomized treatment groups of the CORAL Trial

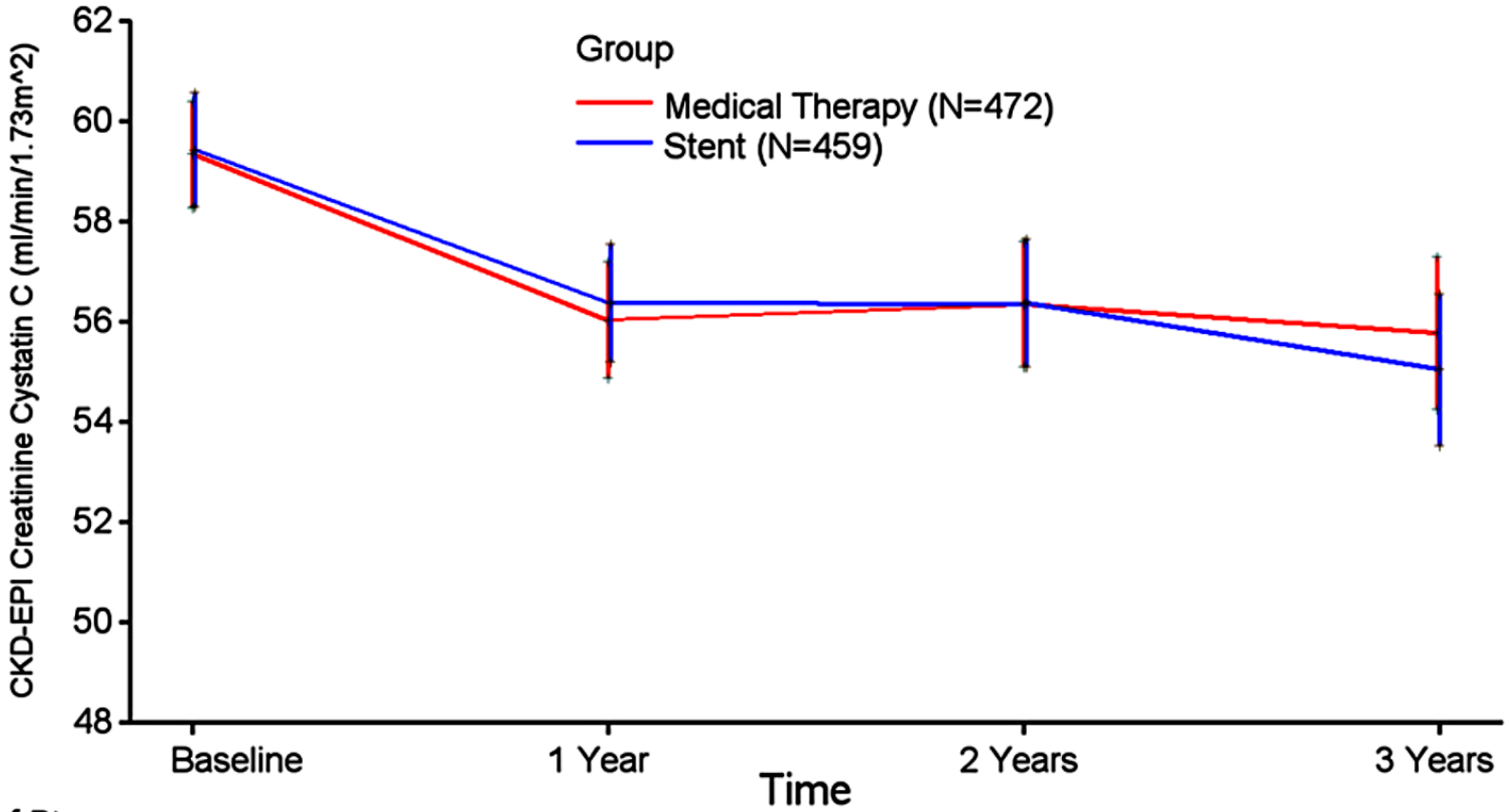

# of Pts	Baseline	1 Year	2 Years	3 Years
Medical Rx	454	387	345	219
Stent	436	383	344	258

Tuttle K.R. et. al., Clin J Am Soc Nephrol., 2016, 11: 1180–1188

The CORAL Study

Kaplan–Meier Curves for the Primary Outcome

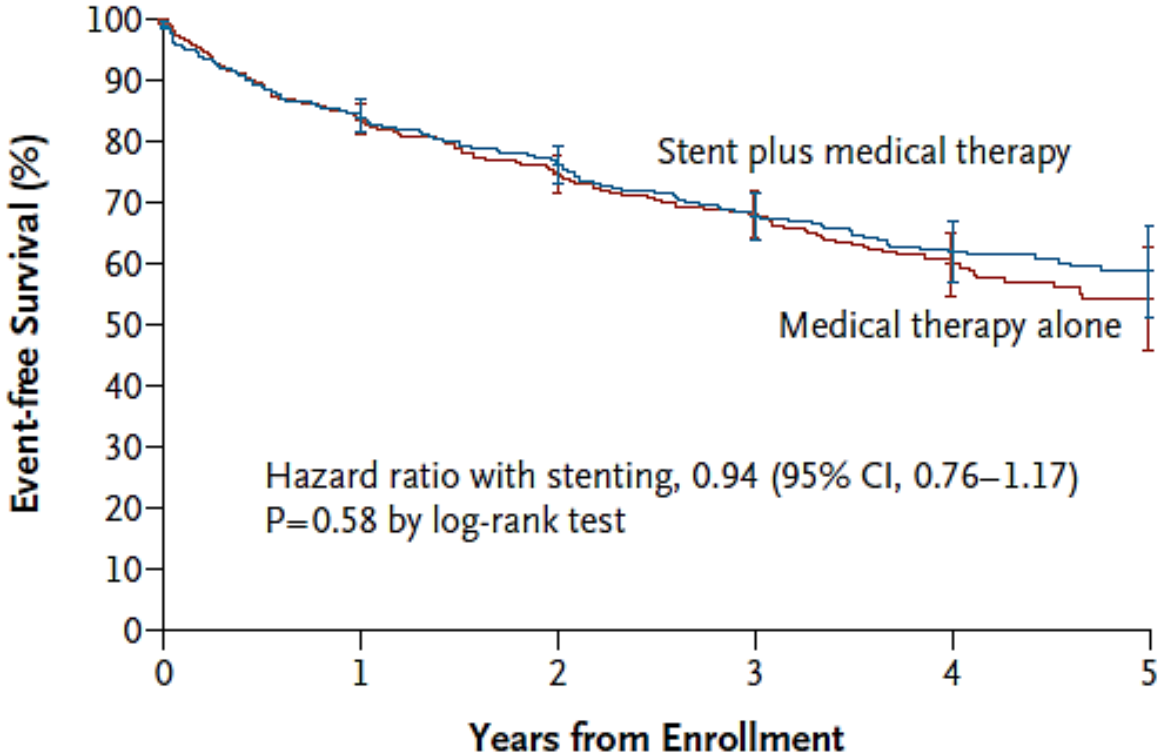

No. at Risk

Medical therapy alone	472	371	314	214	115	40
Stent plus medical therapy	459	362	318	224	131	59

Cooper C. J. et al., N. Engl.J. Med., 2014, 370, 13 - 22

Leading European Nephrology

The CORAL Study:
Forest Plot of Treatment Effects within Subgroups

Subgroup	Stent plus Medical Therapy	Medical Therapy Alone	Hazard Ratio (95% CI)	P Value for Interaction
	no. of patients/total no. (%)			
Overall	161/459 (35.1)	169/472 (35.8)	0.94 (0.76–1.17)	
Creatinine level				0.09
>1.6 mg/dl	43/84 (51.2)	34/87 (39.1)	1.35 (0.86–2.11)	
≤1.6 mg/dl	112/352 (31.8)	128/367 (34.9)	0.87 (0.67–1.12)	
Estimated GFR				0.80
≥45 ml/min/1.73 m^2	91/288 (31.6)	105/311 (33.8)	0.93 (0.70–1.23)	
<45 ml/min/1.73 m^2	64/148 (43.2)	57/143 (39.9)	0.98 (0.68–1.40)	
Diabetes				0.17
Yes	69/148 (46.6)	66/162 (40.7)	1.15 (0.82–1.61)	
No	92/309 (29.8)	103/310 (33.2)	0.84 (0.64–1.12)	
Sex				0.64
Male	75/234 (32.1)	78/231 (33.8)	0.89 (0.65–1.22)	
Female	86/225 (38.2)	91/241 (37.8)	0.99 (0.74–1.33)	
Global ischemia				0.32
Yes	39/89 (43.8)	20/51 (39.2)	1.07 (0.62–1.83)	
No	119/356 (33.4)	106/264 (40.2)	0.78 (0.60–1.01)	
Race				0.62
Black	11/29 (37.9)	10/30 (33.3)	1.01 (0.42–2.43)	
Other	126/356 (35.4)	136/357 (38.1)	0.88 (0.69–1.13)	
Baseline systolic blood pressure				0.55
>160 mm Hg	66/148 (44.6)	58/139 (41.7)	1.02 (0.71–1.45)	
≤160 mm Hg	95/309 (30.7)	108/328 (32.9)	0.90 (0.68–1.18)	
Age				0.56
>70 yr	91/226 (40.3)	94/220 (42.7)	0.87 (0.65–1.16)	
≤70 yr	70/233 (30.0)	75/252 (29.8)	1.00 (0.72–1.39)	
U.S. sites				0.38
Yes	137/385 (35.6)	146/387 (37.7)	0.90 (0.71–1.14)	
No	24/74 (32.4)	23/85 (27.1)	1.22 (0.69–2.16)	
Maximal diameter stenosis				0.66
≥80%	77/198 (38.9)	64/166 (38.6)	0.93 (0.67–1.30)	
<80%	77/231 (33.3)	79/208 (38.0)	0.84 (0.61–1.14)	

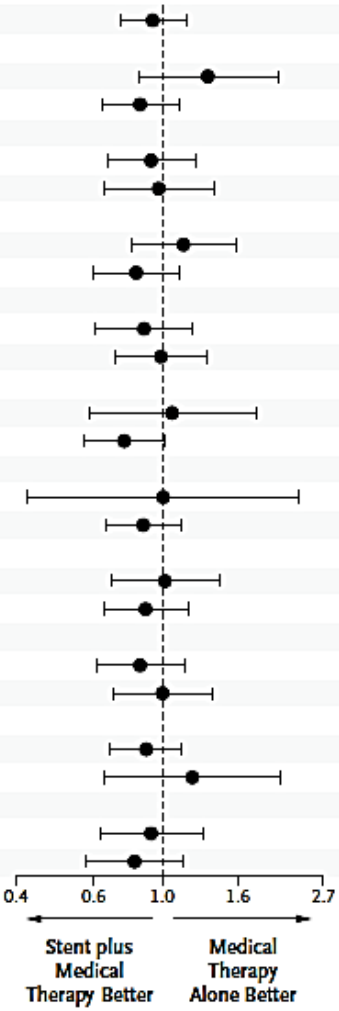

Cooper C. J. et al., N. Engl. J. Med., 2014, 370, 13 - 22

Leading European Nephrology

The NEW ENGLAND JOURNAL of MEDICINE

ESTABLISHED IN 1812 JANUARY 2, 2014 VOL. 370 NO. 1

Stenting and Medical Therapy for Atherosclerotic Renal-Artery Stenosis

Christopher J. Cooper, M.D., Timothy P. Murphy, M.D., Donald E. Cutlip, M.D., Kenneth Jamerson, M.D., William Henrich, M.D., Diane M. Reid, M.D., David J. Cohen, M.D., Alan H. Matsumoto, M.D., Michael Steffes, M.D., Michael R. Jaff, D.O., Martin R. Prince, M.D., Ph.D., Eldrin F. Lewis, M.D., Katherine R. Tuttle, M.D., Joseph I. Shapiro, M.D., M.P.H., John H. Rundback, M.D., Joseph M. Massaro, Ph.D., Ralph B. D'Agostino, Sr., Ph.D., and Lance D. Dworkin, M.D., for the CORAL Investigators*

ABSTRACT

BACKGROUND

Atherosclerotic renal-artery stenosis is a common problem in the elderly. Despite two randomized trials that did not show a benefit of renal-artery stenting with respect to kidney function, the usefulness of stenting for the prevention of major adverse renal and cardiovascular events is uncertain.

From the University of Toledo, Toledo, OH (C.J.C.); Rhode Island Hospital (T.P.M., L.D.D.) and Alpert Medical School of Brown University (T.P.M., L.D.D.) — both in Providence; Harvard Clinical Research Institute (D.E.C., J.M.M., R.B.D.), Beth Israel Deaconess Medical Center (D.E.C.),

CONCLUSIONS

Renal-artery stenting did not confer a significant benefit with respect to the prevention of clinical events when added to comprehensive, multifactorial medical therapy in people with atherosclerotic renal-artery stenosis and hypertension or chronic kidney disease. (Funded by the National Heart, Lung and Blood Institute and others; ClinicalTrials.gov number, NCT00081731.)

Renal artery revascularization:

updated meta-analysis with the CORAL trial summary estimates of cardiovascular outcomes for revascularization vs medical therapy

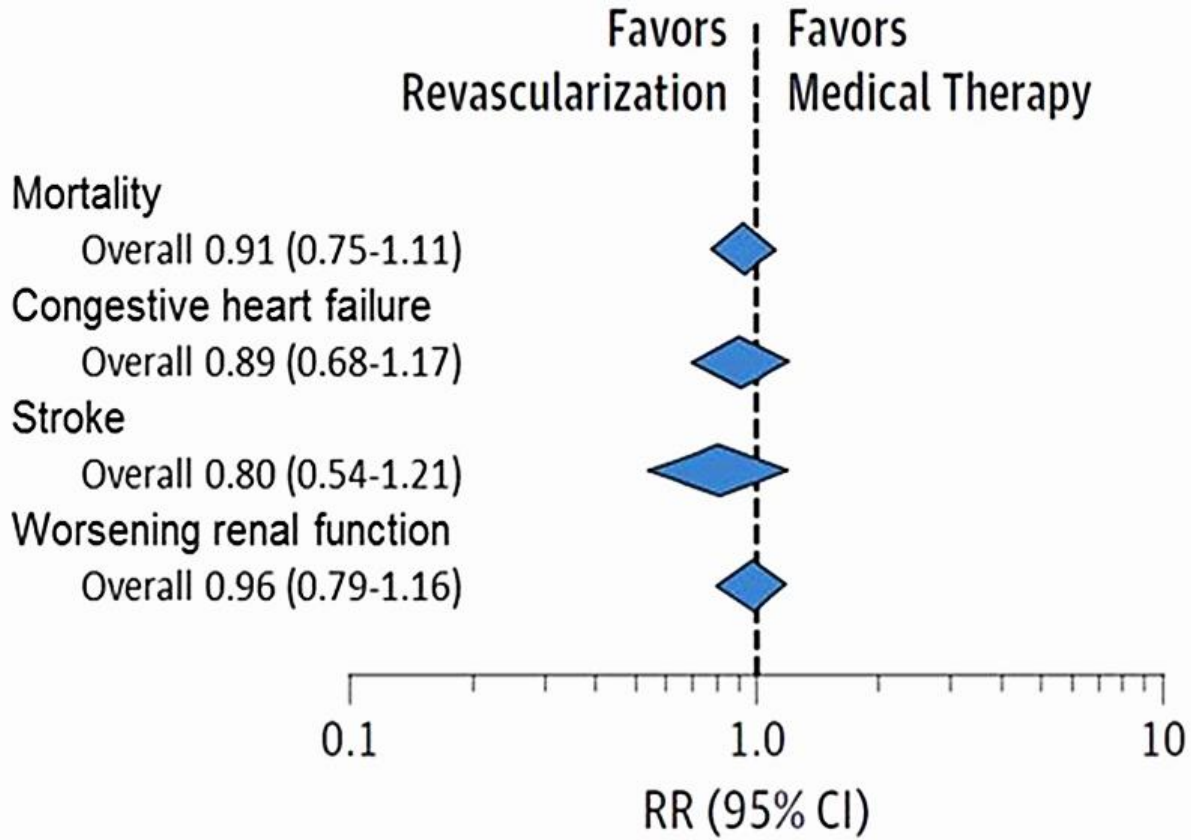

Included trials: STAR; ASTRAL; SNARSCG; NITER; CORAL; RASCAD; DRASTIC; EMMA

Oparil S. and Schmieder R., Circ. Res., 2015, 116:1074-1095

Leading European Nephrology

CURRENT OPINION

Where now in the management of renal artery stenosis? Implications of the ASTRAL and CORAL trials

James Ritchie, Helen V. Alderson, and Philip A. Kalra

Purpose of review

The neutral findings of Angioplasty and Stenting for Renal Artery Lesions and Cardiovascular Outcomes in Renal Artery Lesions trials have shown that unselected revascularization does not improve outcomes in atherosclerotic renovascular disease (ARVD). This review highlights recent translational, clinical and epidemiological studies and suggests directions for future research.

Recent findings

Imaging studies show that the degree of renal artery stenosis is not the most important determinant of outcome and response to therapies in ARVD. Porcine models have established a better understanding of the microvascular and inflammatory changes that occur in ARVD. Biomarkers of inflammation and cardiovascular dysfunction may be informative but do not yet help assess prognosis or response to treatment. Stem cell therapies show promise in animal models but have yet to translate into clinical practice. Analysis of patient subgroups with high-risk presentations of ARVD has provided new insights into treatment response and may guide future studies.

Summary

It is time to reframe thinking and research in ARVD. We need better ways to identify patients likely to benefit from revascularization and to improve response to treatment in these individuals. Many preclinical studies show promise, but these are often small scale and difficult to replicate. Future work should focus on establishing an international disease registry as a foundation for collaborative research.

Current. Opin. Nephrol. Hypertens., 2014, 23, 525-532

Mean (±SEM) change in MAP and the number of antihypertensive drugs taken after the correction of RAS, according to resistance index values before revascularization

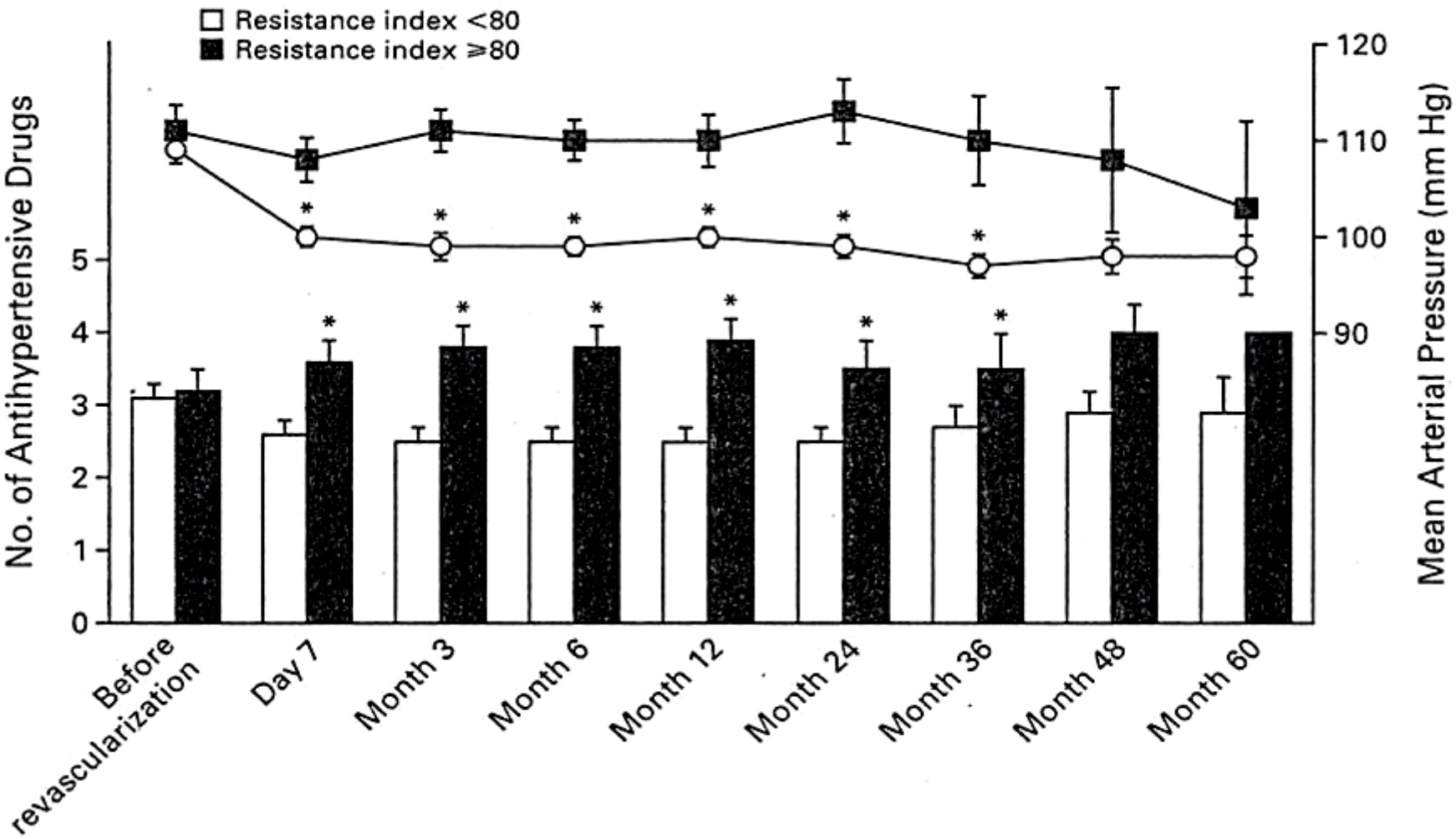

Radermacher J. et al N. Eng. J. Med., 2001, 344, 410-417

Leading
European
Nephrology

Mean changes in creatinine clearance after the correction of RAS, according to resistance index values before revascularization

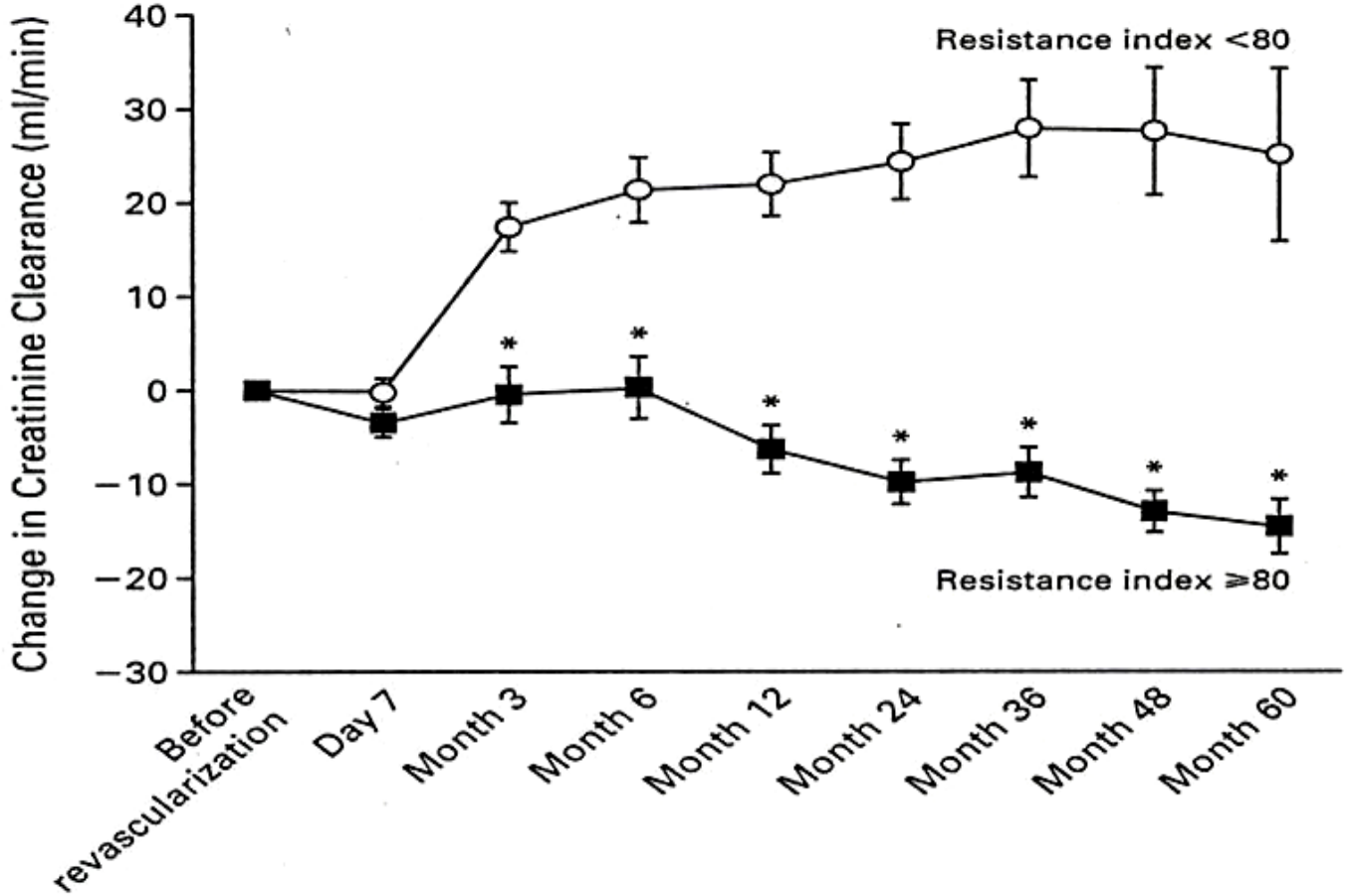

No. with Follow-up Data									
Resistance index <80	96	96	95	83	73	59	43	34	21
Resistance index ≥80	35	35	33	31	26	21	16	8	5

Radermacher J. et al N.Eng. J. Med., 2001, 344, 410-417

Renovascular Hypertension Revisited: To intervene or not?

- Therefore, the assumption that restoring renal artery patency always protects the kidney is false. In addition, sometimes the revascularization procedure causes a worsening of kidney function, in addition to the high risk of major complications and increased economic costs associated with the procedure

Boehlke M. and Correa Barcellos F., Am J Kidney Dis., 2015, 65: 611-622

Factors favoring medical therapy plus revascularization for renal artery stenosis:

- Progressive decline in GFR during treatment of hypertension
- Failure to achieve adequate BP control with optimal medical therapy
- Rapid or recurrent decline in GFR in association with a reduction in systemic pressure
- Decline in GFR during therapy with ACE inhibitors or ARBs
- Recurrent congestive heart failure in a patient in whom left ventricular failure does not explain the cause (flash pulmonary edema)

Textor S.C., Clin J Am Soc Nephrol., 2014, 9: 1117–1123

Factors favoring medical therapy and surveillance of renal artery disease

- Controlled BP with stable renal function
- Stable renal artery stenosis without progression on surveillance studies (e.g., serial duplex ultrasound)
- Advanced age and/or limited life expectancy
- Extensive comorbidities that make revascularization too risky
- High risk for or previous experience with atheroembolic disease
- Other concomitant renal parenchymal diseases that cause progressive renal dysfunction (e.g., diabetic nephropathy) or severely reduced kidney size (< 7.0 cm)

Textor S.C., Clin J Am Soc Nephrol., 2014, 9: 1117–1123

Leading European Nephrology

Injury pathways and targets in Atherosclerotic Renovascular Disease (ARVD)

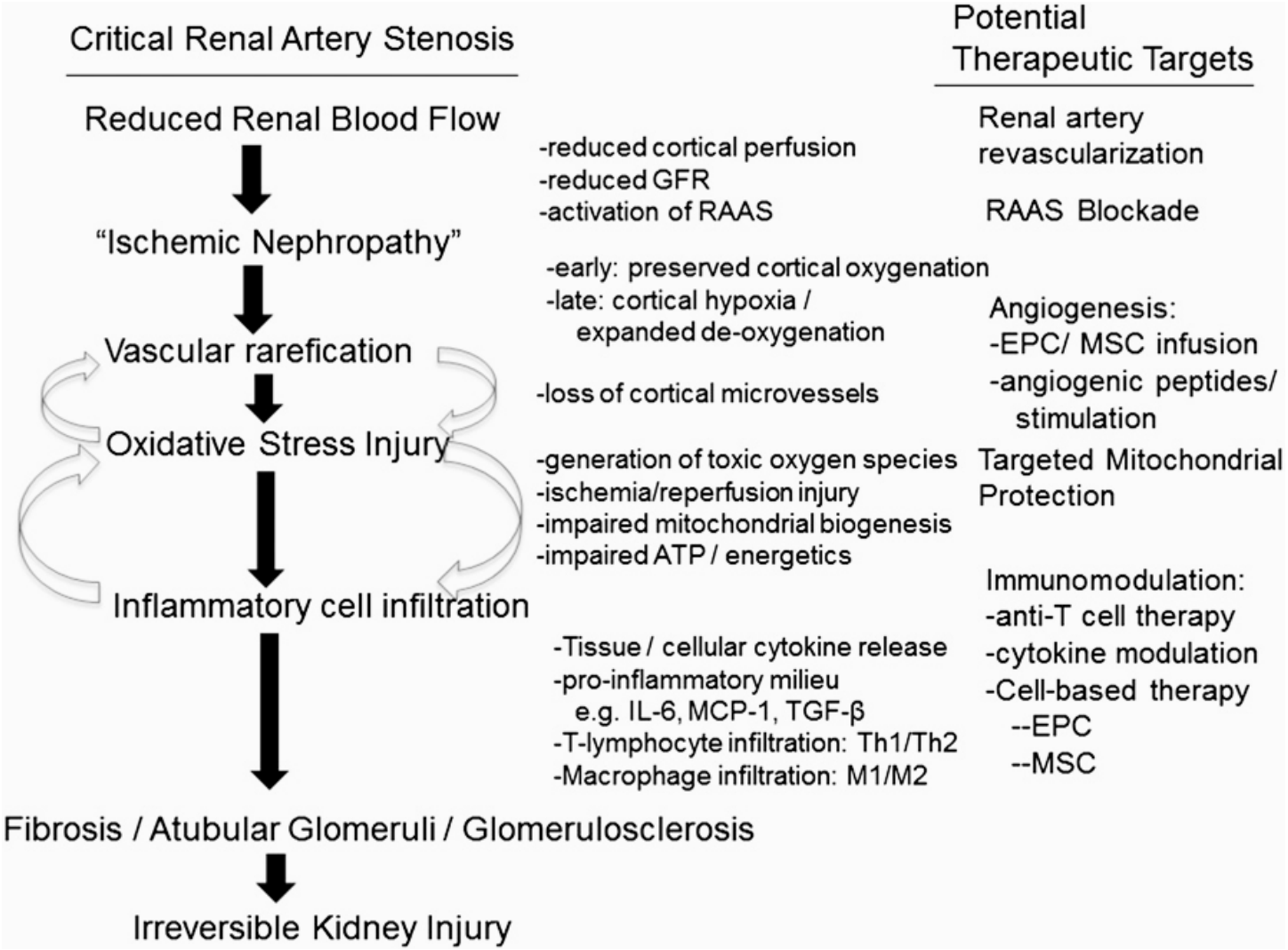

Textor S.C., and Lerman L.O., J. Am. Soc. Nephrol., 2015, 26: 2074–2080

Andrzej Więcek
Katowice

Leading
European
Nephrology