C3 GLOMERULOPATHIES

Budapest Nephrology School

8.30.2018.

Zoltan Laszik

Learning Objectives

- Familiarize with the pathogenetic mechanisms of glomerular diseases
- Learn the pathologic landscape and clinical course of C3 glomerulopathies
- Explore the underlying pathogenetic mechanisms of C3 glomerulopathies
- Venture into the unknown and therapy

UCSF

Percutaneous needle kidney biopsies
Historical context

- Iversen and Brun (1951), Denmark
- Alwall (1952), Sweden
- Kark and Muehrcke (1952), University of Illinois, Chicago
- Pirani (early 50's), pathology interpretation, University of Illinois, Chicago

UCSF

Light Microscopy (LM)

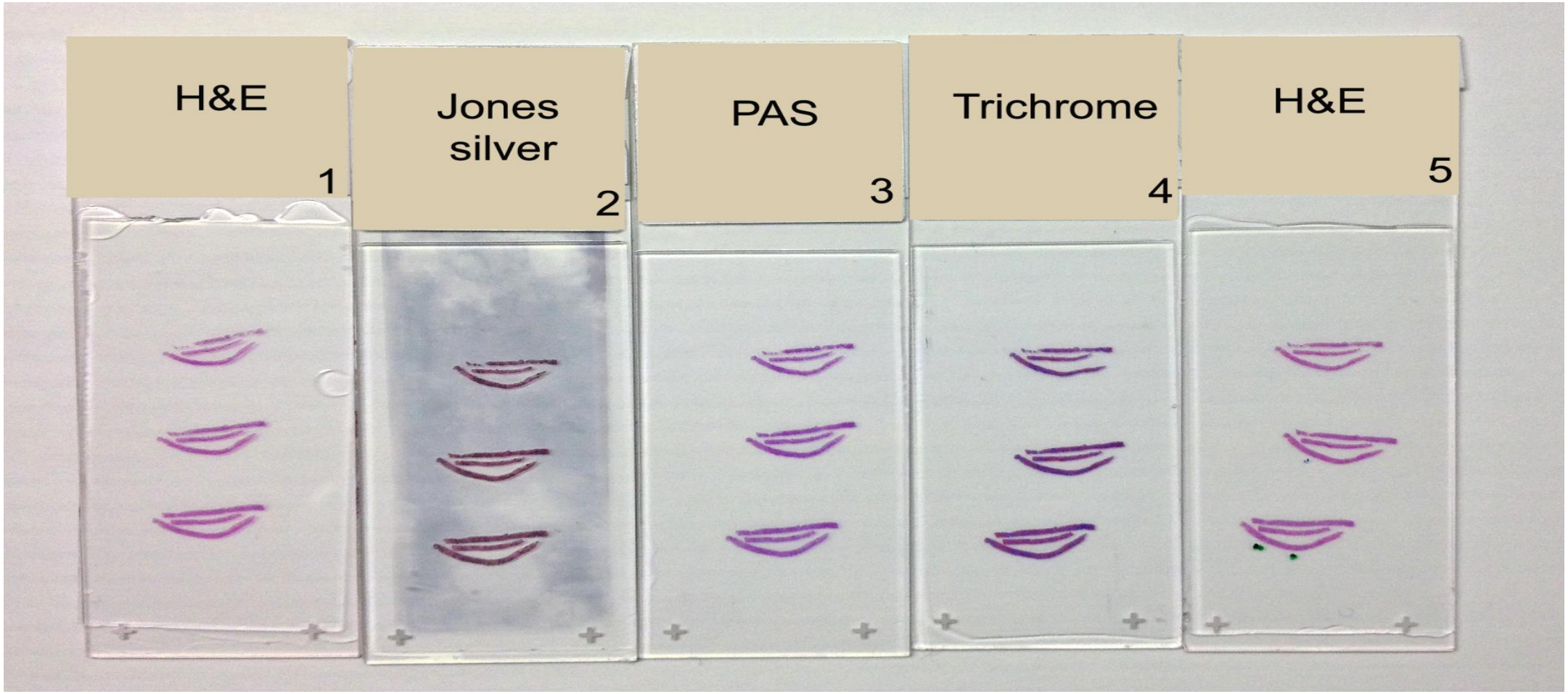

H&E

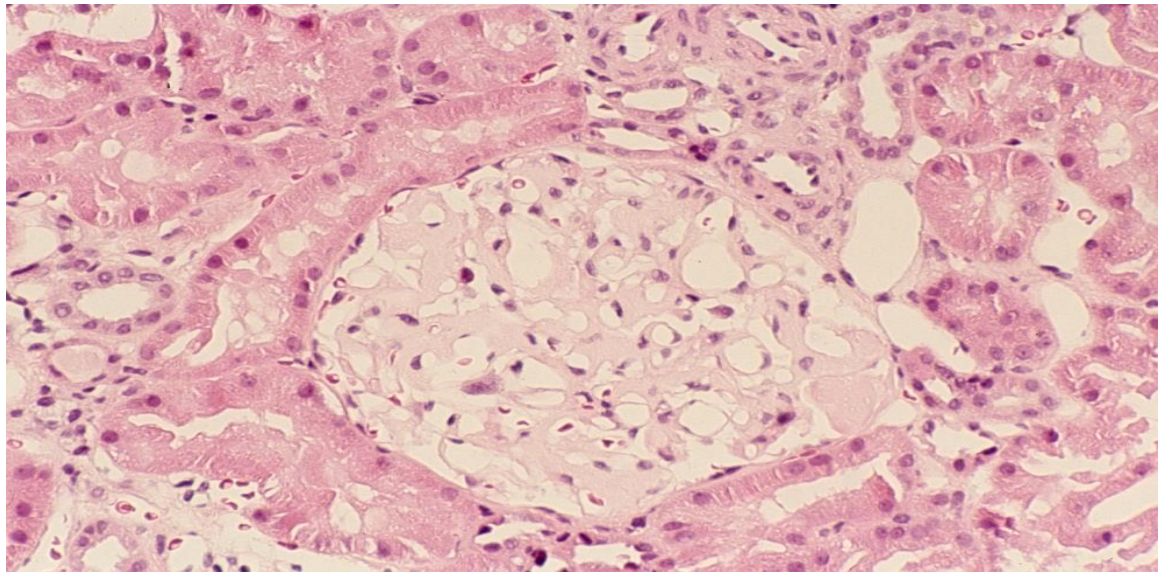

PAS

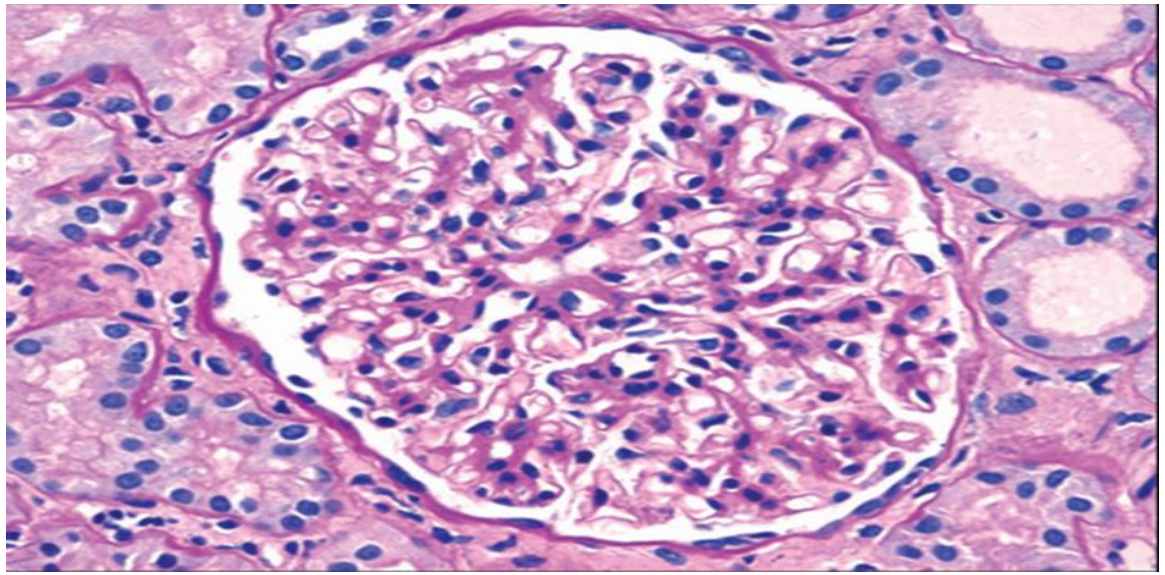

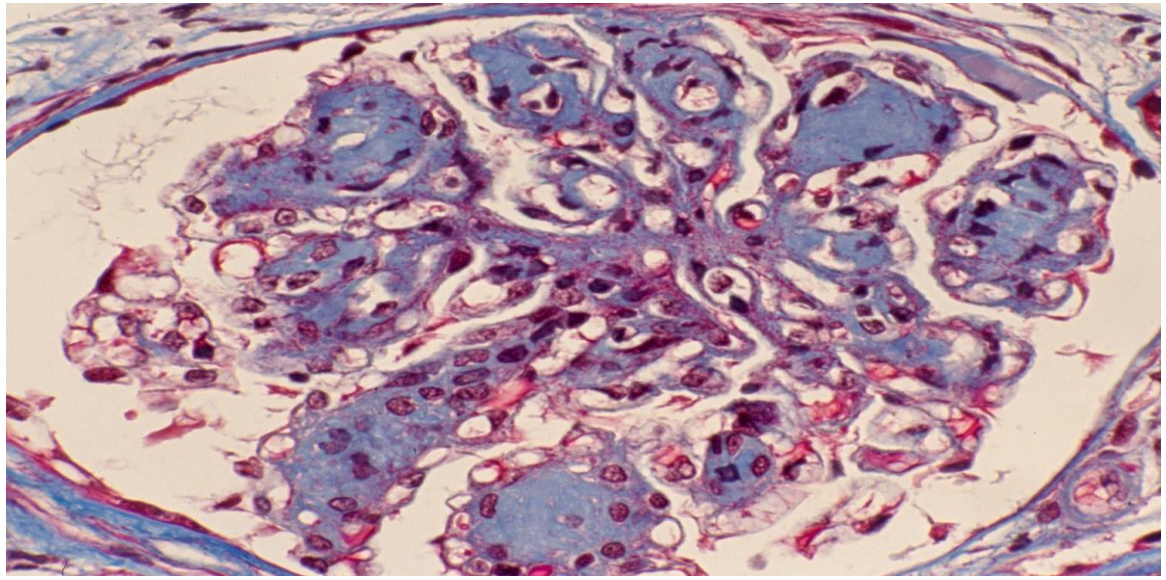

Trichrome

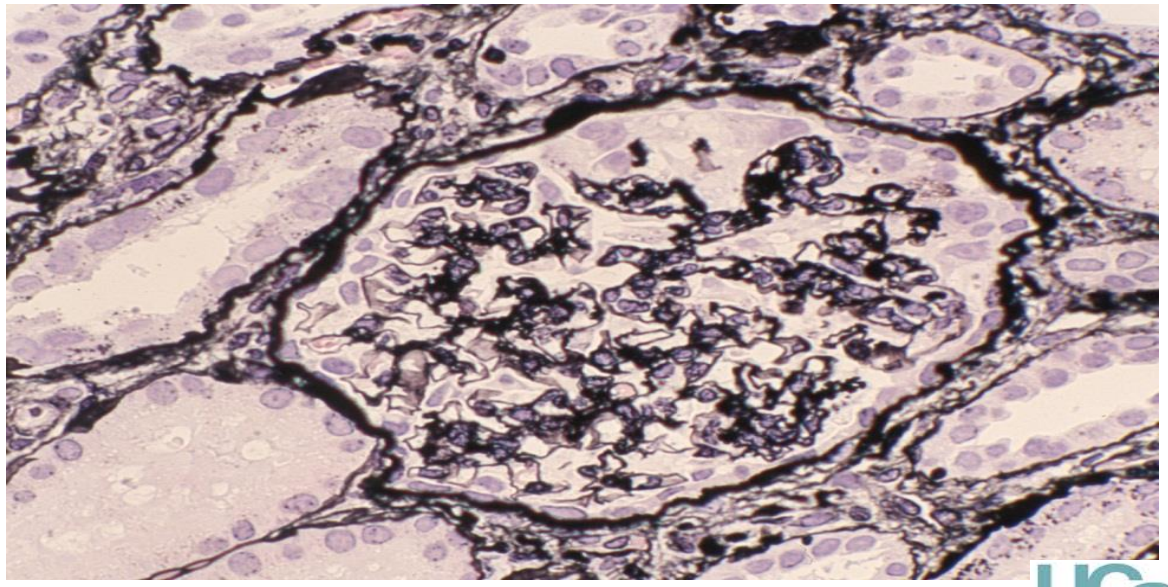

Jones methenamine silver

Antibody mediated glomerular injury

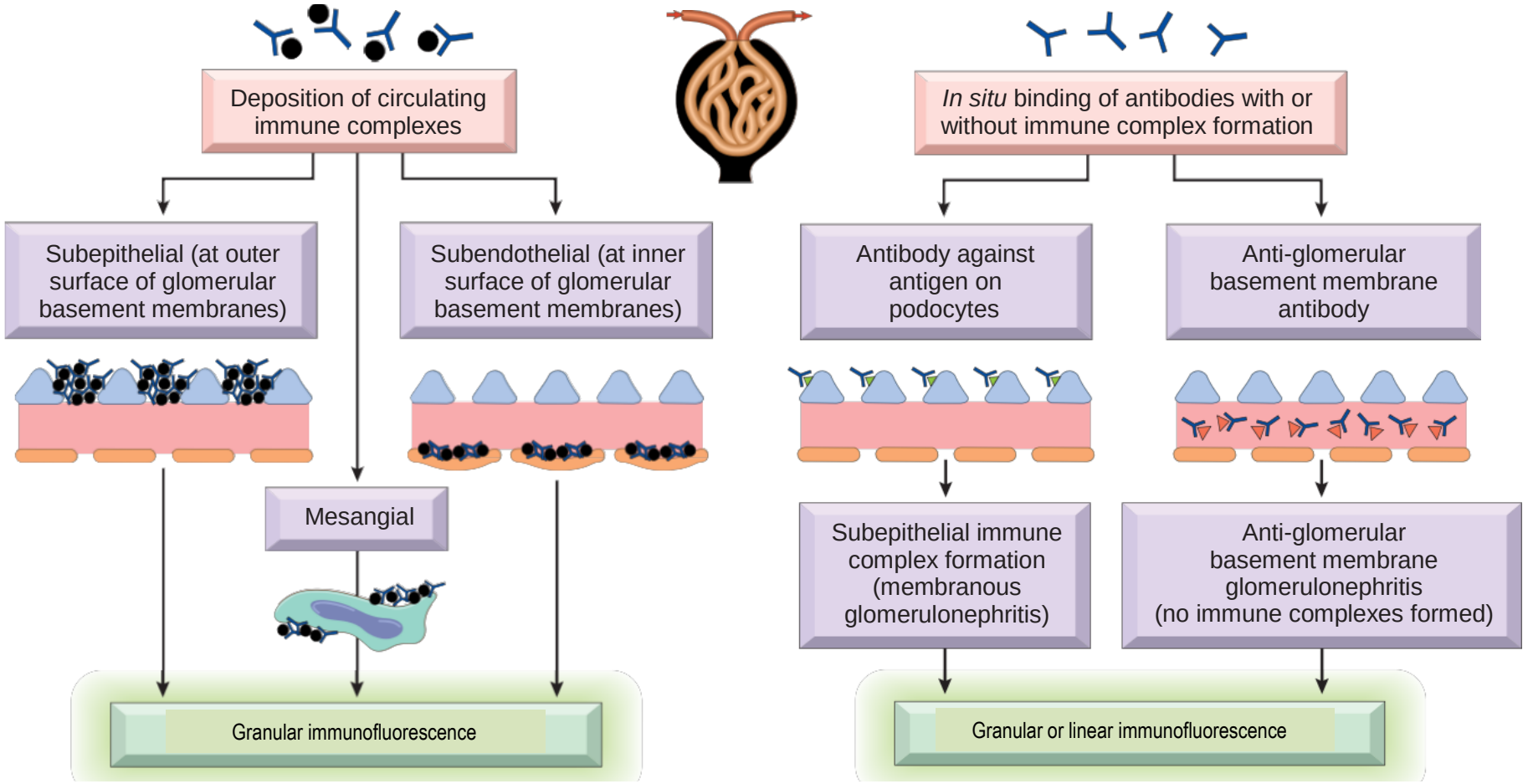

The hunt for the immune complexes

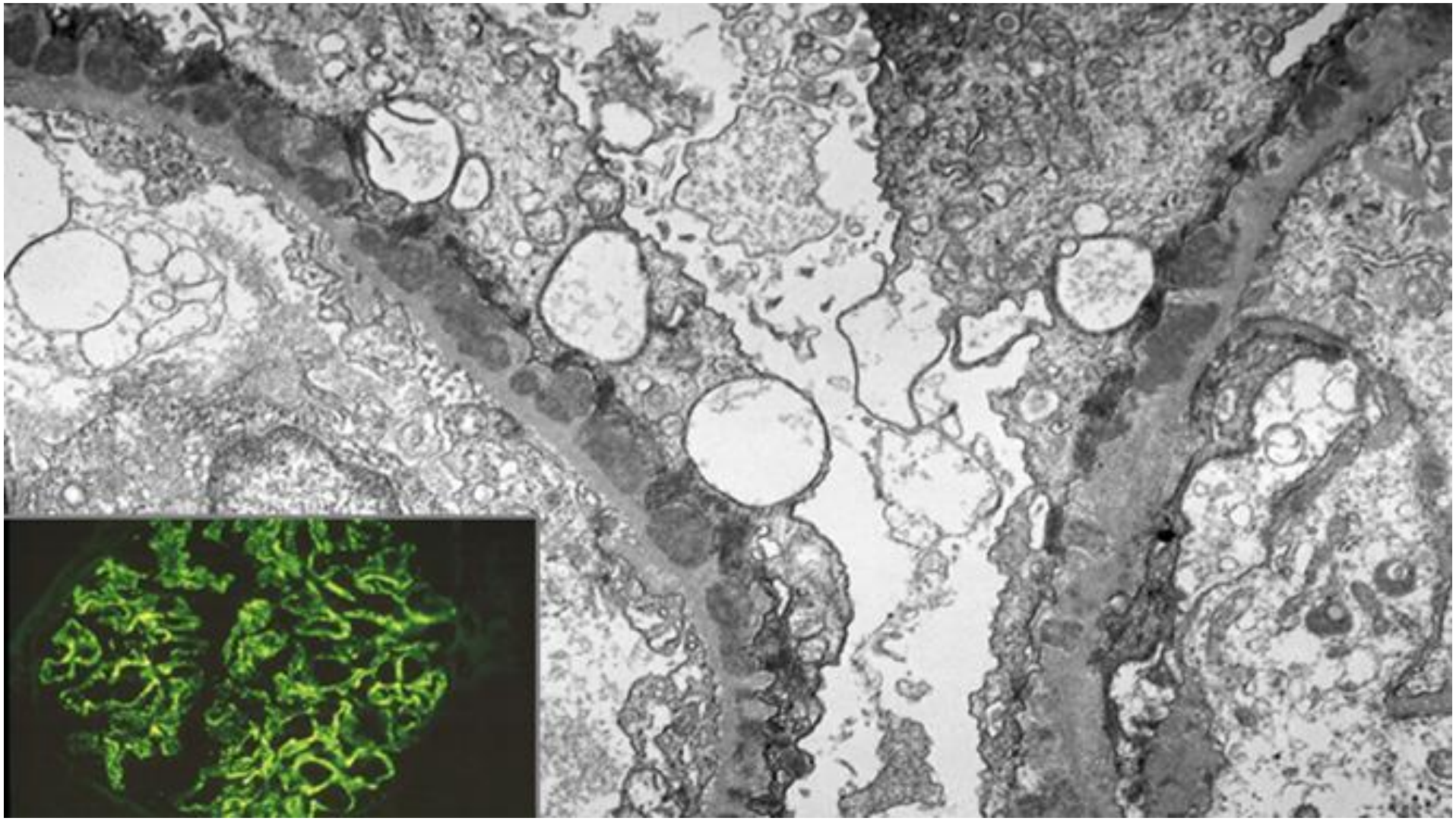

Mechanisms of glomerular diseases

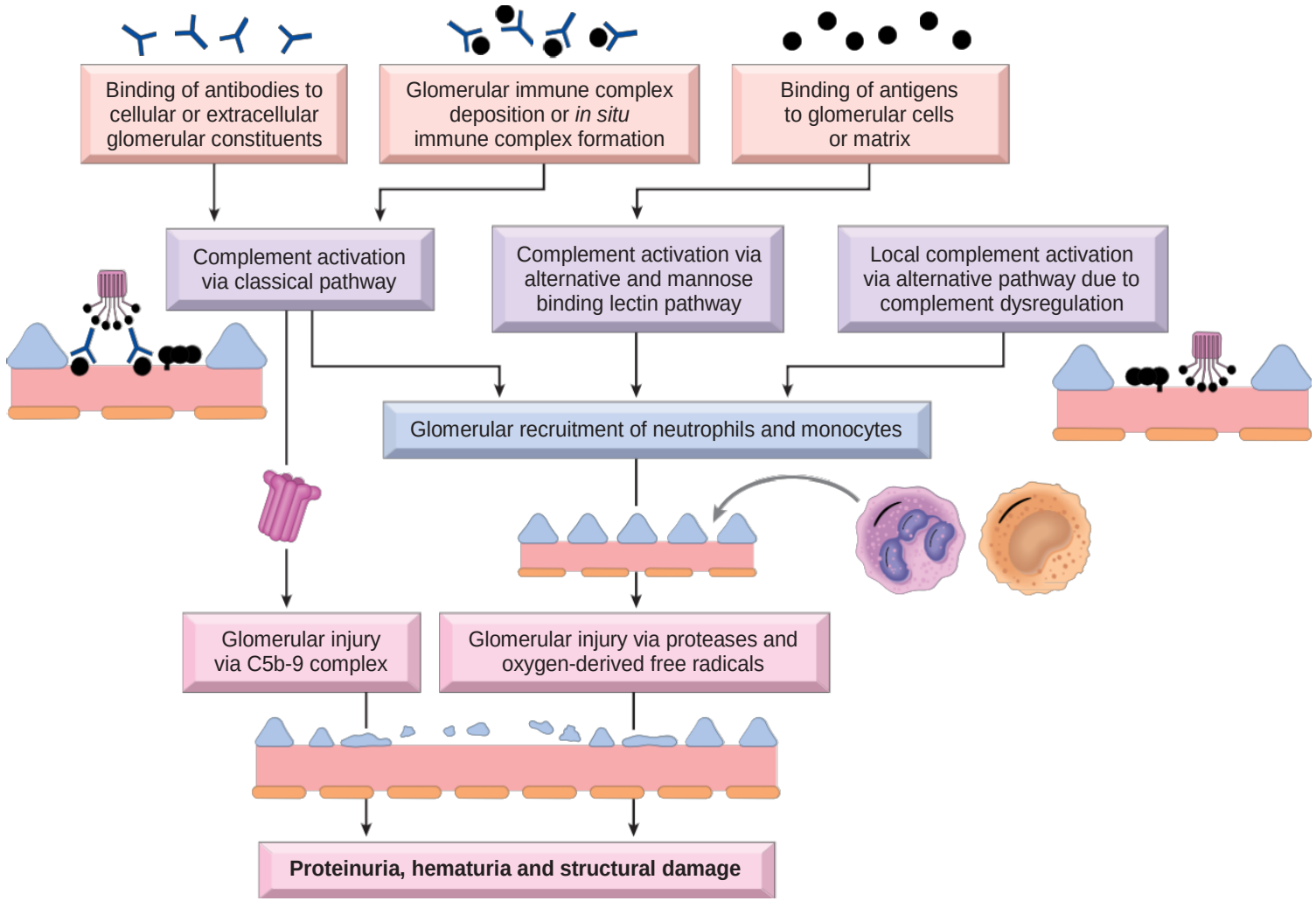

f0030

Mechanisms of glomerular diseases

- Immune mechanisms
  - Circulating Immune Complexes
  - Immune Complexes Formed In Situ
  - Anti-GBM Antibody–Mediated
  - Caused by Abnormal Complement Activation
- Mediators of immune injury
  - Complement and leukocytes
- Podocyte injury
- Nephron loss

UCSF

Algorithm of Morphologic Interpretation of Glomerular Patterns

The True Glomerulonephritides

The Non-Glomerulonephritic Glomerulonephrophathies

A. Is there glomerular hypercellularity (with narrowing of capillary lumens)?

GLOMERULAR HYPERCELLULARITY
(usually nephritic)

or

MINIMAL GLOMERULAR HYPERCELLULARITY
(usually nephrotic)

B. Is the hypercellularity:

INTRA-CAPILLARY or **EXTRA-CAPILLARY** (crescents) Crescentic GN

MESANGIUM NORMAL Minimal Change Nephrotic Syndrome

DIFFUSE MESANGIAL PROMINENCE Diffuse Mesangial Hypercellularity or **DIABETIC NEPHROPATHY**

SEGMENTAL MESANGIAL SCLEROSIS Focal segmental sclerosis

MEMBRANOUS GLOMERULO-NEPHROPATHY

C. Is the hypercellularity:

DIFFUSE

1) Acute Postinfectious GN
2) Membranoproliferative GN (Types 1,2,3)

or

FOCAL Global or Segmental

Focal GN
(SLE, Collagenvascular diseases infective endocarditis etc.)

UCSF

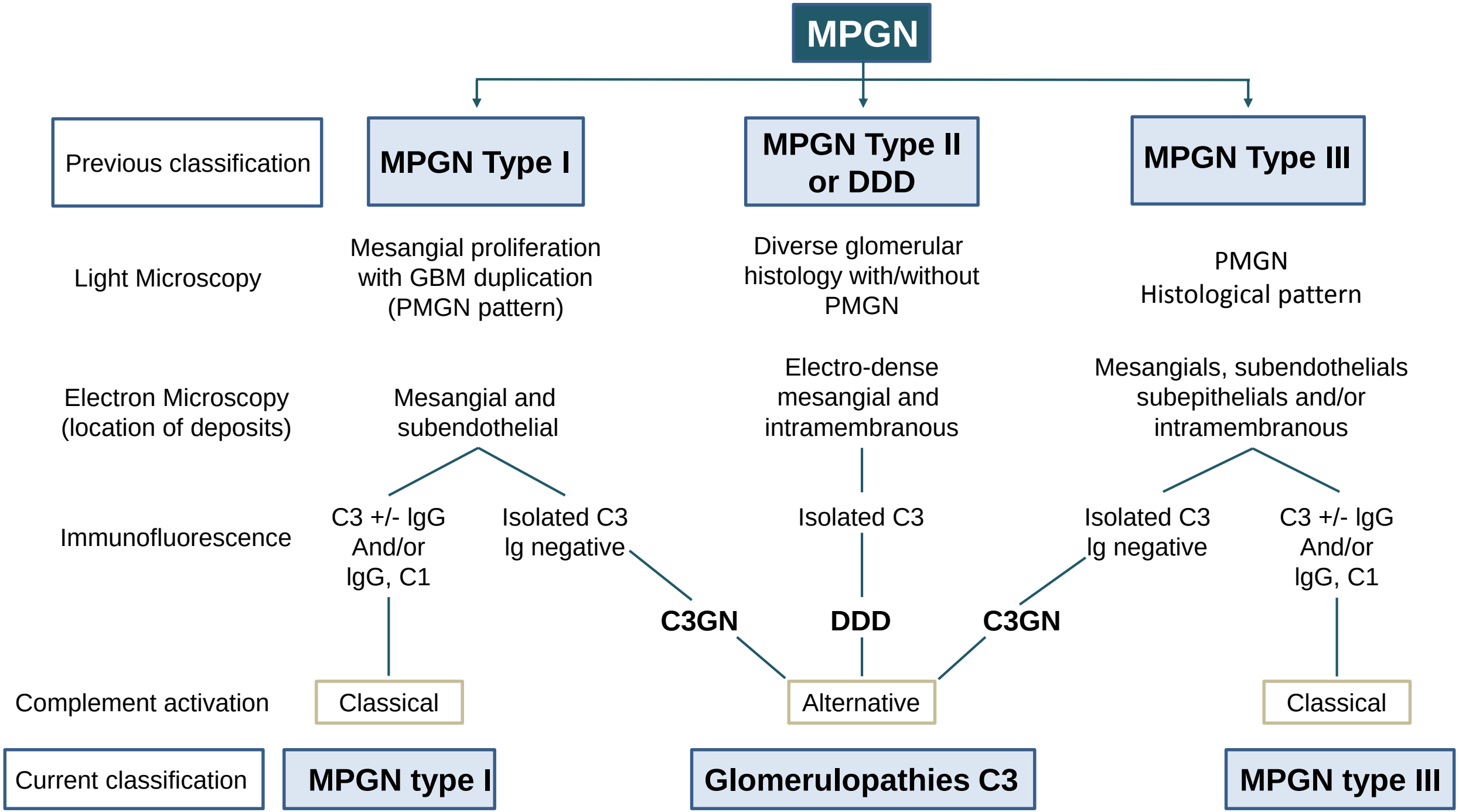
MPGN
Previous classification
MPGN Type I
MPGN Type II or DDD
MPGN Type III
Light Microscopy
Mesangial proliferation with GBM duplication (PMGN pattern)
Diverse glomerular histology with/without PMGN
PMGN Histological pattern
Electron Microscopy (location of deposits)
Mesangial and subendothelial
Electro-dense mesangial and intramembranous
Mesangials, subendothelials subepithelials and/or intramembranous
Immunofluorescence
C3 +/- IgG And/or IgG, C1
Isolated C3 Ig negative
Isolated C3
Isolated C3 Ig negative
C3 +/- IgG And/or IgG, C1
C3GN
DDD
C3GN
Complement activation
Classical
Alternative
Classical
Current classification
MPGN type I
Glomerulopathies C3
MPGN type III

Membranoproliferative GN

- Types I, II and III
- Children and young adults
- Nephrotic and nephritic
- Rare
- Secondary forms
  - older adults
  - most commonly associated with hepatitis C

UCSF

MPGN, 1

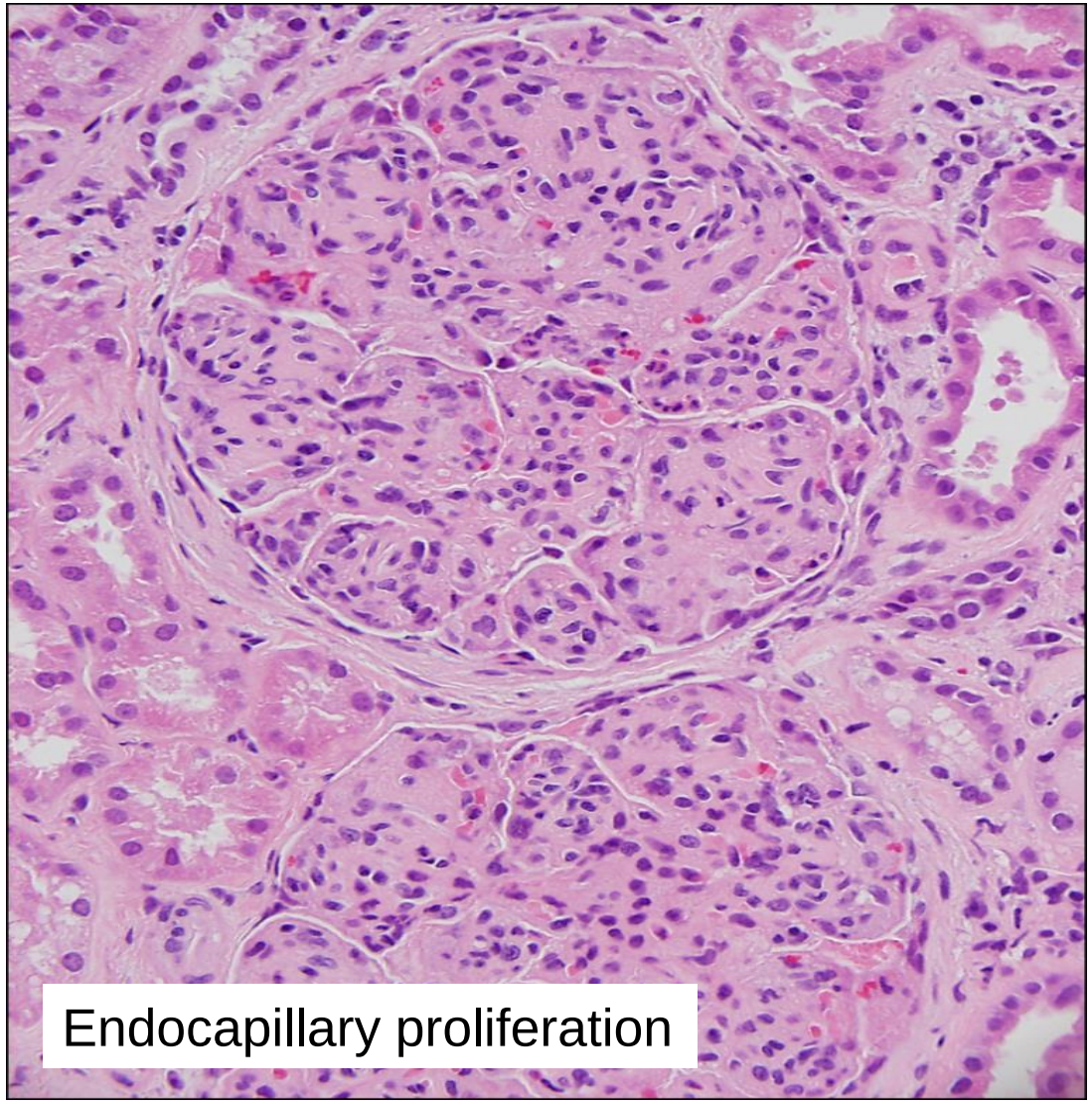
Endocapillary proliferation

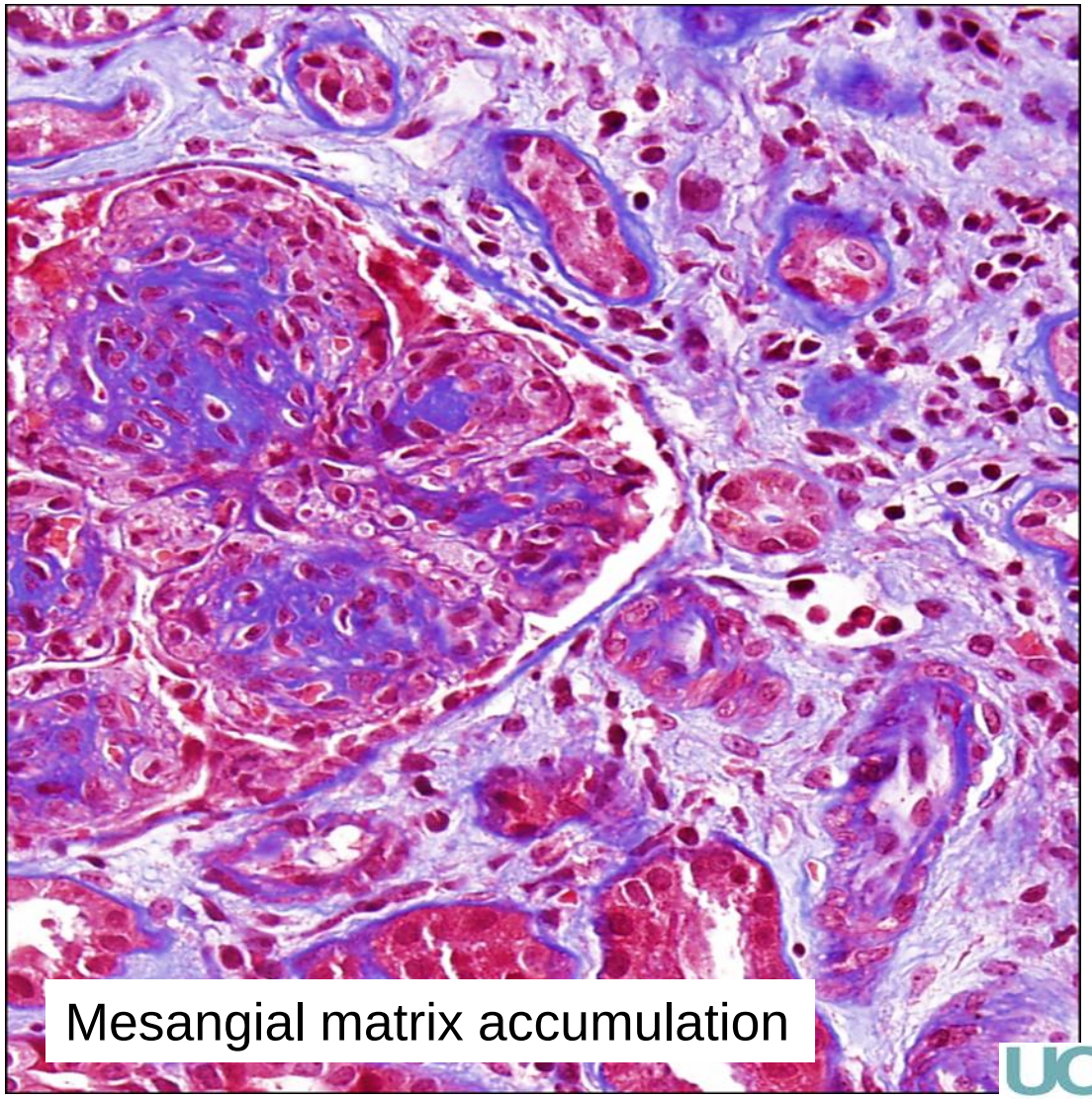
Mesangial matrix accumulation

MPGN, 1

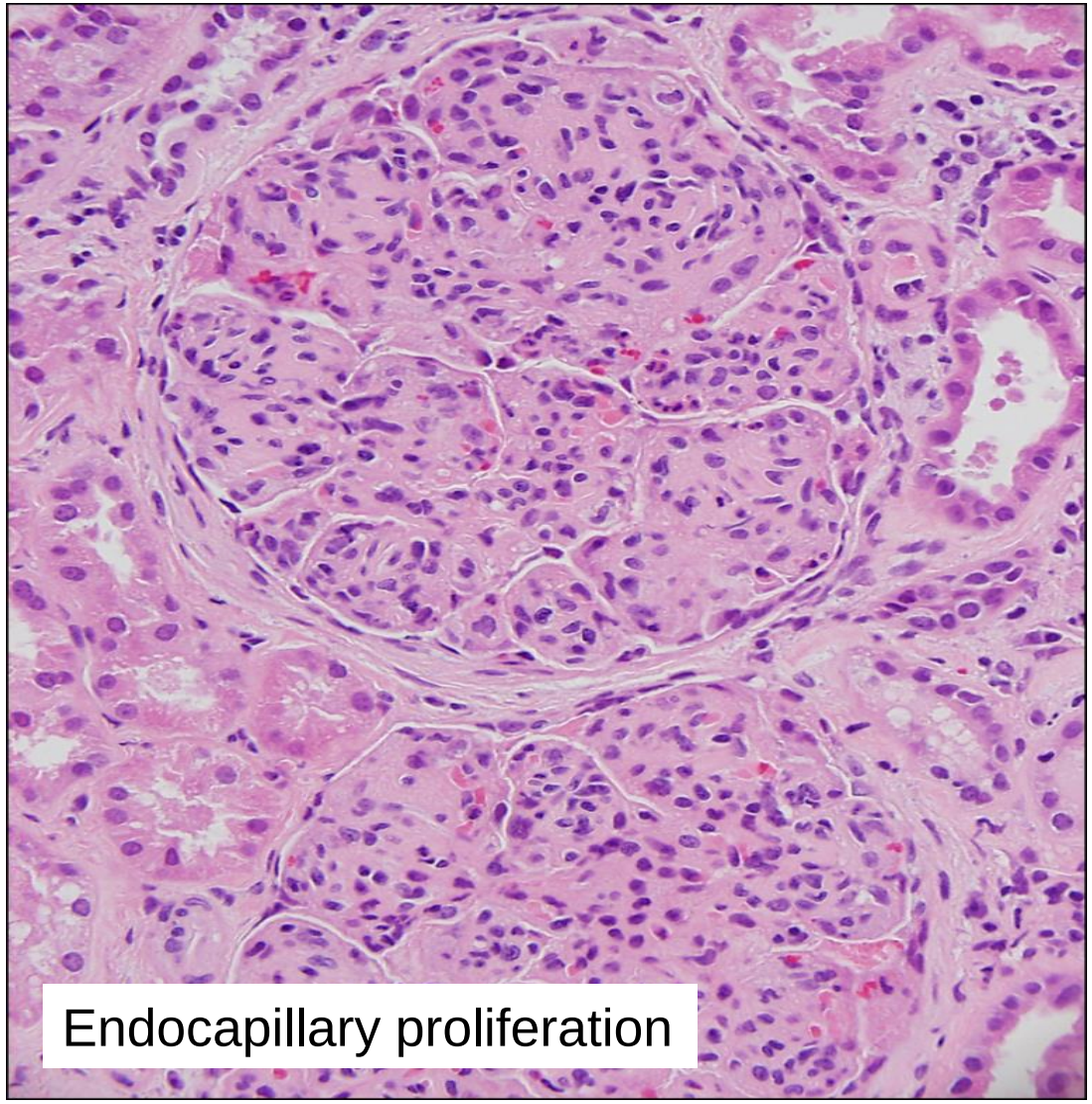
Endocapillary proliferation

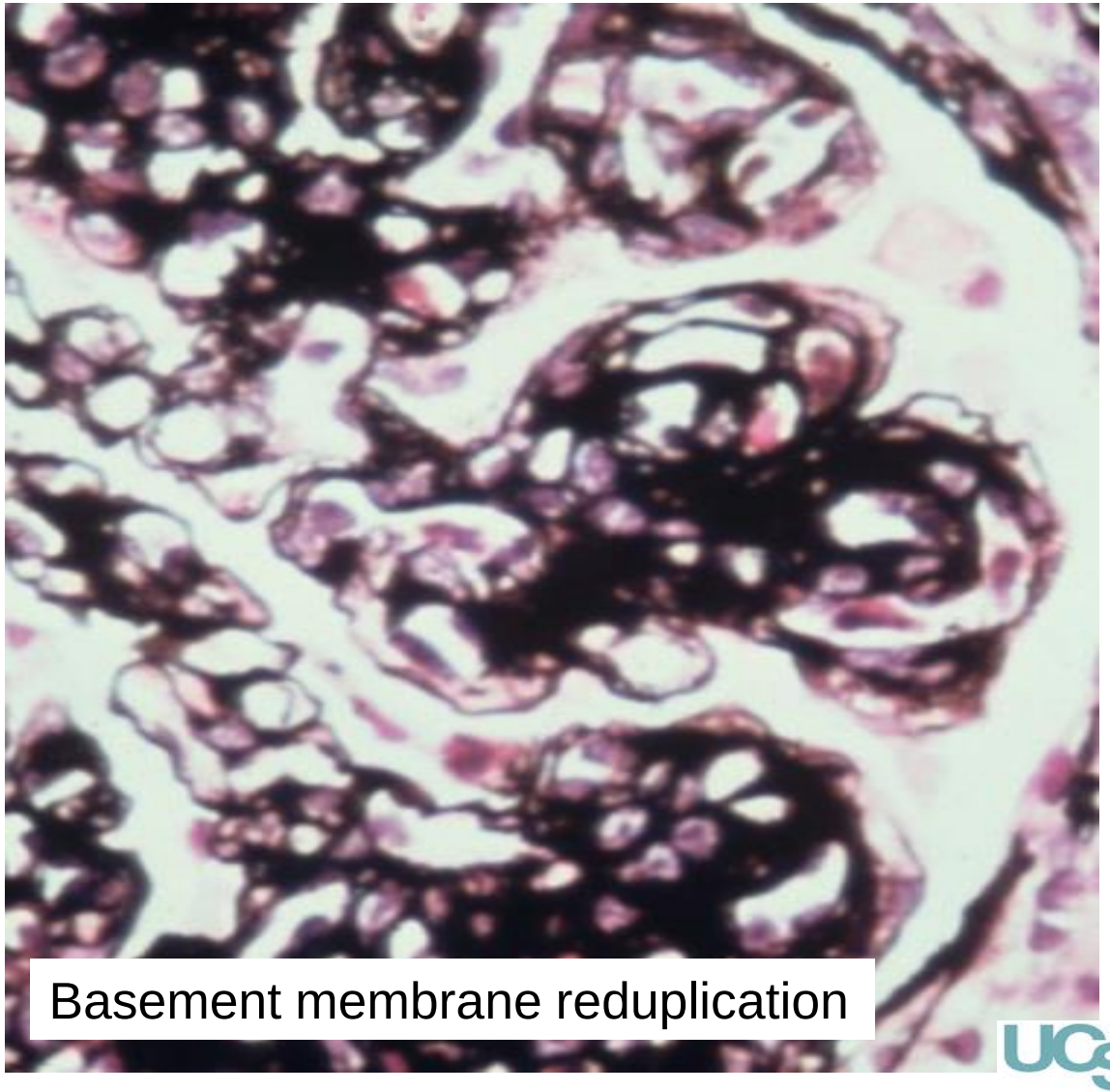
Basement membrane reduplication

MPGN, 1

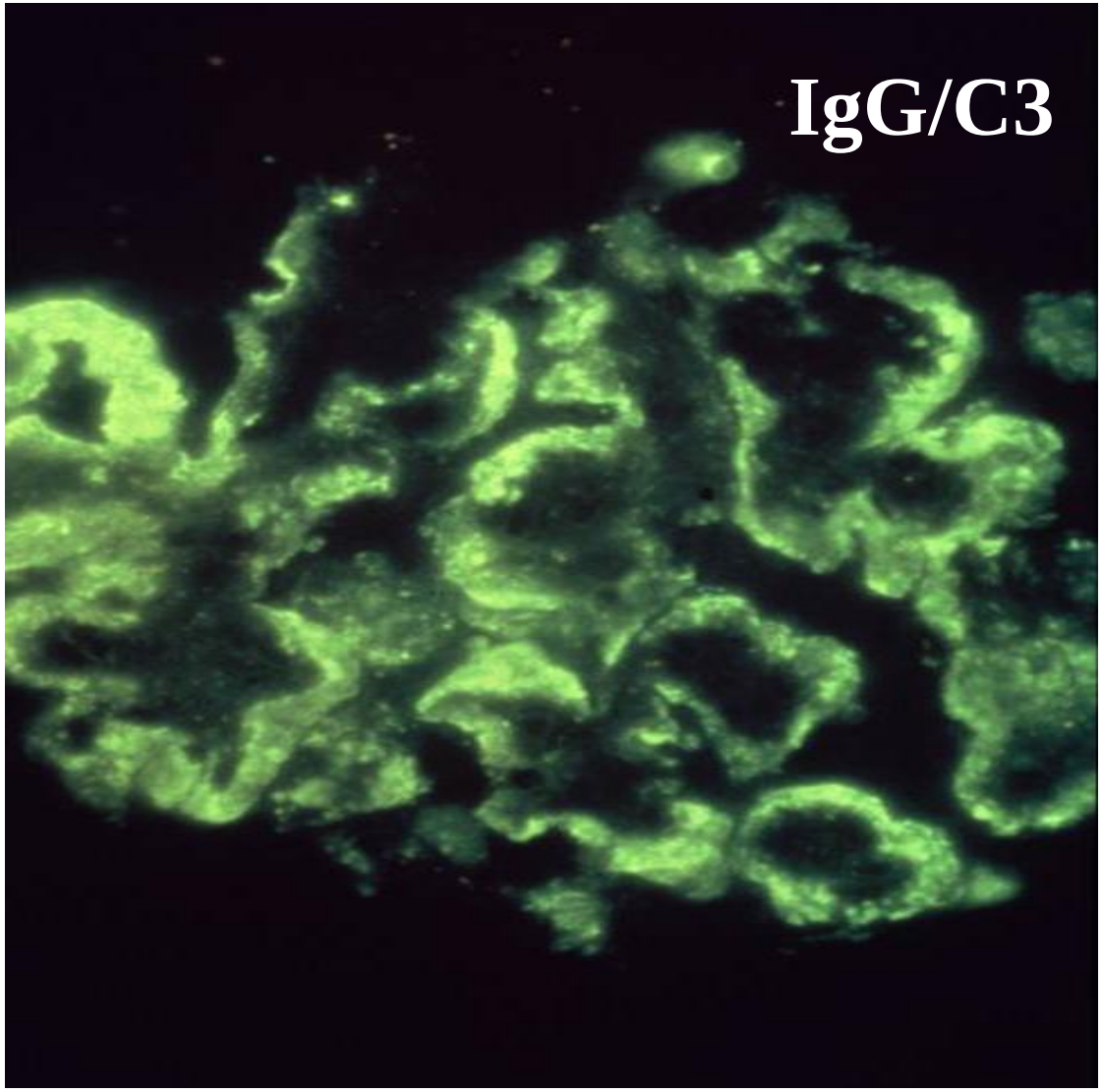

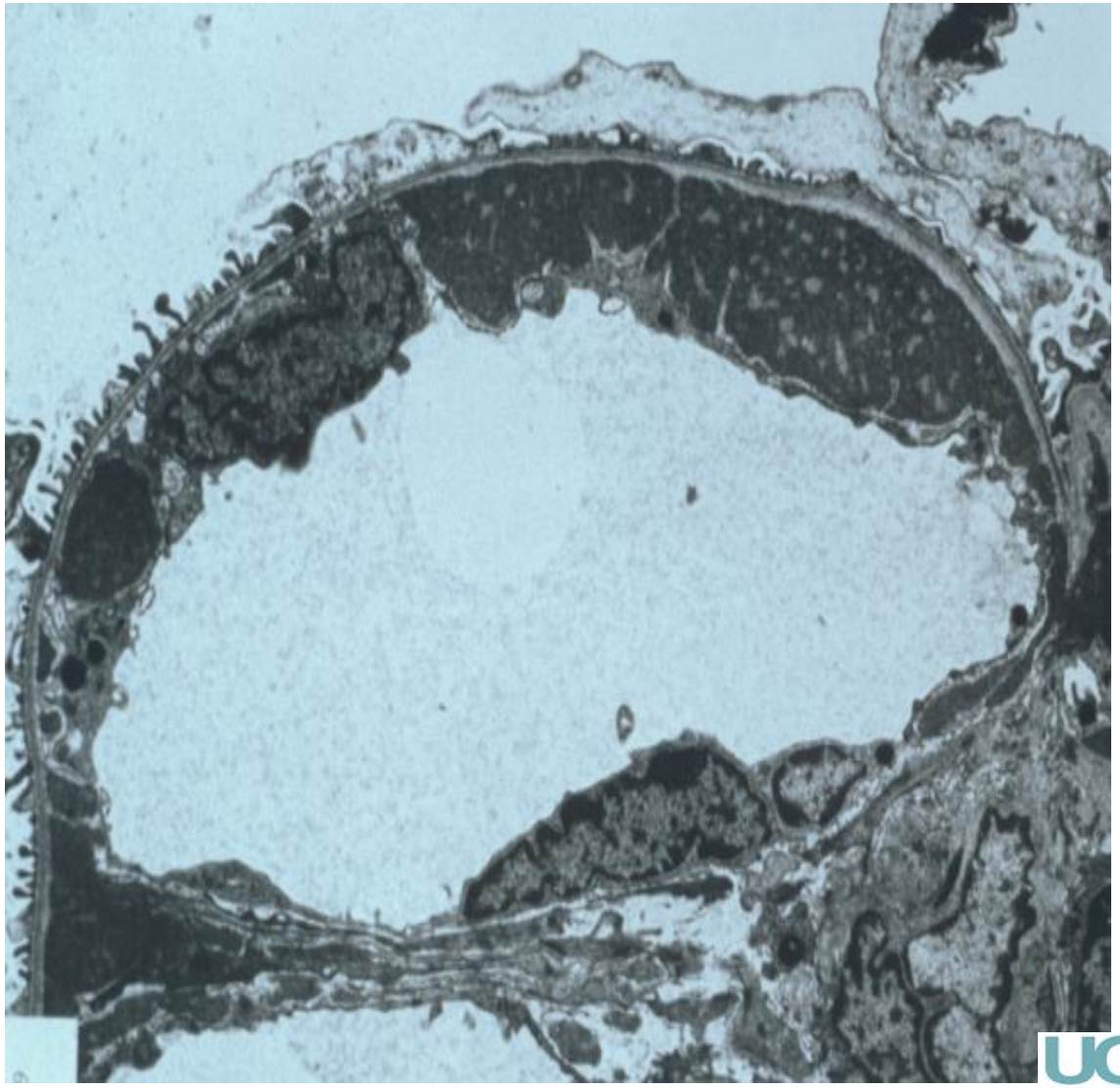

MPGN, type I, secondary forms

- Infections
  - Viral, bacterial, parasitic
- SLE
- Liver diseases
  - Hepatitis (C & B)
  - Cirrhosis or fibrosis (with or without hepatitis)
- Portosystemic shunt
  - With dominant IgA2 deposits

UCSF

Classic MPGN type 1 vs Cryoglobulinemic GN

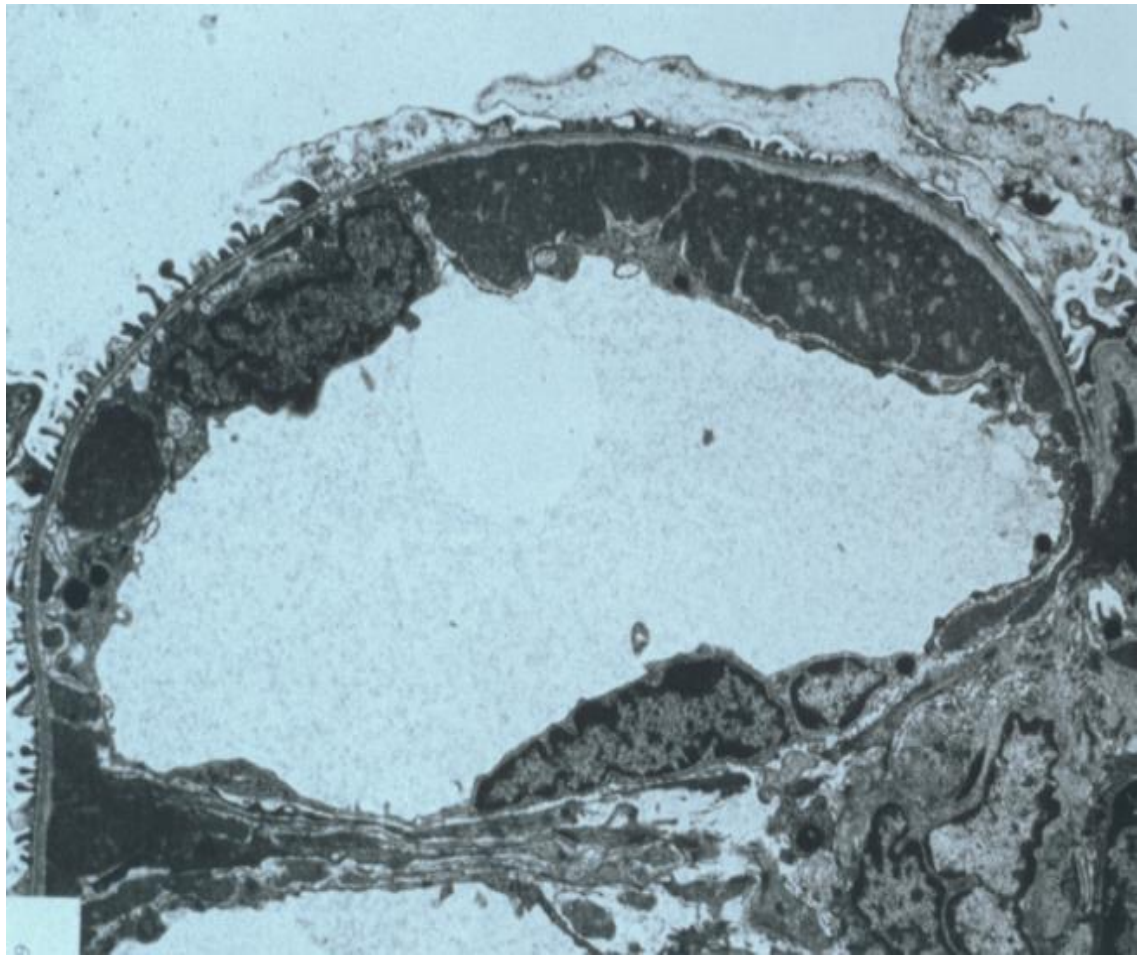

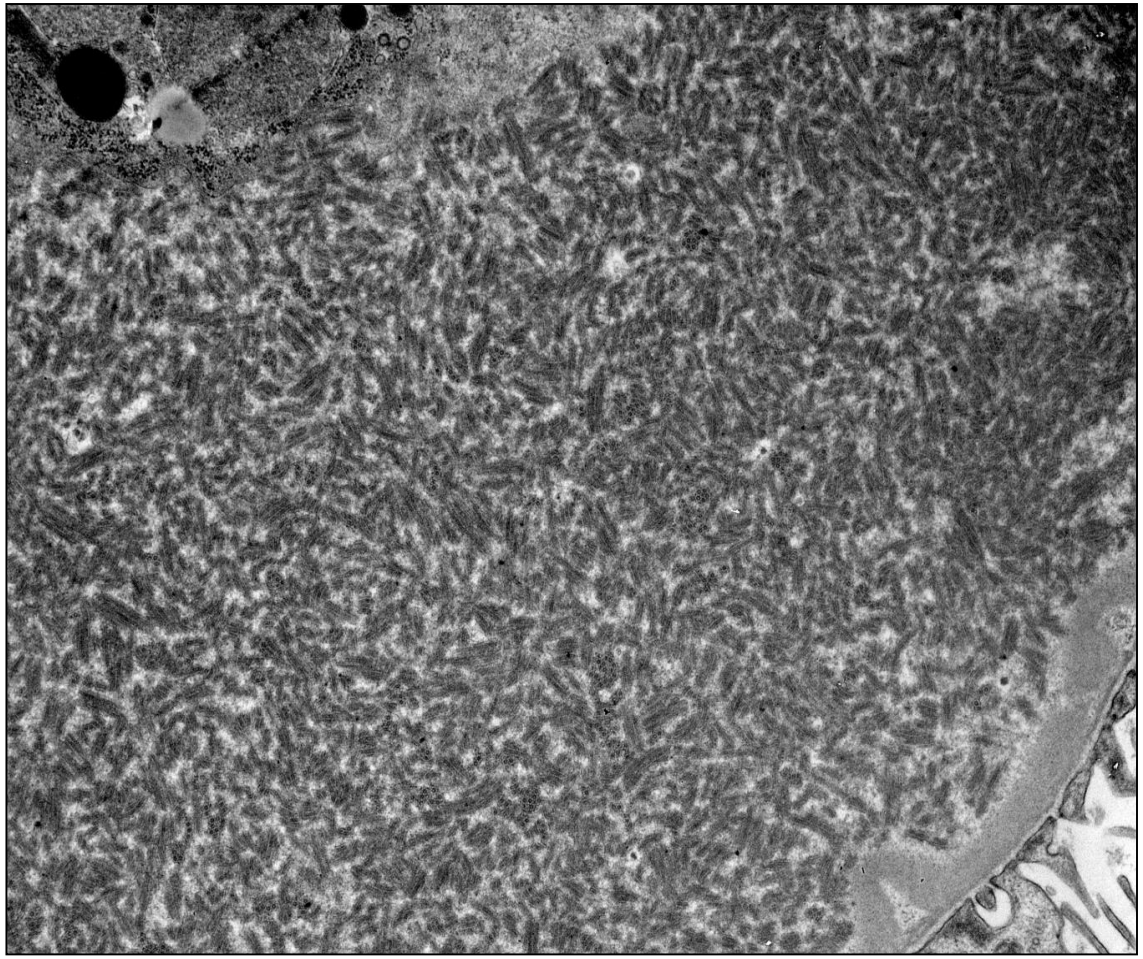

UCSF

Antibody mediated glomerular injury

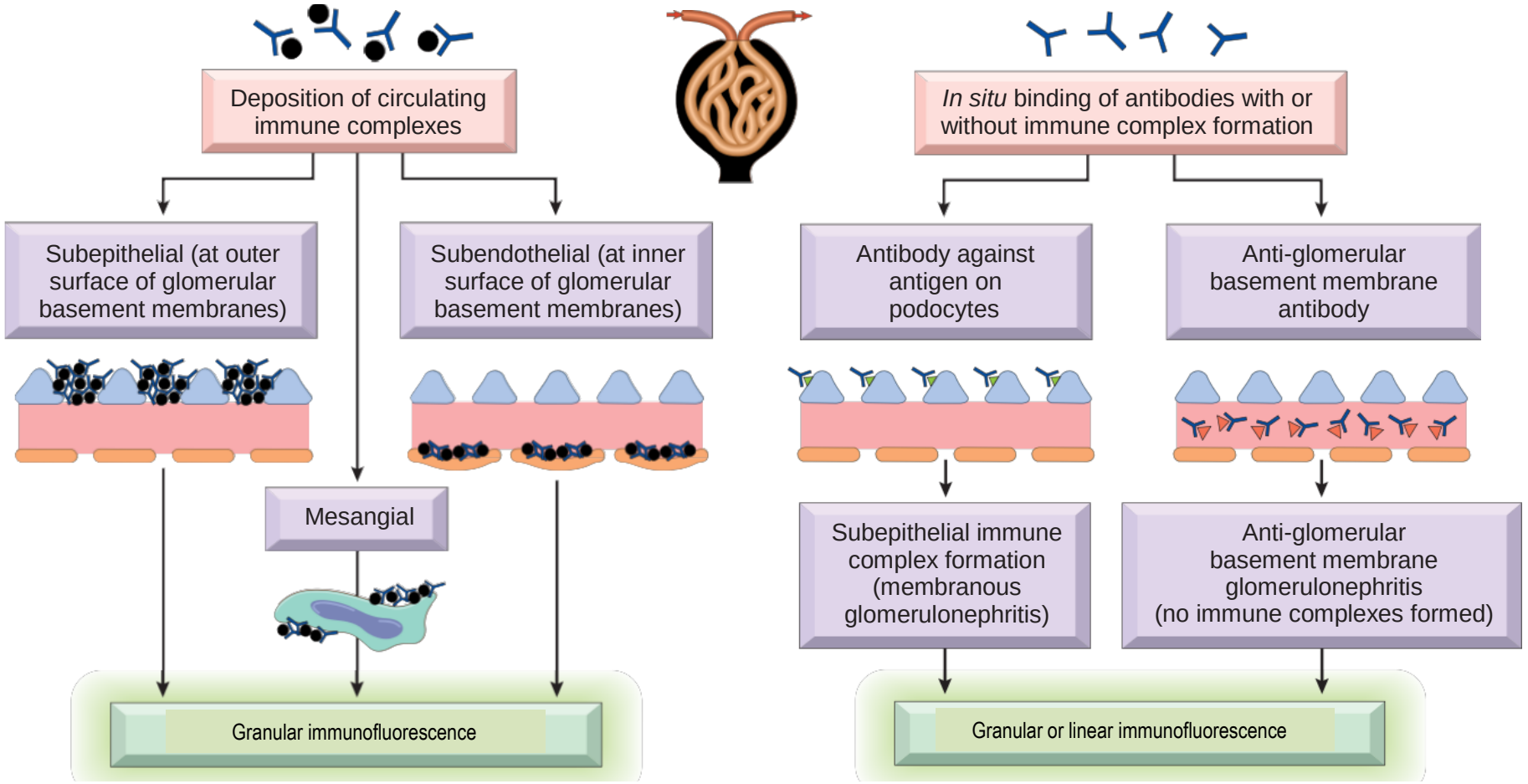

Dense Deposit Disease (MPGN, Type 2)

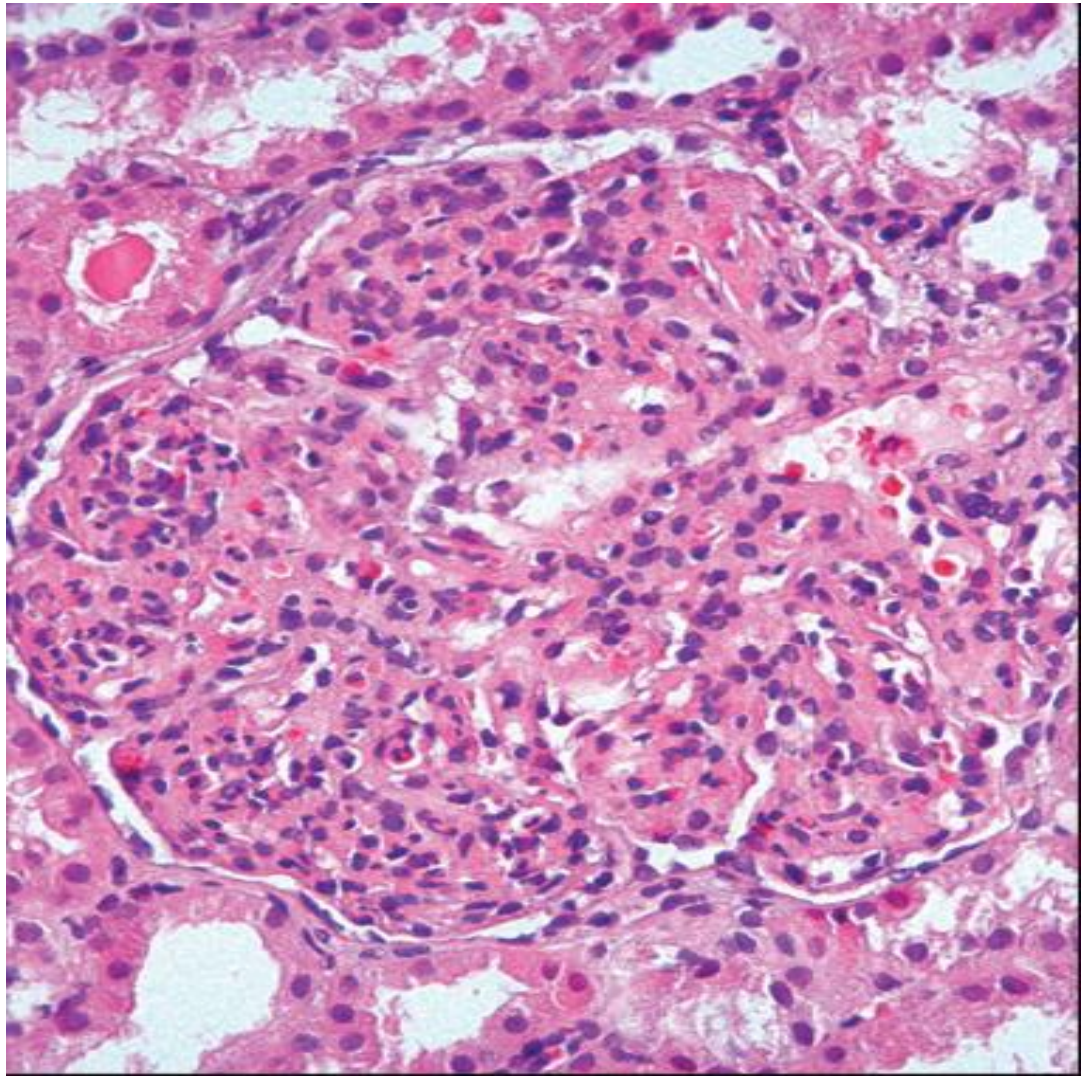

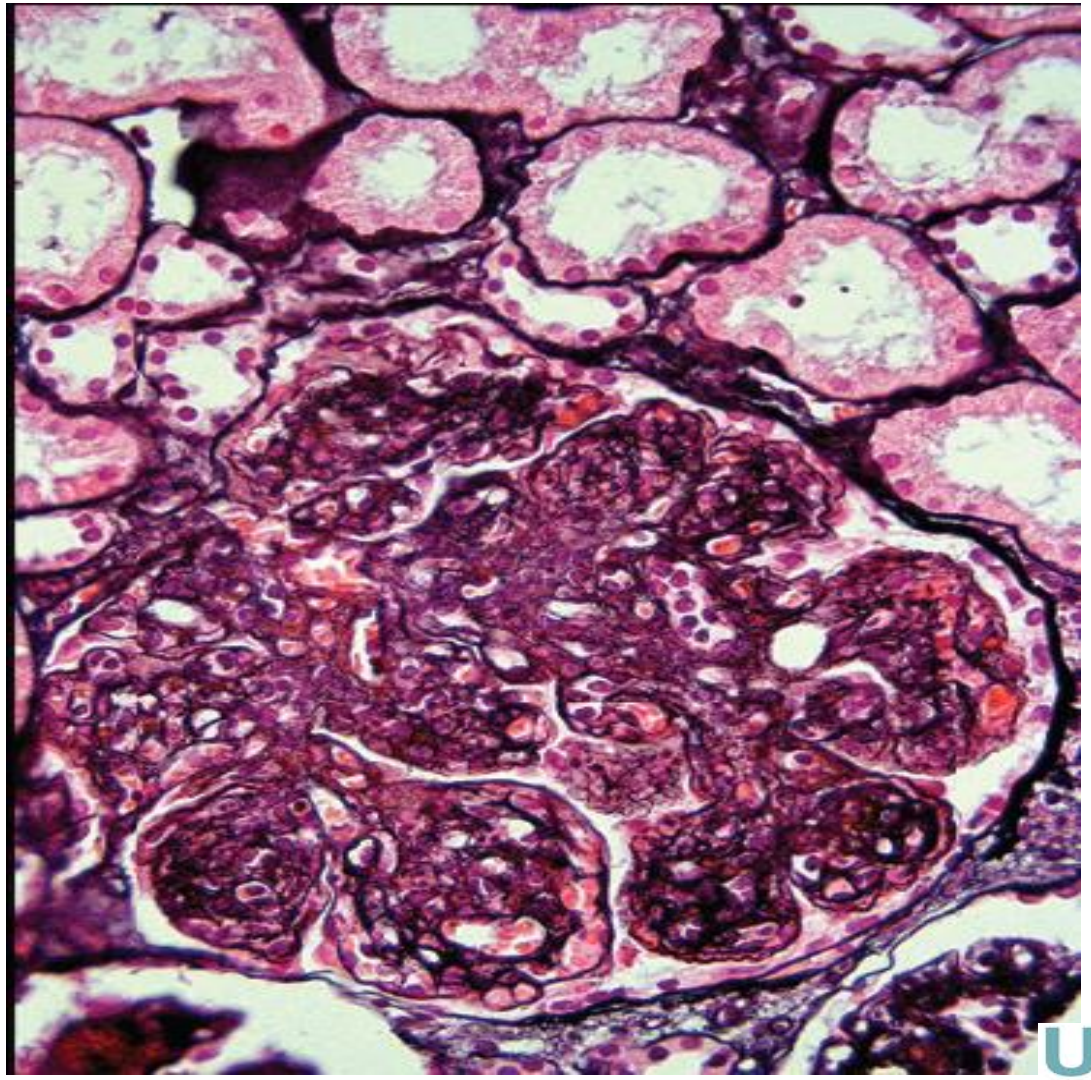

Dense Deposit Disease (MPGN, Type II)

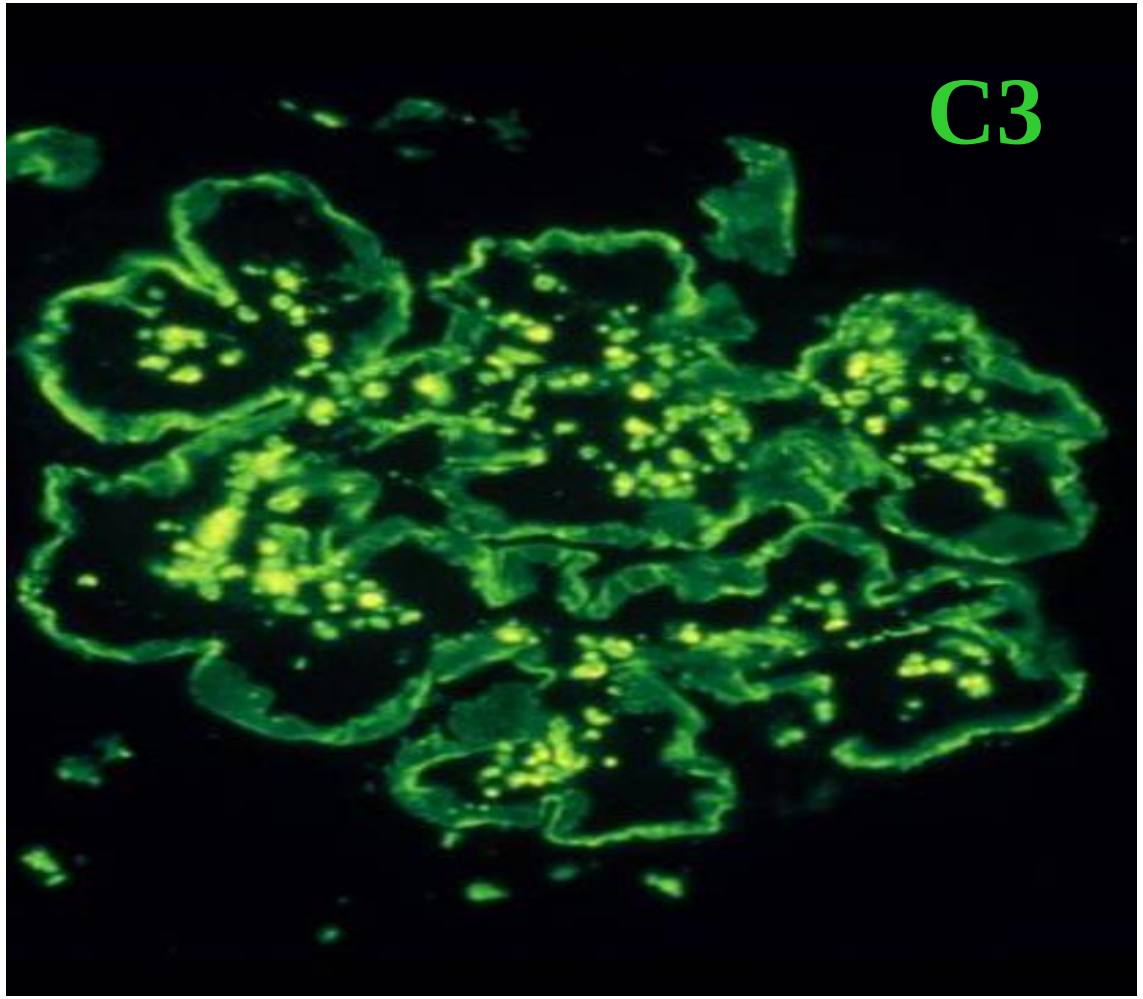

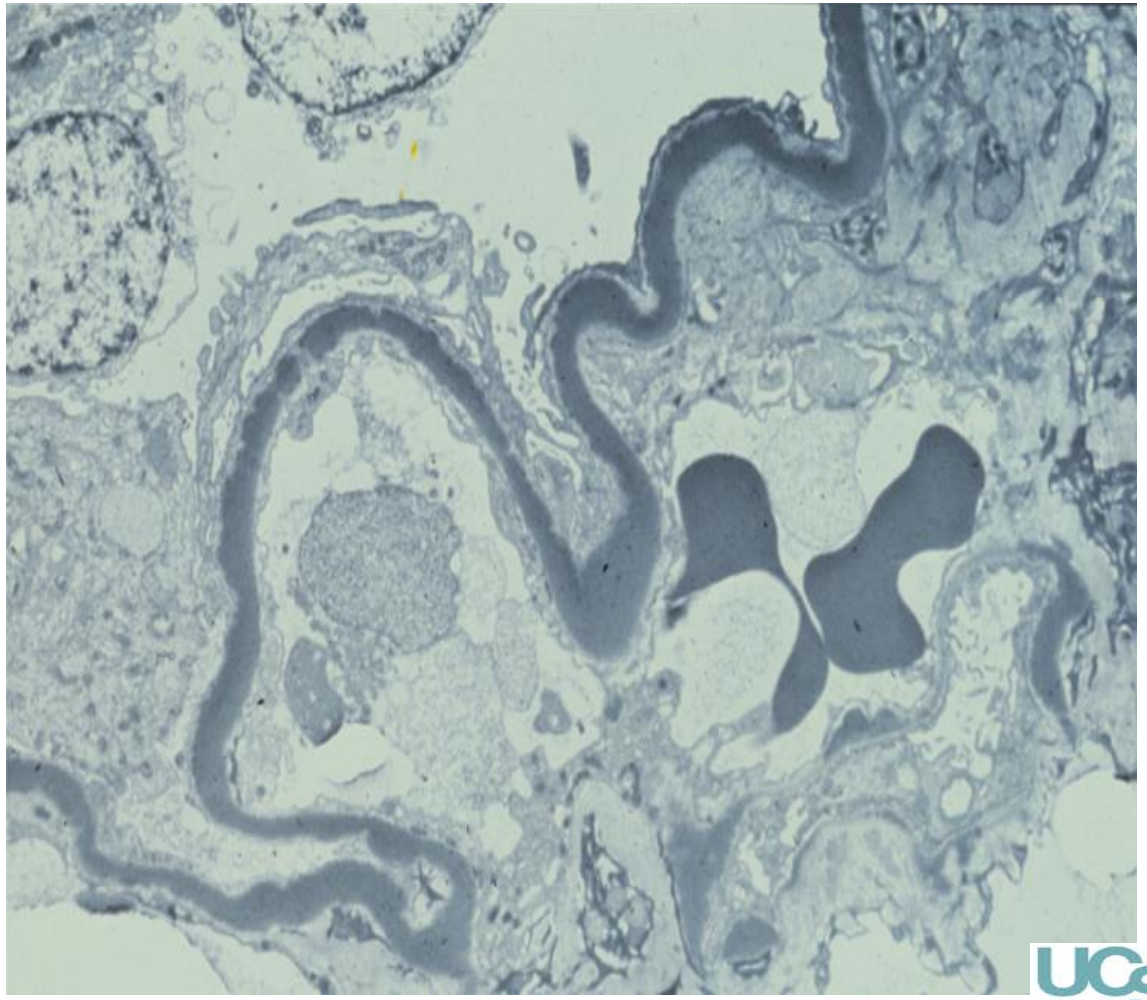

Dense deposit disease (DDD) (Type 2, MPGN)

- Recognized by transmission electron microscopy (1962)
- C3 glomerular deposition and low serum C3 levels attributed to the activation of the alternative pathway of complement (1975)
- In the 1980s, several reports in affected families indicated a genetic basis for some cases of DDD

Berger J, Galle P. J Urol Nephrol (Paris) 1962; 68: 116–122
Habib et al. Kidney Int 1975; 7: 204–215

UCSF

Dense Deposit Disease (Type 2, MPGN)
Clinical presentation

- Nephritic, proteinuria, hematuria, renal insufficiency
- Post tx recurrence common; outcome generally favorable
- Monoclonal gammopathy in older patients

UCSF

Dense Deposit Disease (MPGN, Type 2) Etiology

- Associated with complement dysregulation
  - C3NF (anti-C3 convertase)*
  - Genetic
    - Homozygous Factor H mutations
    - Heterozygous Factor H, I, MCP mutations*
- Low serum C3 (but not C4) common, but does not correlate with disease activity

Pediatr Nephrol (2011) 26:419-424

UCSF

C3 nephritic ‘factor’ (C3NeF)

- Existence inferred from the accelerated C3 breakdown *in vitro* following the addition to normal human serum of serum obtained from patient with persistent hypocomplementemic GN

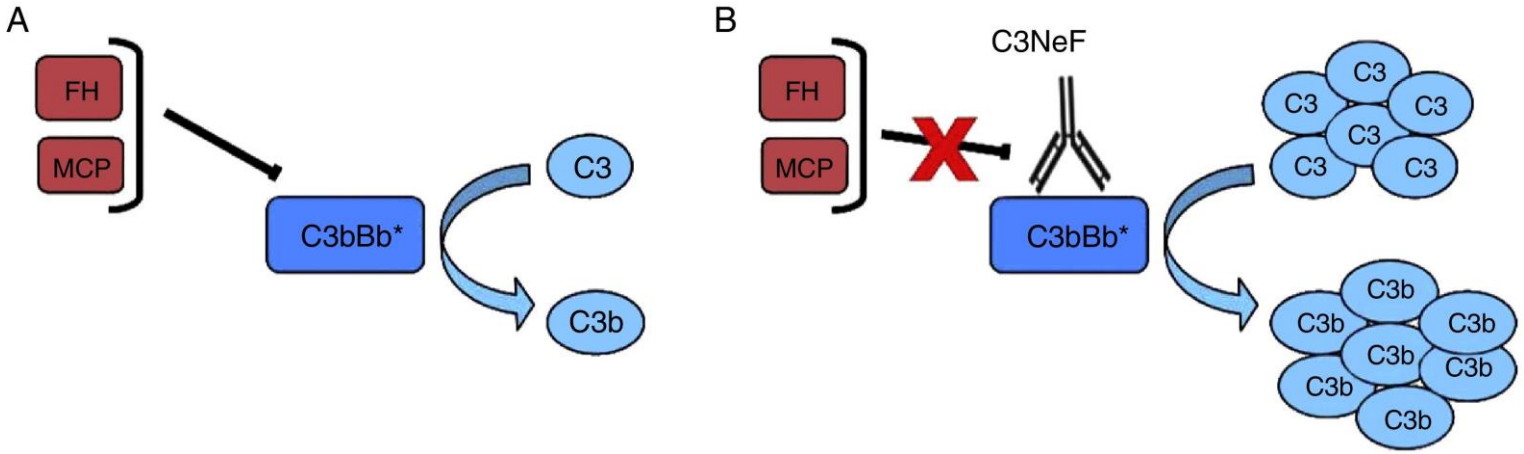

Spitzer RE et al. Serum C’3 lytic system in patients with glomerulonephritis. Science 1969; 164: 436–437

DDD, IF & Mass Spec

- 41% C3 only (without Ig)
- 59% dominant C3 with up to 1+ IgM
  - 80% dominant C3 of X2 orders of magnitude of intensity by IF greater than any other immune reactant
- Complement C3, MAC components, CFHR5, vitronectin and apolipoprotein E
- Absence of CFB
  - consistent with AP C3 convertase formation with excessive C3 activation in the fluid phase, with subsequent deposition of C3 breakdown products

Hou J et al. KI 2013 doi:10.1038/ki.2013.340.

UCSF

Mechanisms of glomerular diseases

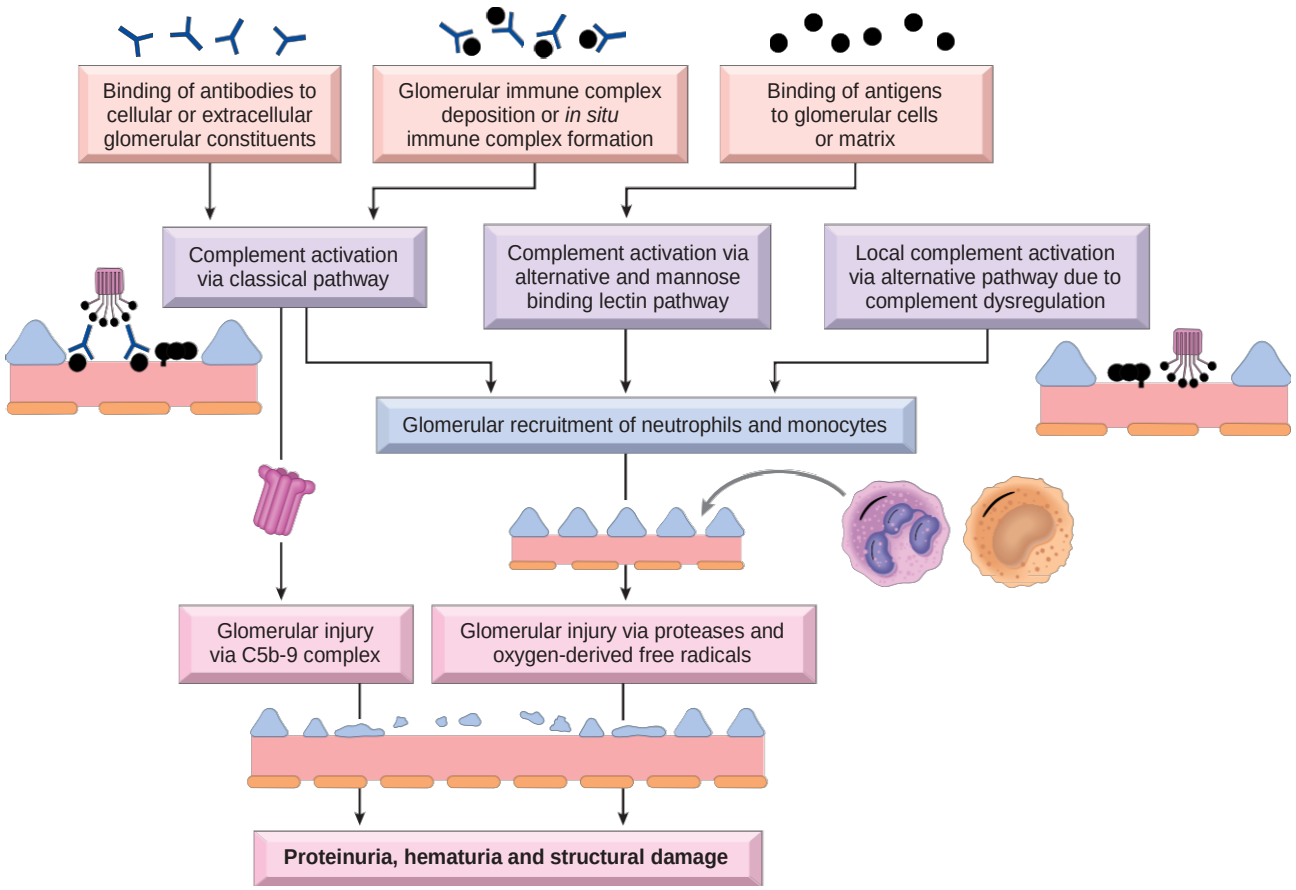

f0030

- Immune mechanisms
  - Circulating Immune Complexes
  - Immune Complexes Formed In Situ
  - Anti-GBM Antibody–Mediated
  - Caused by Abnormal Complement Activation
- Mediators of immune injury
  - Complement and leukocytes
- Podocyte injury
- Nephron loss

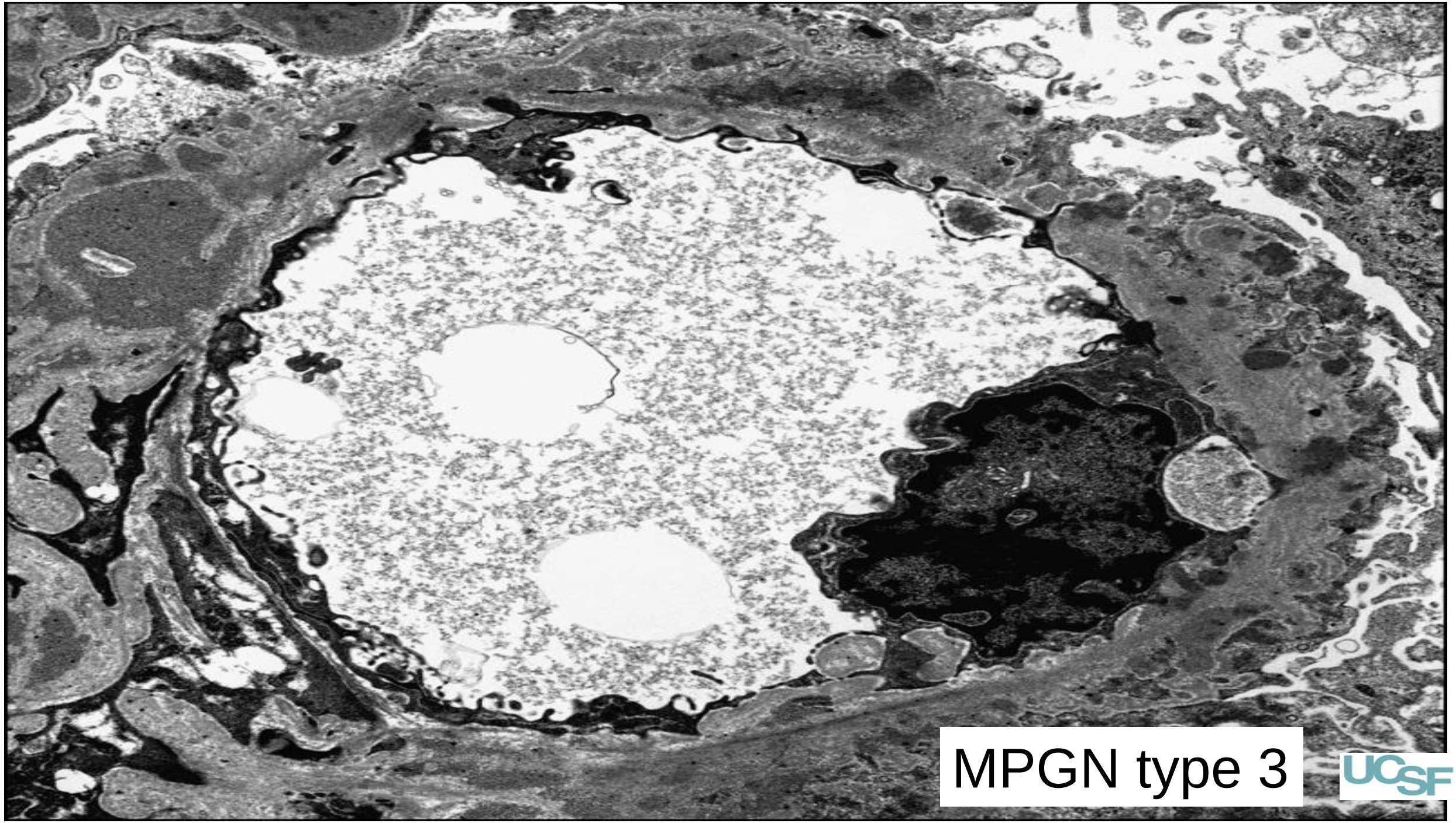
MPGN type 3
UCSF

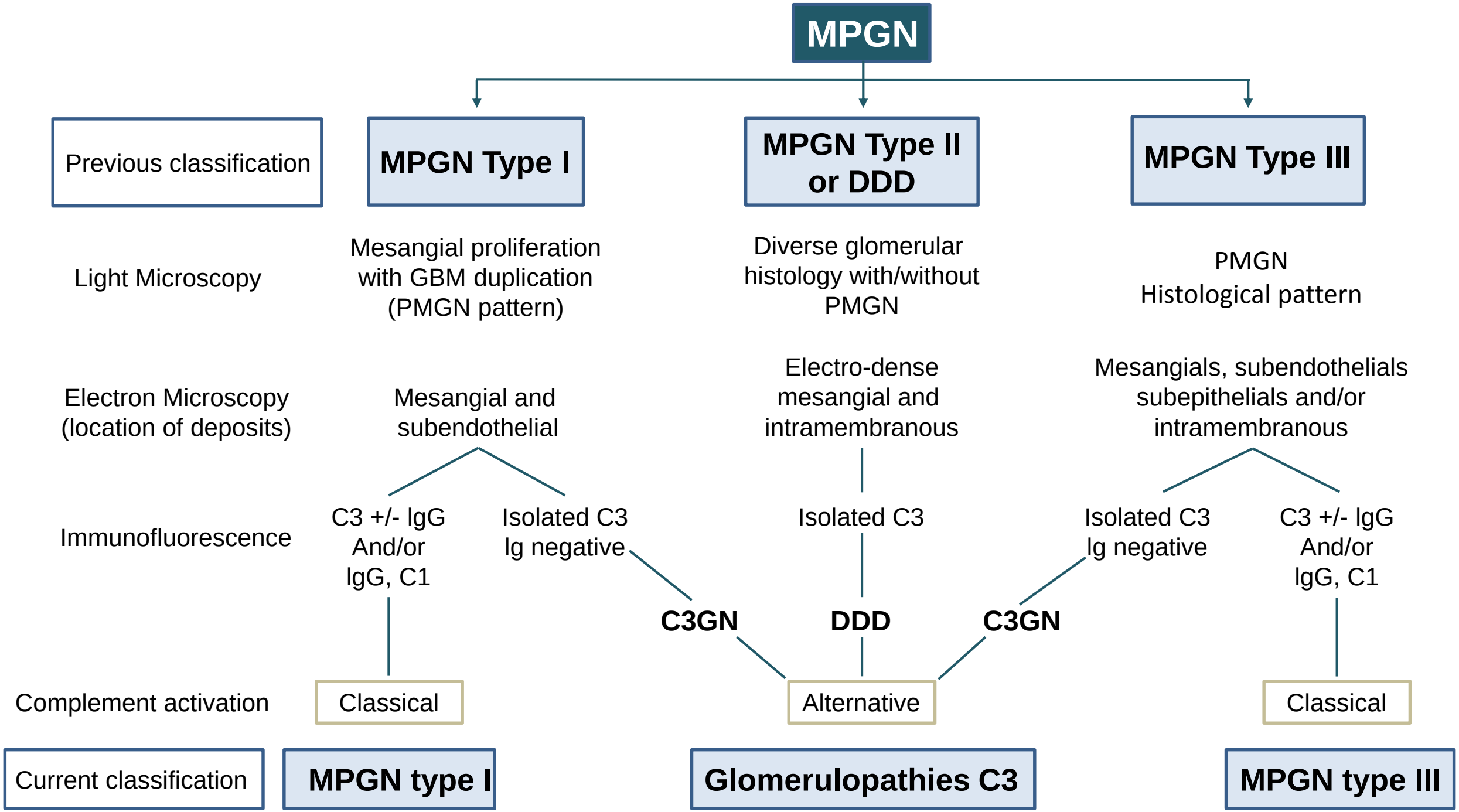
MPGN
Previous classification
MPGN Type I
MPGN Type II or DDD
MPGN Type III
Light Microscopy
Mesangial proliferation with GBM duplication (PMGN pattern)
Diverse glomerular histology with/without PMGN
PMGN Histological pattern
Electron Microscopy (location of deposits)
Mesangial and subendothelial
Electro-dense mesangial and intramembranous
Mesangials, subendothelials subepithelials and/or intramembranous
Immunofluorescence
C3 +/- IgG And/or IgG, C1
Isolated C3 Ig negative
Isolated C3
Isolated C3 Ig negative
C3 +/- IgG And/or IgG, C1
C3GN
DDD
C3GN
Complement activation
Classical
Alternative
Classical
Current classification
MPGN type I
Glomerulopathies C3
MPGN type III

C3 Glomerulonephritis

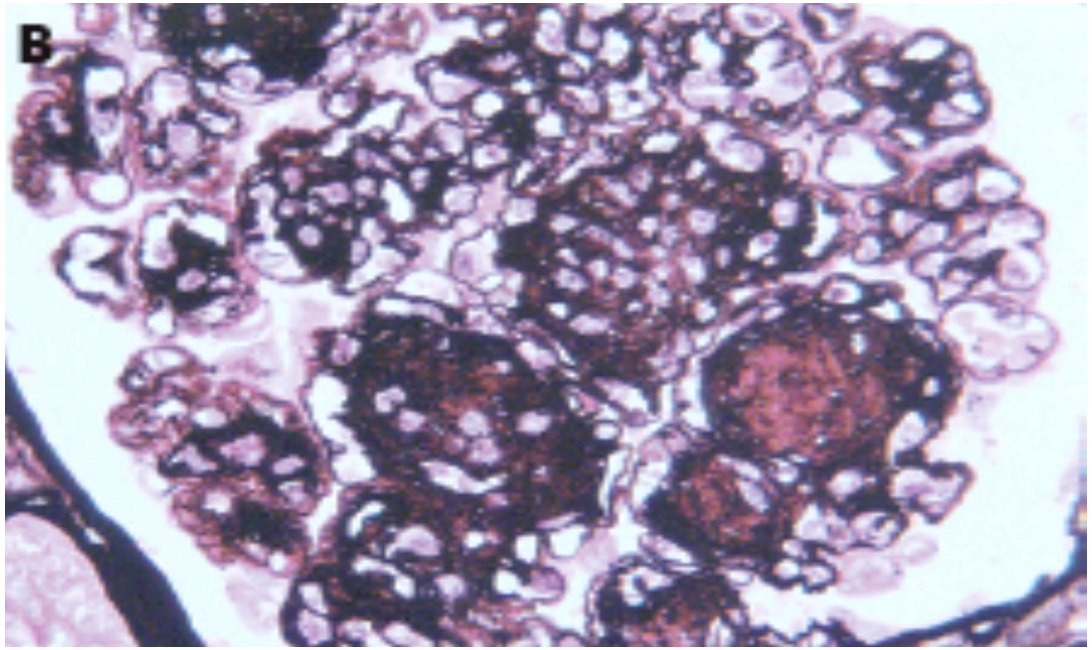

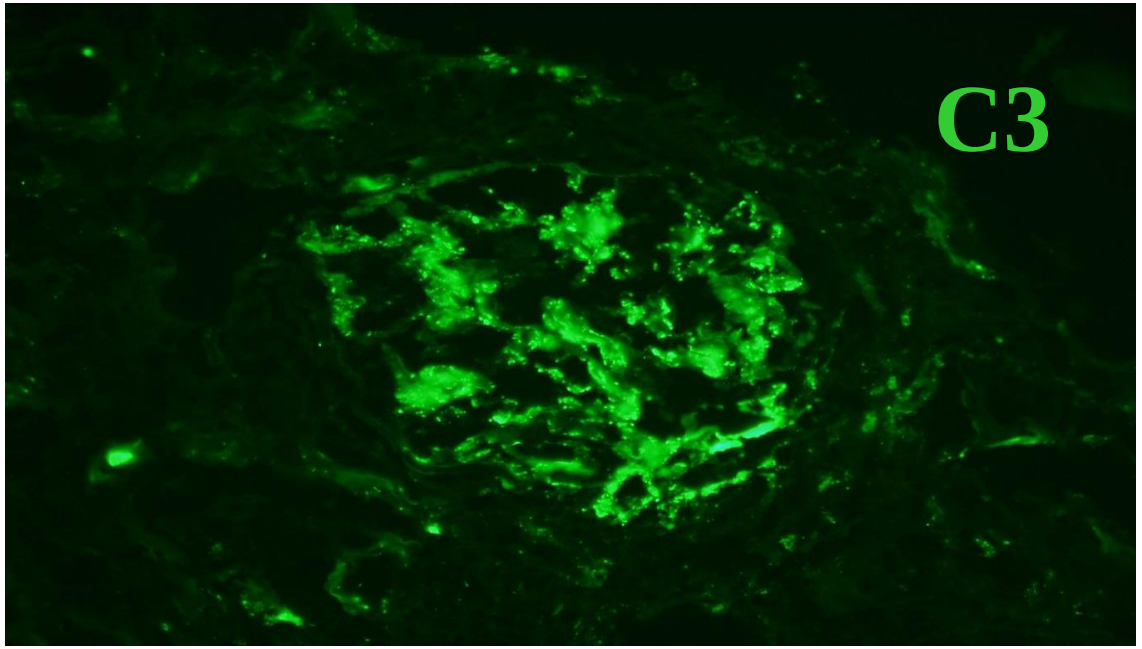

Servais A, Fremeaux-Bacchi V, et al. Primary glomerulonephritis with isolated C3 deposits: a new entity which shares common genetic risk factors with haemolytic uraemic syndrome. *J Med Genet*. (2007) **44**:193-199.

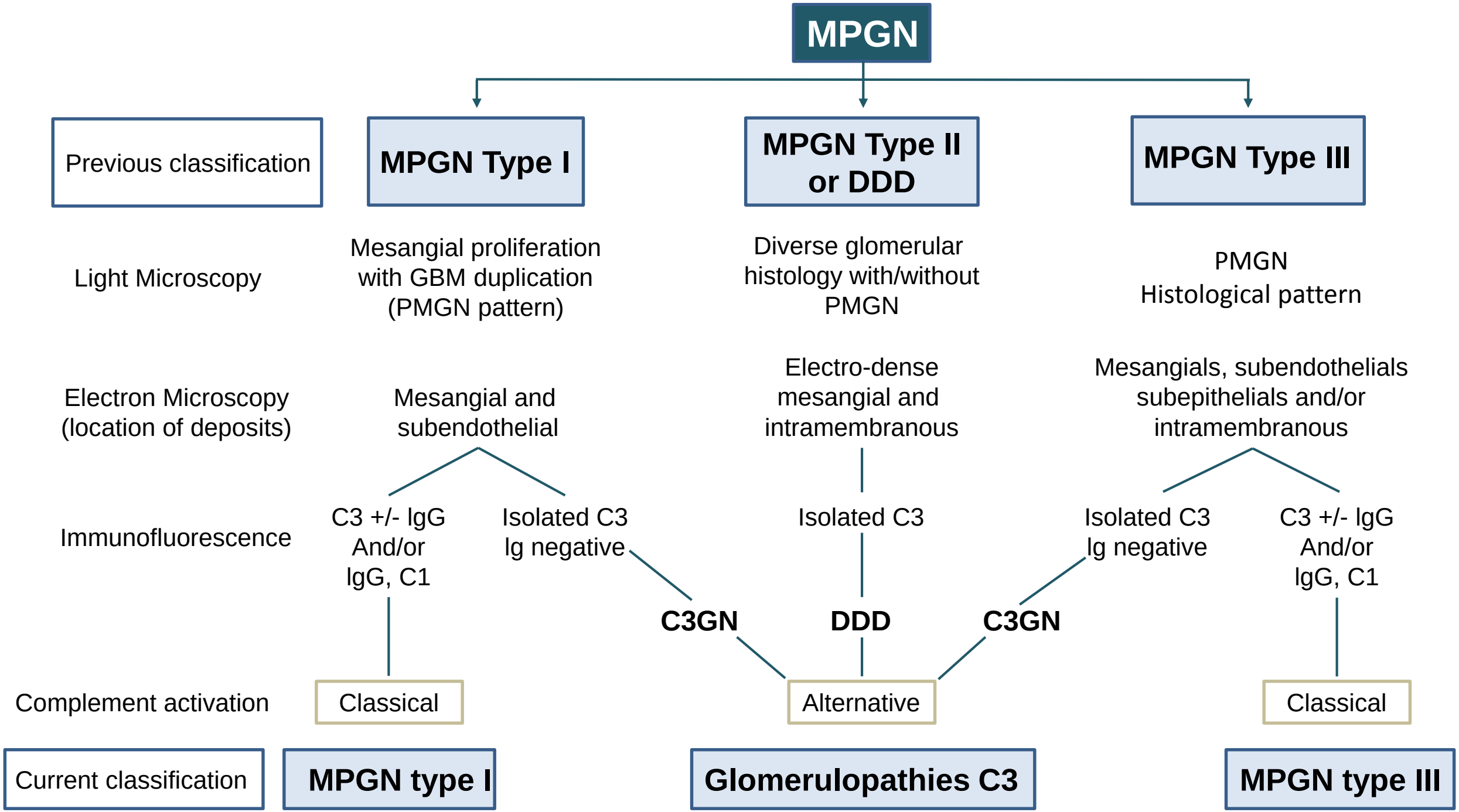
MPGN
Previous classification
MPGN Type I
MPGN Type II or DDD
MPGN Type III
Light Microscopy
Mesangial proliferation with GBM duplication (PMGN pattern)
Diverse glomerular histology with/without PMGN
PMGN Histological pattern
Electron Microscopy (location of deposits)
Mesangial and subendothelial
Electro-dense mesangial and intramembranous
Mesangials, subendothelials subepithelials and/or intramembranous
Immunofluorescence
C3 +/- IgG And/or IgG, C1
Isolated C3 Ig negative
Isolated C3
Isolated C3 Ig negative
C3 +/- IgG And/or IgG, C1
C3GN
DDD
C3GN
Complement activation
Classical
Alternative
Classical
Current classification
MPGN type I
Glomerulopathies C3
MPGN type III

C3 glomerulopathies

- dense deposit disease (DDD) (Formerly MPGN type 2)
- C3 glomerulonephritis (C3GN)
- FHR5 nephropathy

UCSF

C3 glomerulopathies

- Key histological feature
  - isolated complement C3 glomerular deposits with no or little immunoglobulins
- Etiology
  - dysregulation of the alternative pathway of complement
  - genetic defects and/or autoantibodies are identified in a proportion of patients

UCSF

Autoantibodies in C3 glomerulopathies

C3NeF

- Common in DDD, less so in C3GN
- Levels do not correlate with the course of nephritis in DDD
- Nonspecific
  - frequent in MPGN Type 1 and rarely in LN or individuals without renal disease

Other autoantibodies

- To CFB (one patient with DDD) - stabilizes AP C3 convertase
- To CFB and C3b (two patients with DDD)
- Anti-CFH monoclonal light chains or (possibly monoclonal) Ig, inhibitory (DDD and C3GN)
- CFH autoantibodies (C3GN)

UCSF

C3 GN: Genetic abnormalities

- Original French C3GN series
  - heterozygous mutations in the CFH, CFI and MCP genes
- Additional cases of DDD, C3GN, and MPGN Type 1
  - homozygous CFH, heterozygous CFH and CFI mutations
- DDD (50%), C3GN (27%) and MPGN Type 1 (17%)
  - CFH, CFI, CD46 and C3

Servais A et al. KI 2012; 82: 454–464.
Zhao W et al. (2018). Genetic analysis of the complement pathway in C3 glomerulopathy. Nephrol Dial Transplar

UCSF

DDD vs. C3GN IF (C3c)

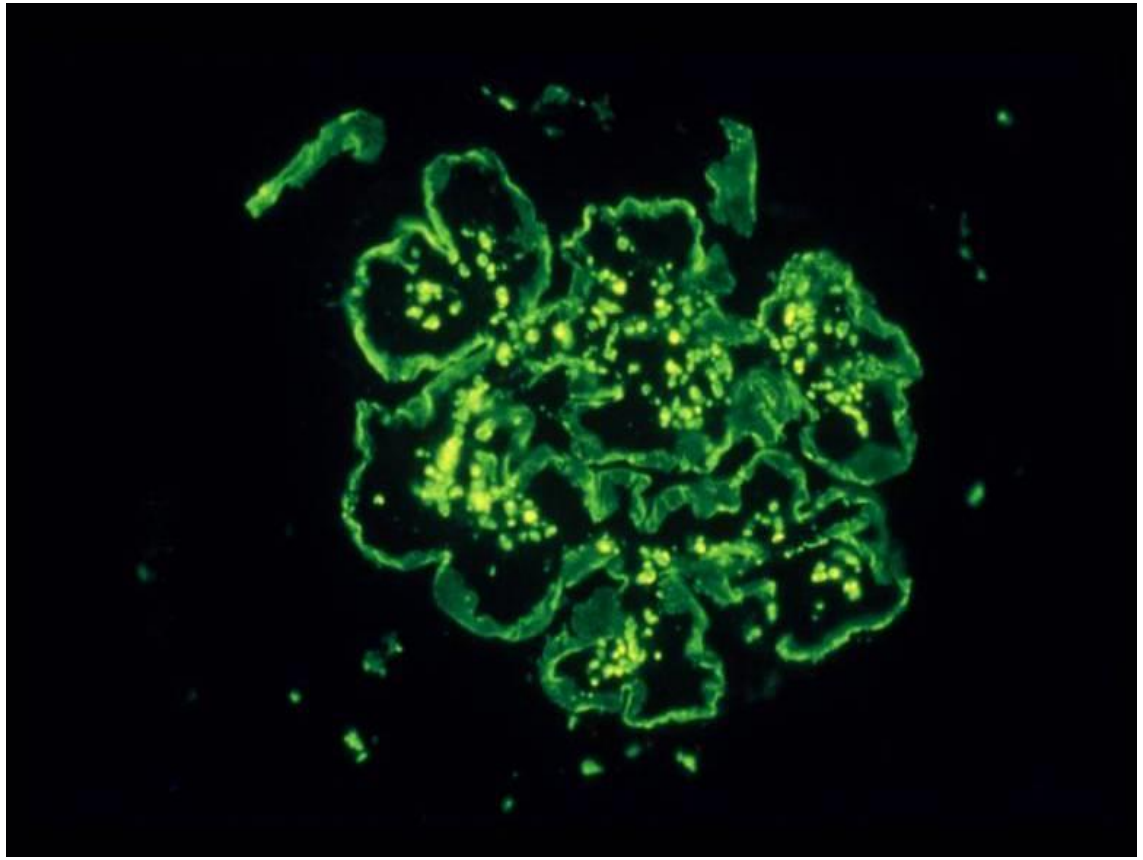

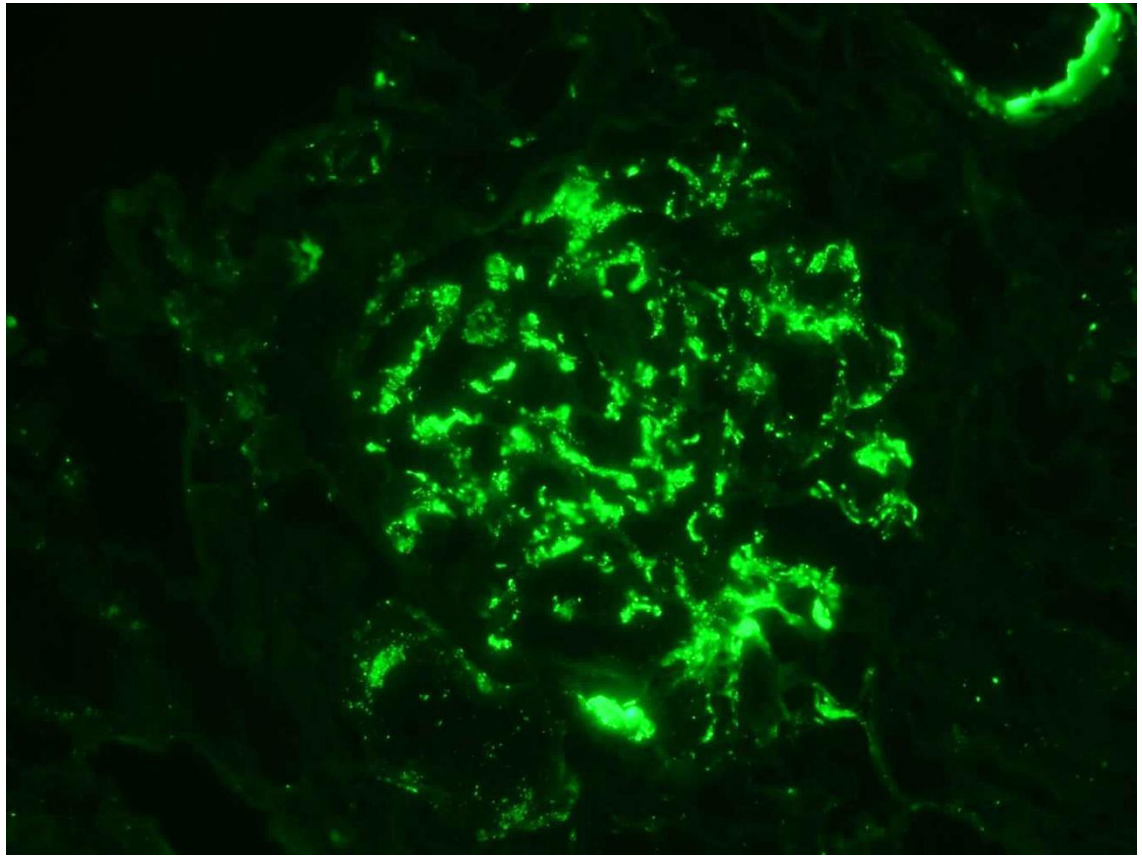

UCSF

DDD vs. C3GN EM

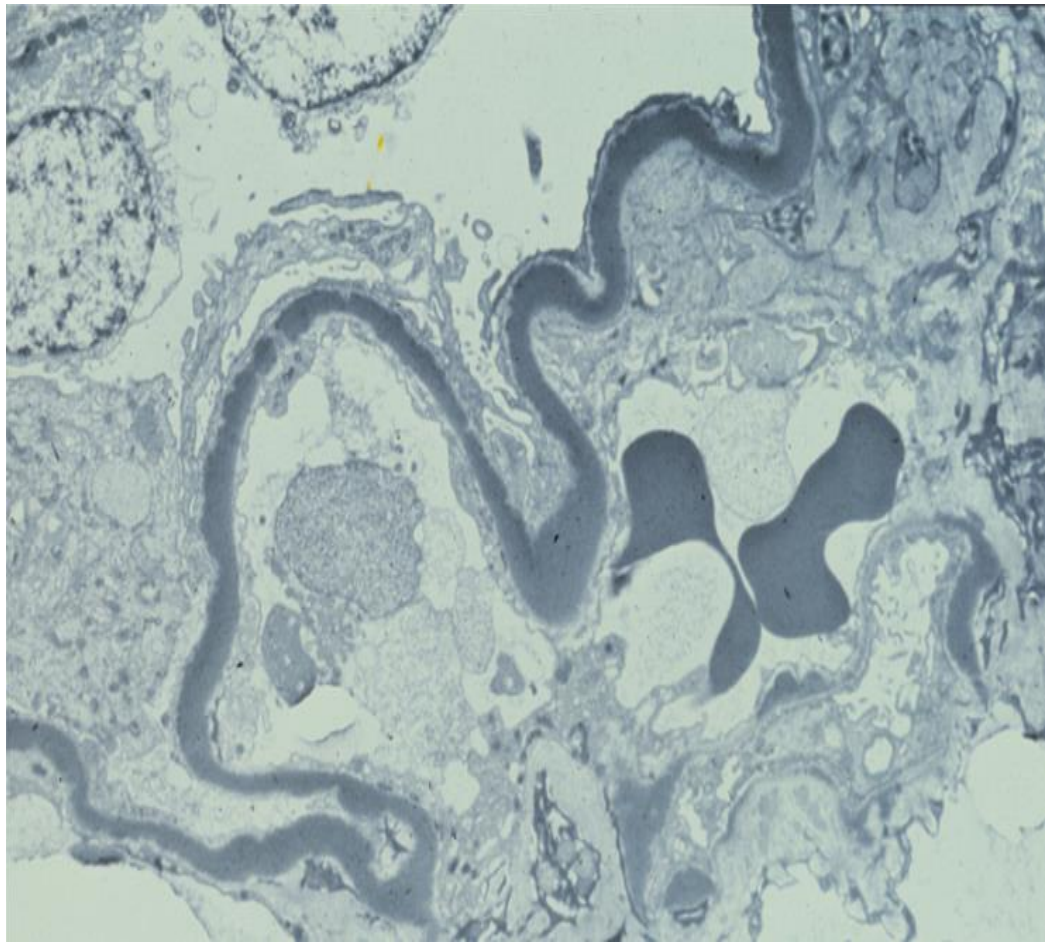

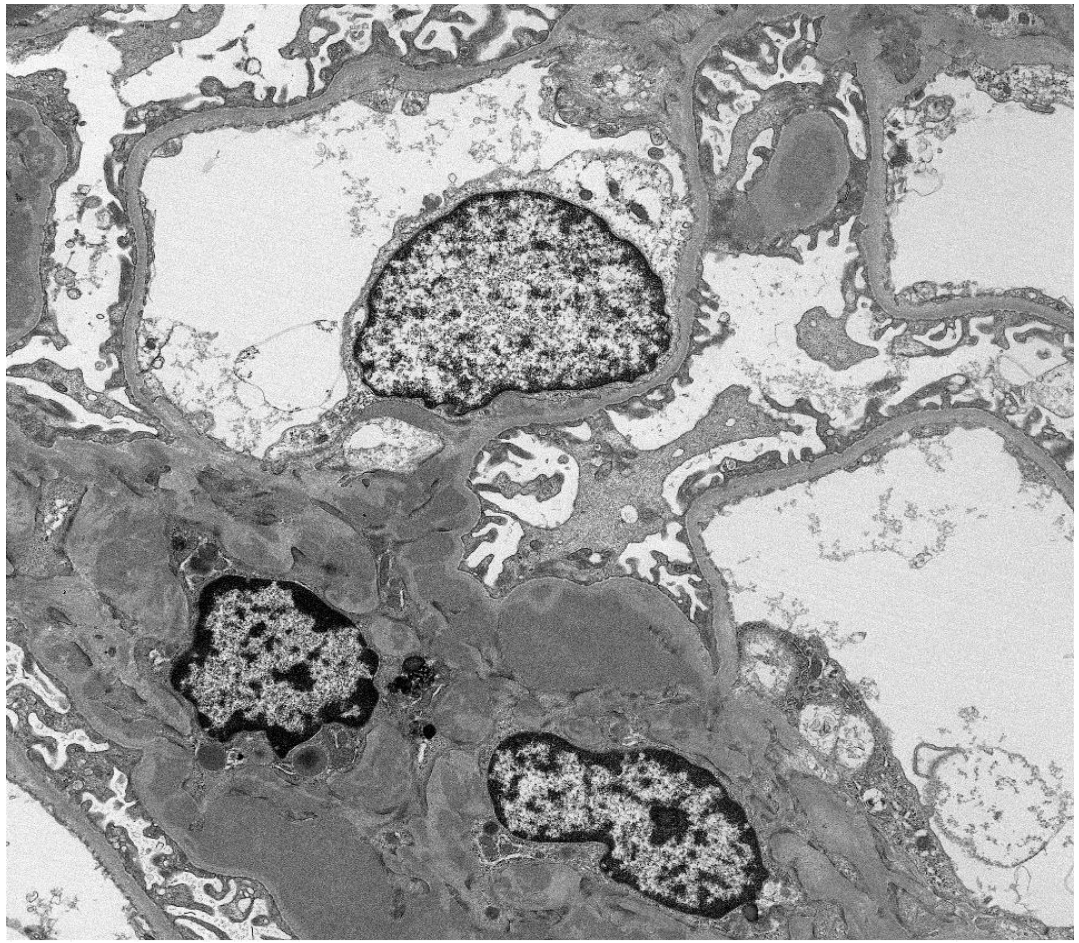

UCSF

DDD vs. C3GN EM

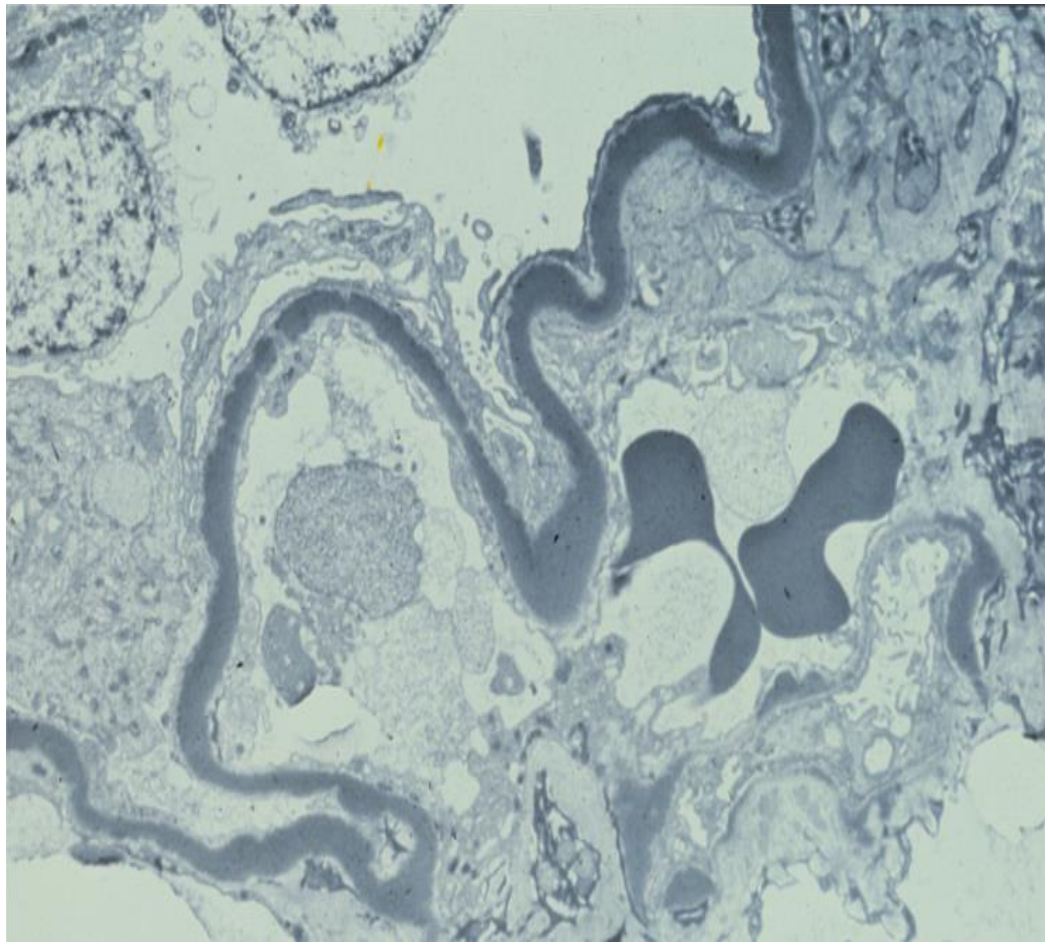

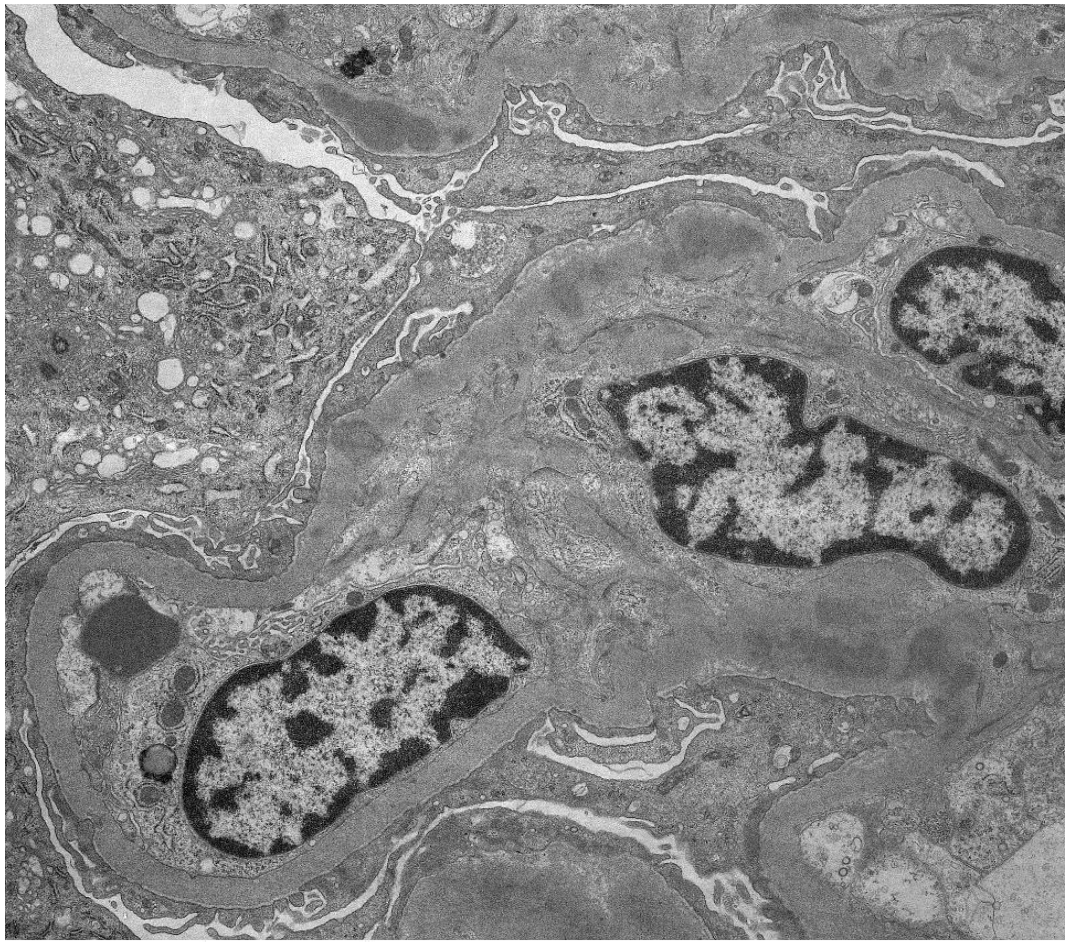

C3GN: Mesangial and subepithelial deposits

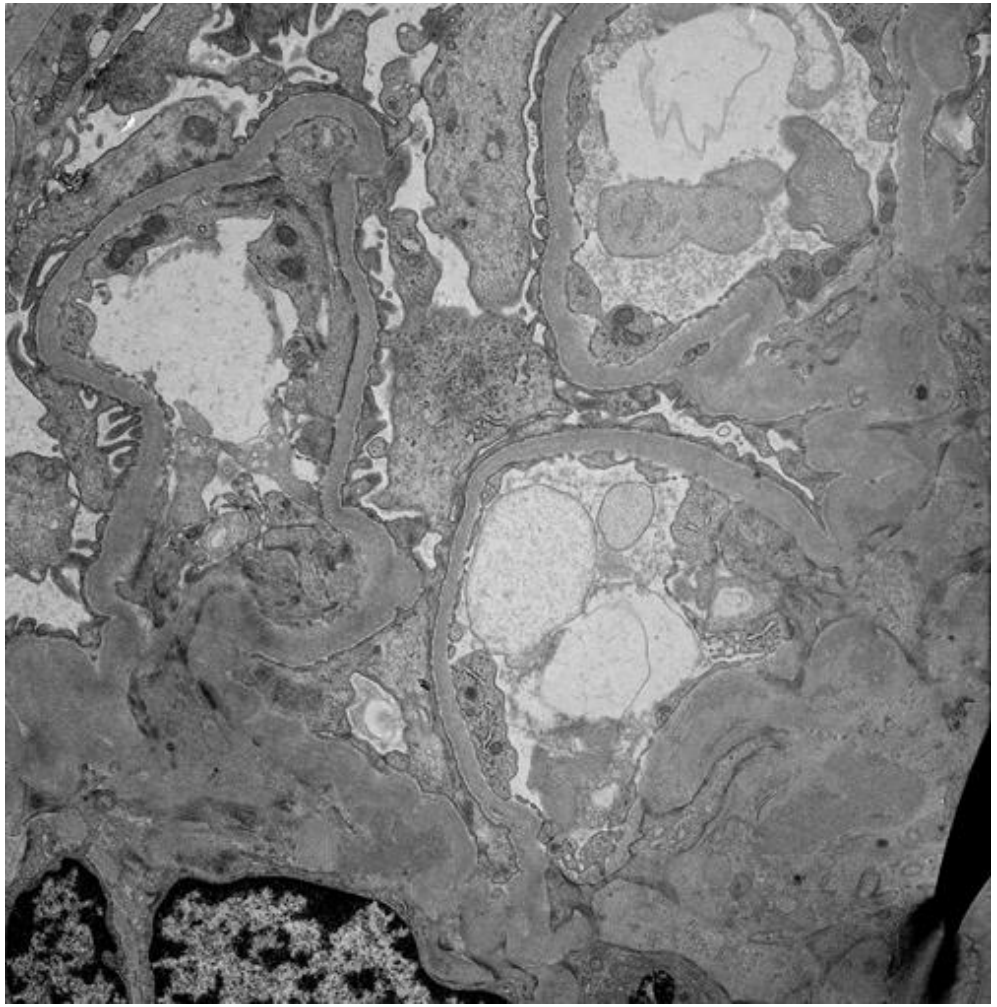

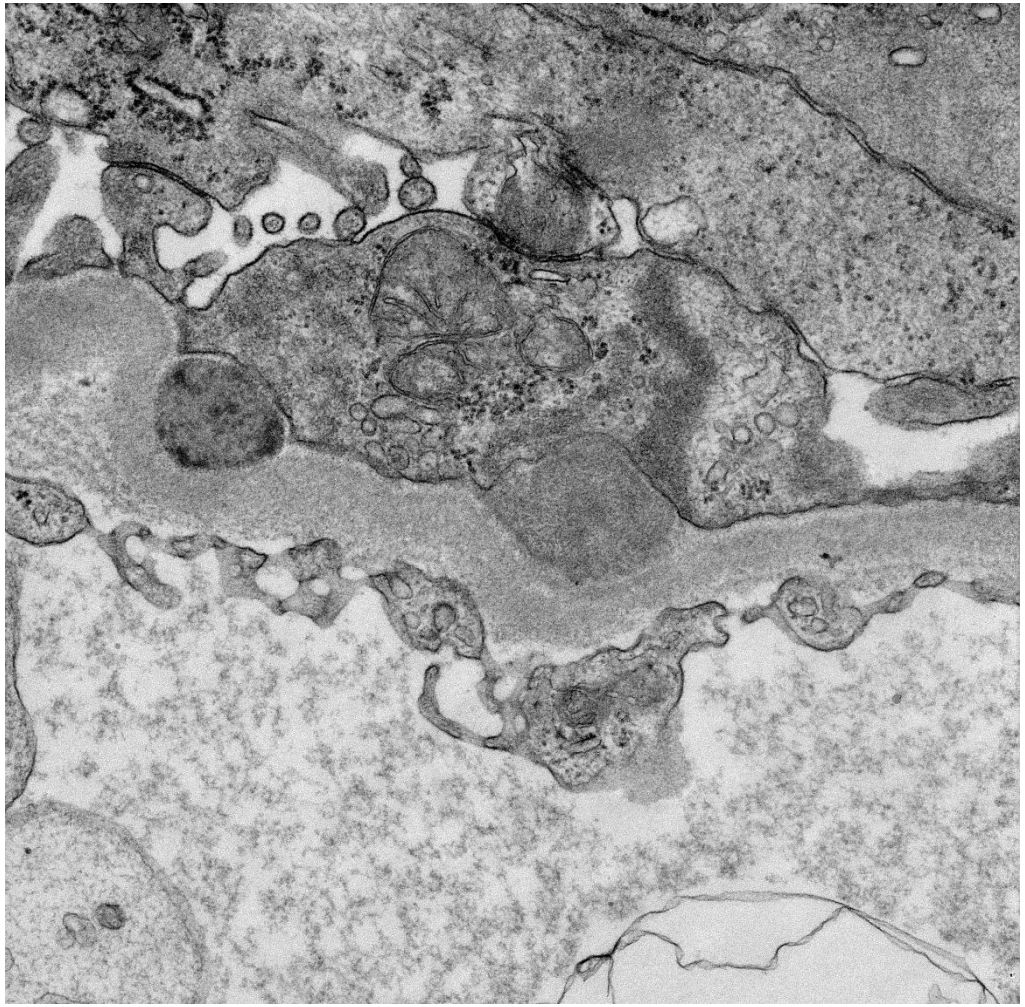

C3 GN with conventional mesangial deposits

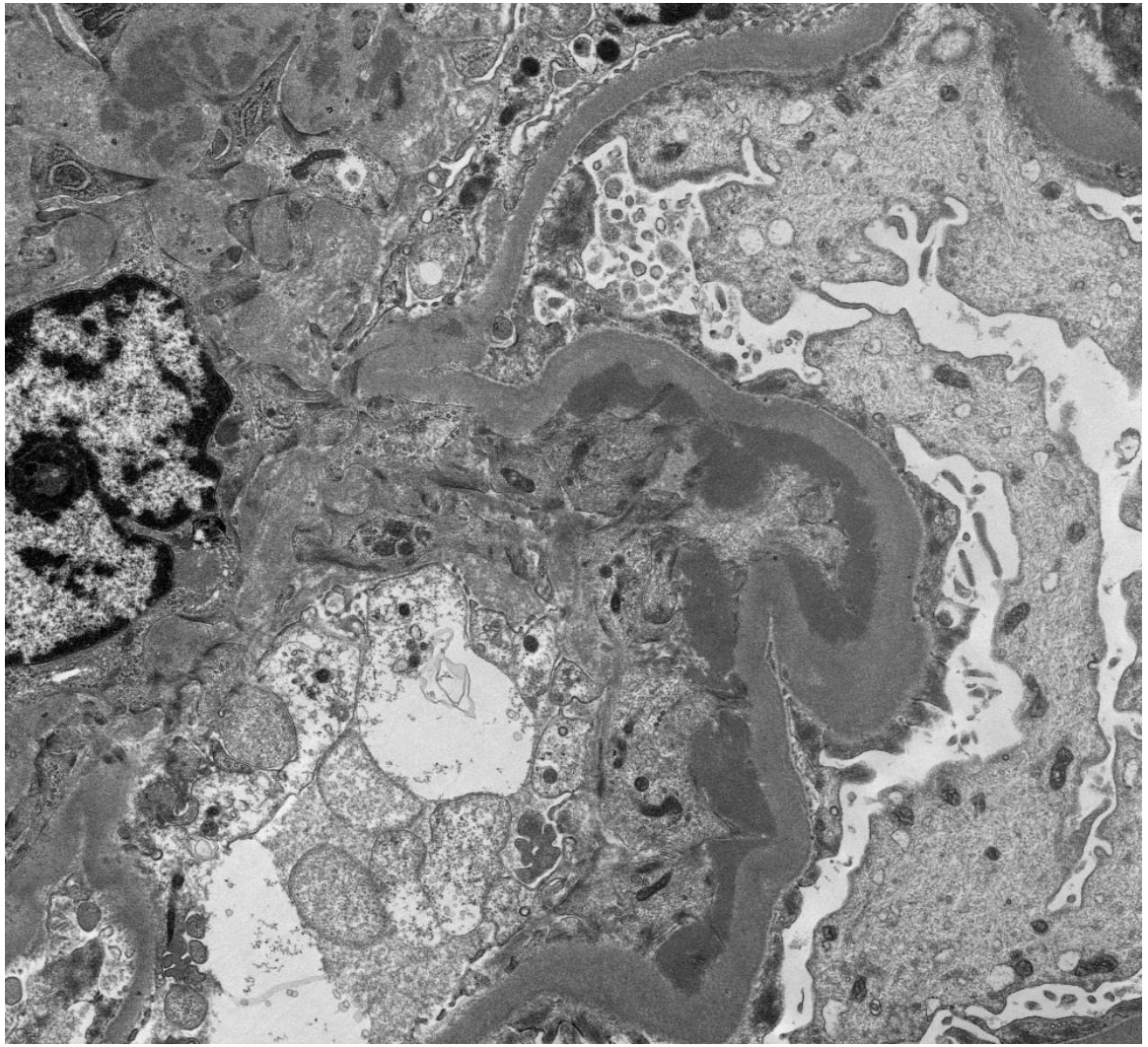

C3 GN with DDD-like mesangial deposits

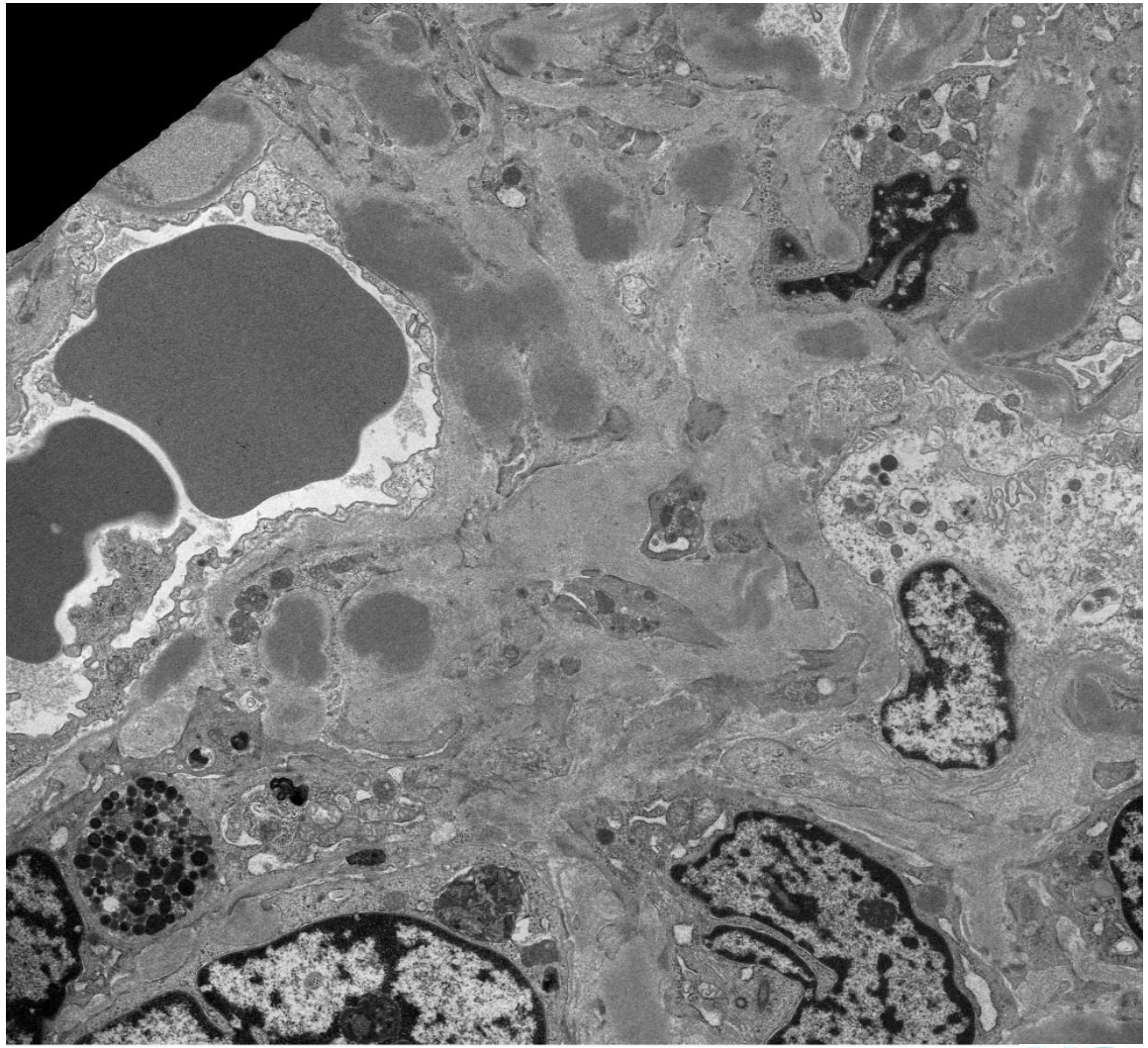

C3 glomerulonephritis and dense deposit disease share a similar disease course in a large United States cohort of patients with C3 glomerulopathy

Bomback, A. S., D. Santoriello, et al. (2018). Kidney Int 93(4): 977-985.

UCSF

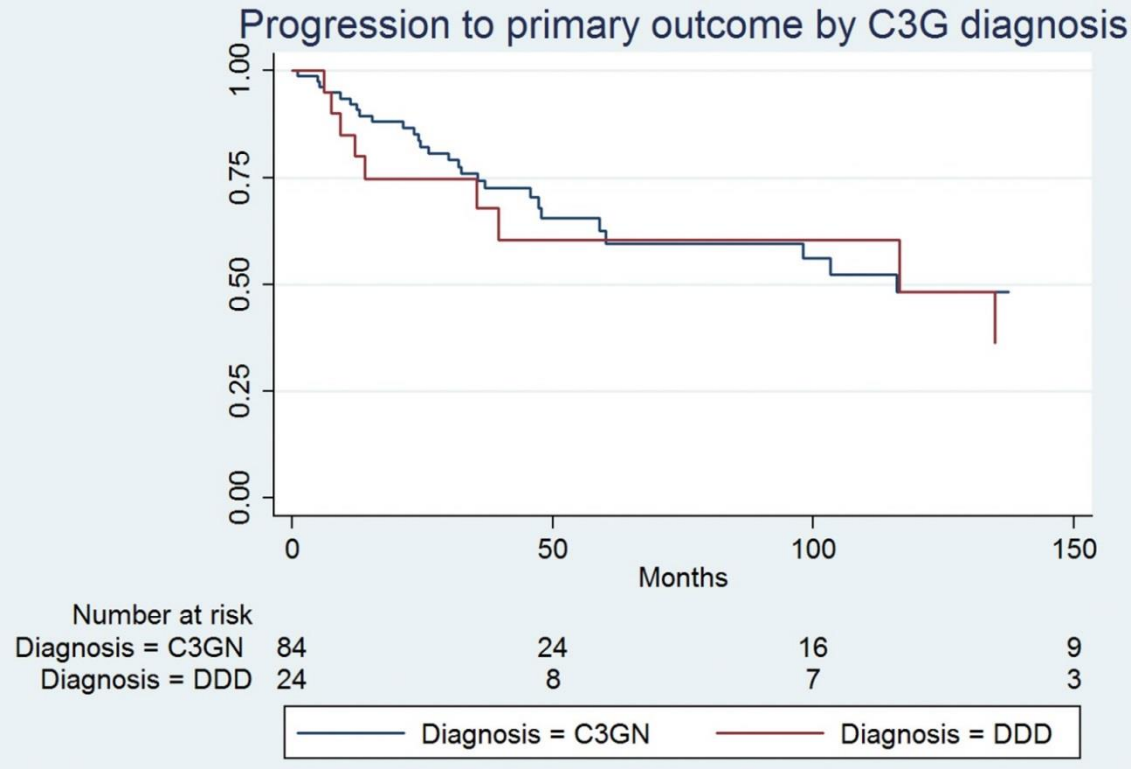

- Over an average of 72 months of follow-up, remission occurred in 38% of patients with C3GN and 25% of patients with dense deposit disease.
- Progression to late-stage CKD and ESRD was common, with no differences between C3GN (39%) and dense deposit disease (42%).

C3 GN vs PIGN

- Differentiation of PIGN from C3 GN often cannot be made on the basis of morphology and clinical and laboratory data available at the time of biopsy
- Clinical and serologic follow up over several months to determine the course of urinary abnormalities and serum C3 levels
- If these parameters do not follow a typical course of PIGN (i.e., normalization of the decreased peripheral C3 level in 8–12 weeks), a diagnosis of C3 GN should be reconsidered and additional investigations performed

Espinosa-Figueroa, J. L., M. Cano-Megias, et al. (2018). Recurrent postinfectious glomerulonephritis: an unus
evolution compatible with C3 glomerulopathy." BMJ Case Rep **2018**.

UCSF

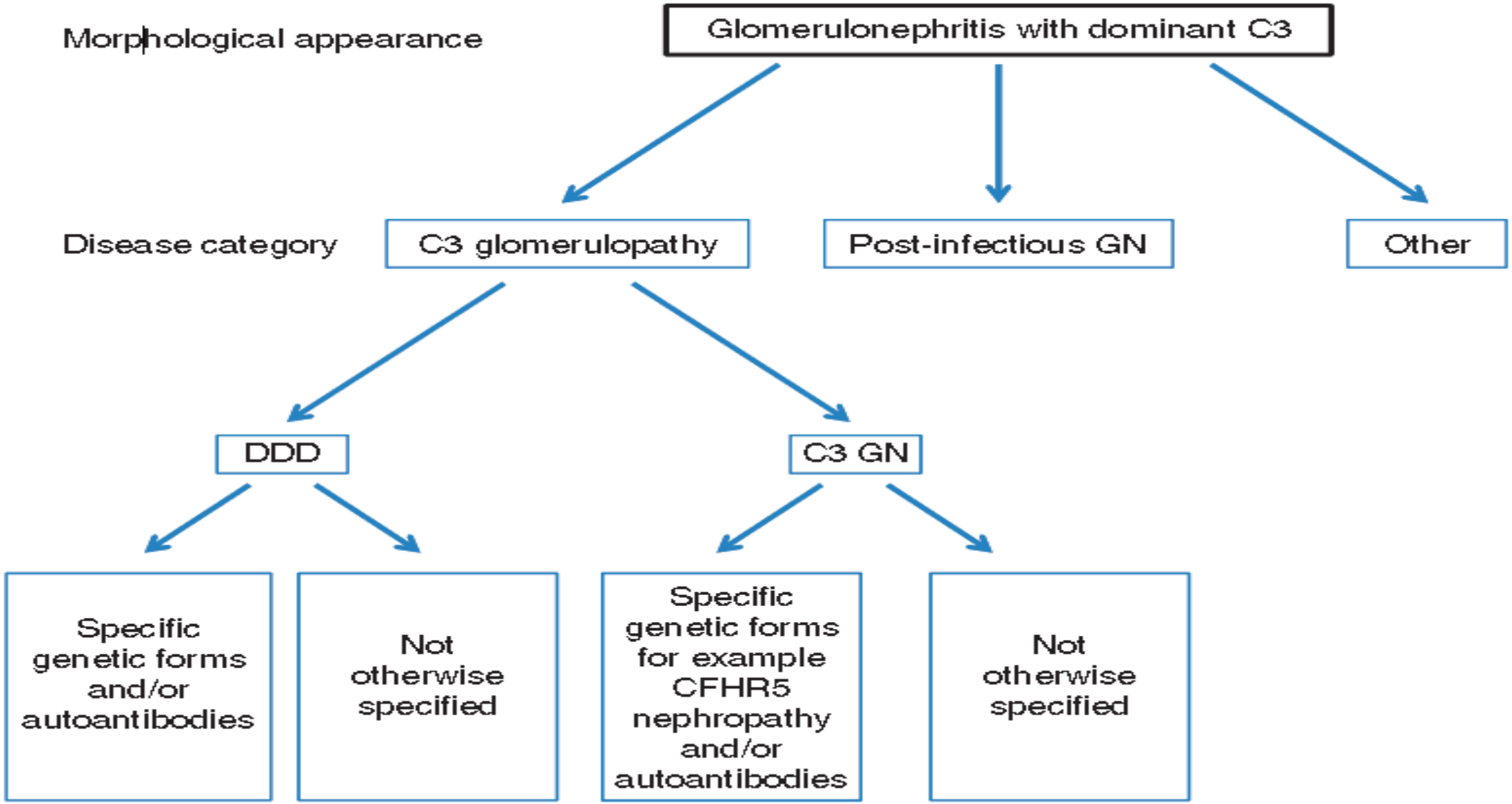
Morphological appearance
Glomerulonephritis with dominant C3
Disease category
C3 glomerulopathy
Post-infectious GN
Other
DDD
C3 GN
Specific genetic forms and/or autoantibodies
Not otherwise specified
Specific genetic forms for example CFHR5 nephropathy and/or autoantibodies
Not otherwise specified

Potential significance/caviats of C3/C5b-9 fragment detection

- Various C3 fragments (C3b, C3c, C3dg) can mediate distinct biological responses through their interactions with complement receptors
- Glomerular and tubular BM deposits of C5b-9 may persist in repeat renal biopsies of C3 GN and DDD 1 year after initiation of Eculizumab therapy despite the normalization of serum C5b-9 levels
- C5b-9 may be present in glomeruli of normal kidneys

UCSF

Case Challenge

- The patient is a 41-year-old woman with a history of systemic plasmacytosis (On prednisone last year for five months)
- Creatinine 1.3
- Has low grade proteinuria (~1gr/24h) and no hematuria

UCSF

Audience Response

What would you do next?

A. Do nothing
B. Do a kidney biopsy
C. I'm not sure

UCSF

Biopsy findings: C3 GN, mesangial variant

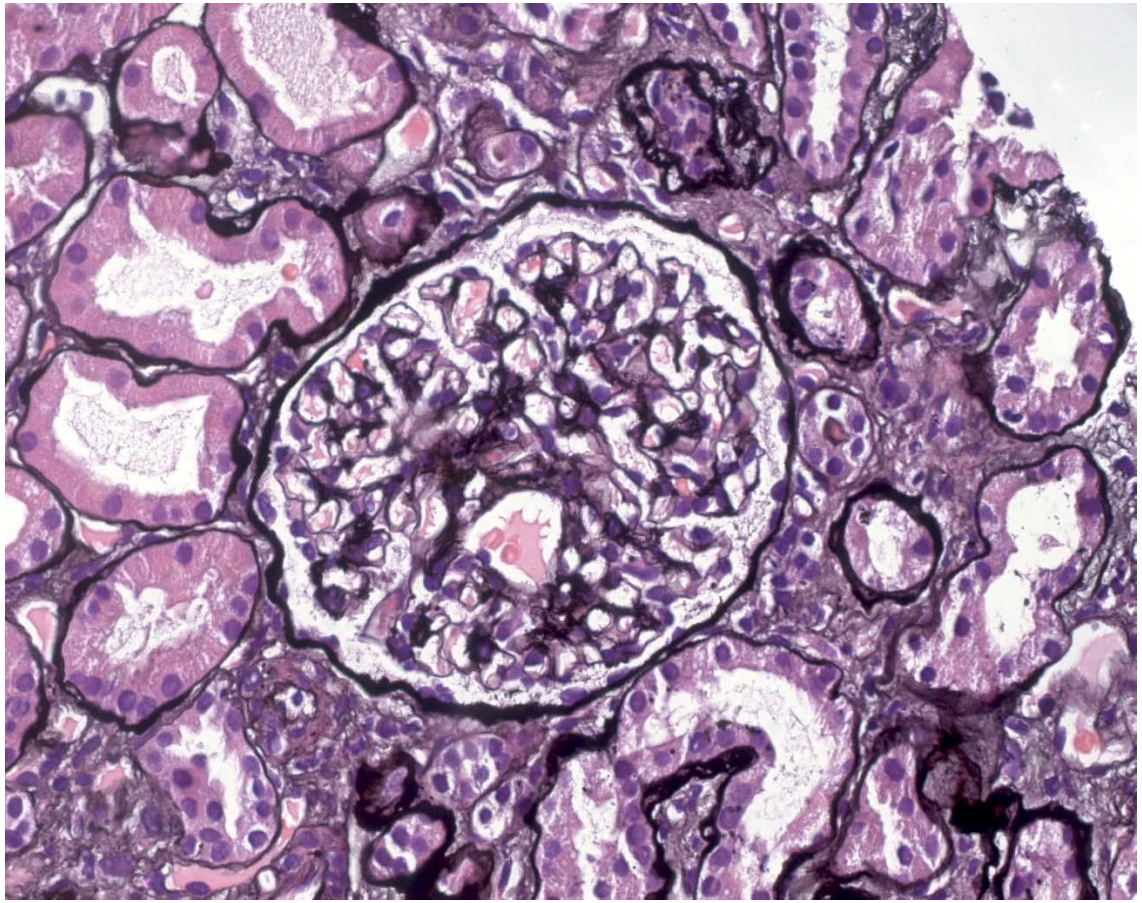

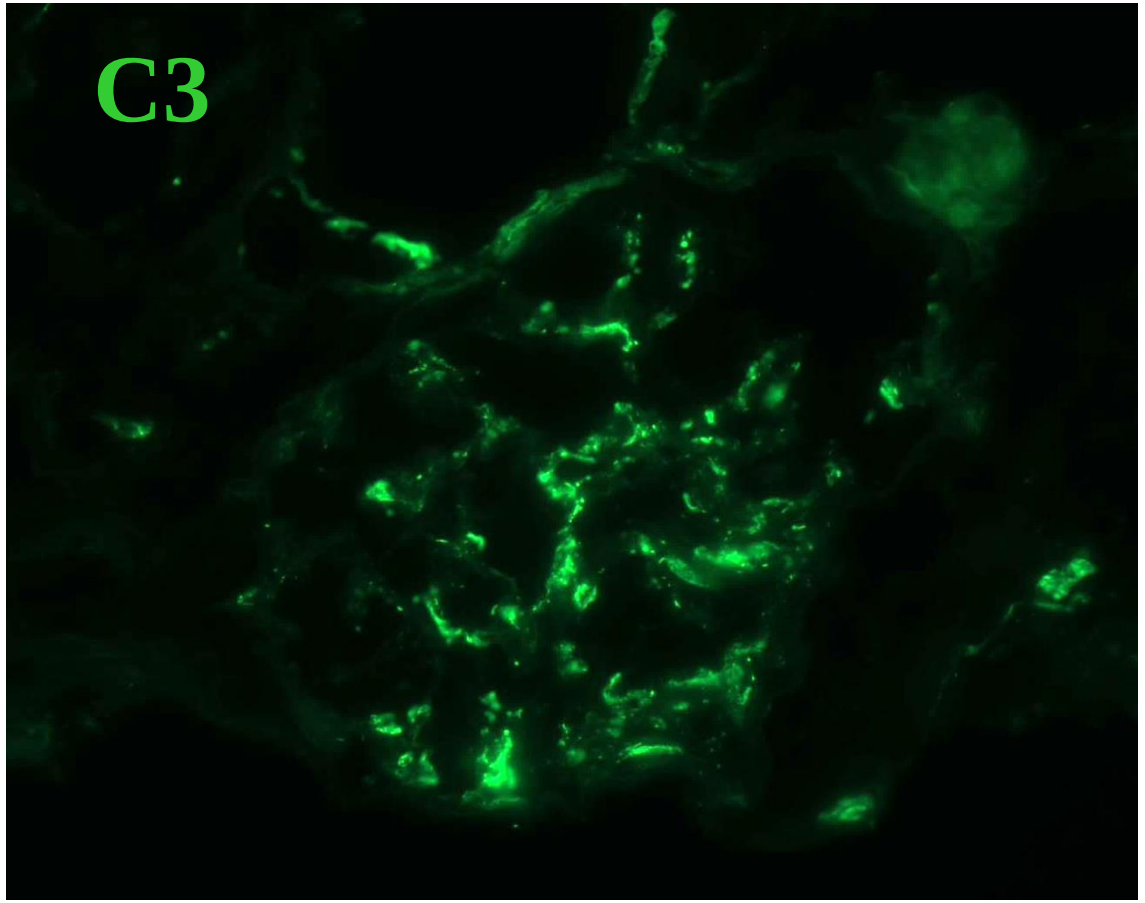

C3 GN, mesangial variant

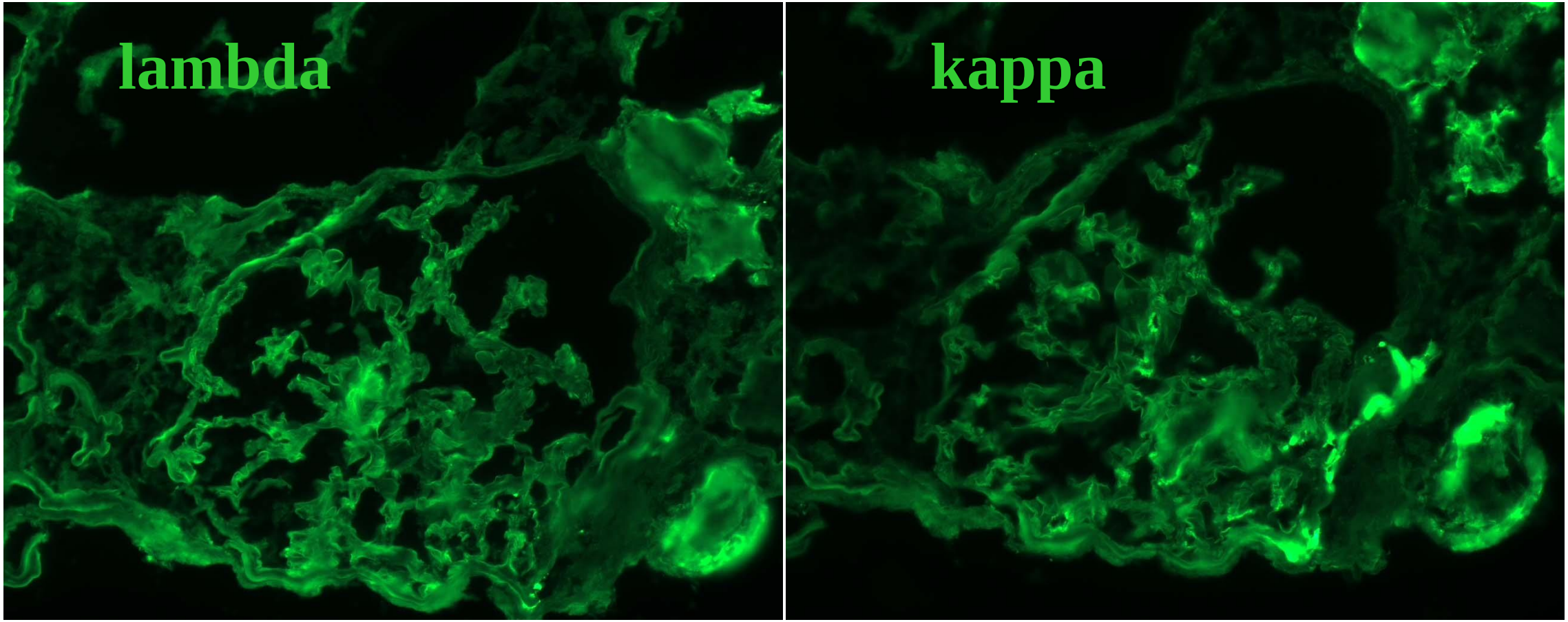

Mesangial and subepithelial deposits

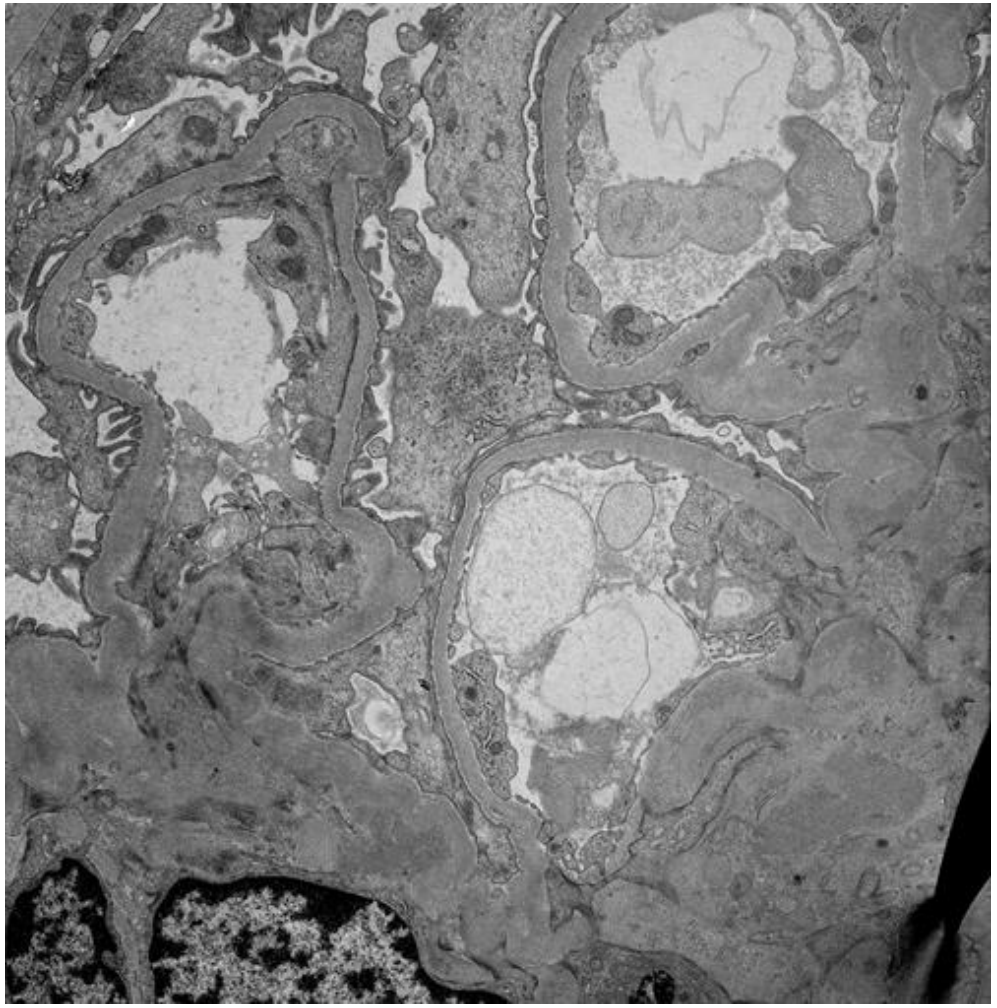

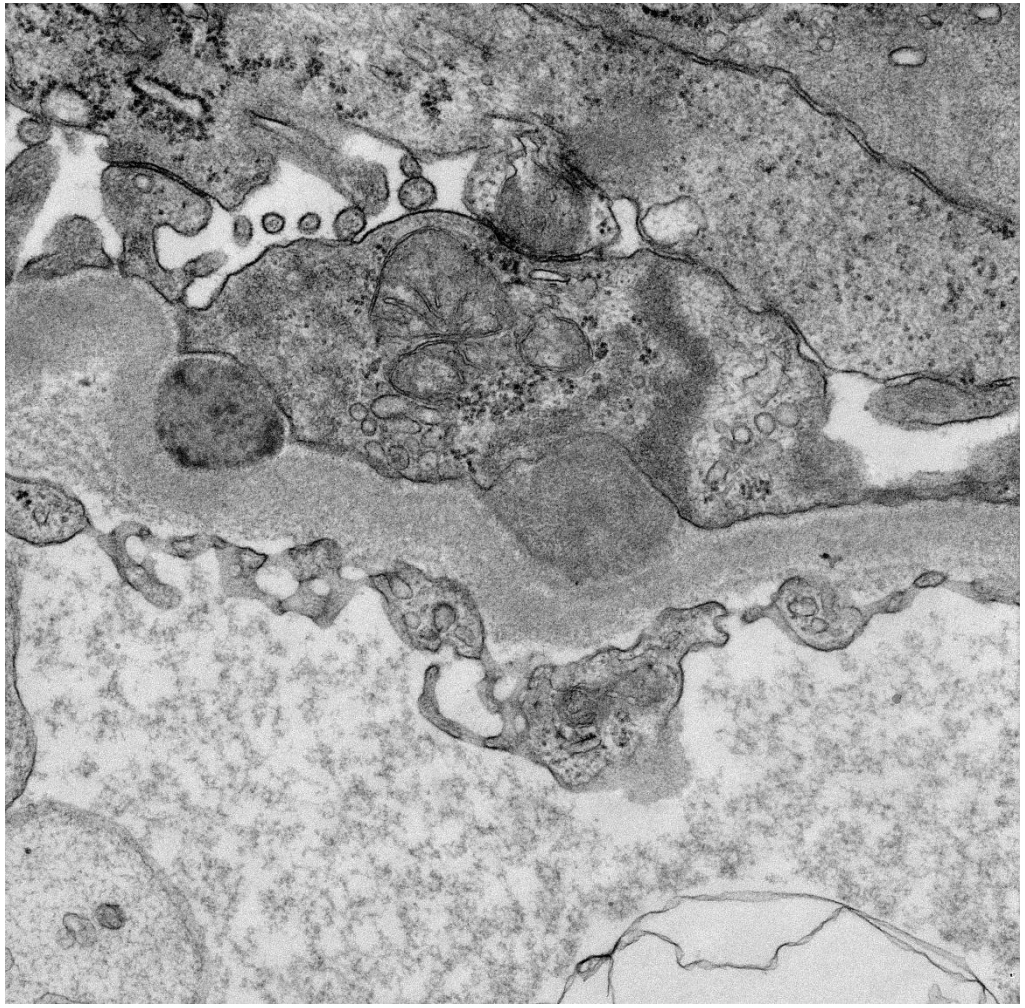

C3 GN: Morphologic manifestations

- Mild mesangial proliferative GN
- MPGN
- Crescentic GN

UCSF

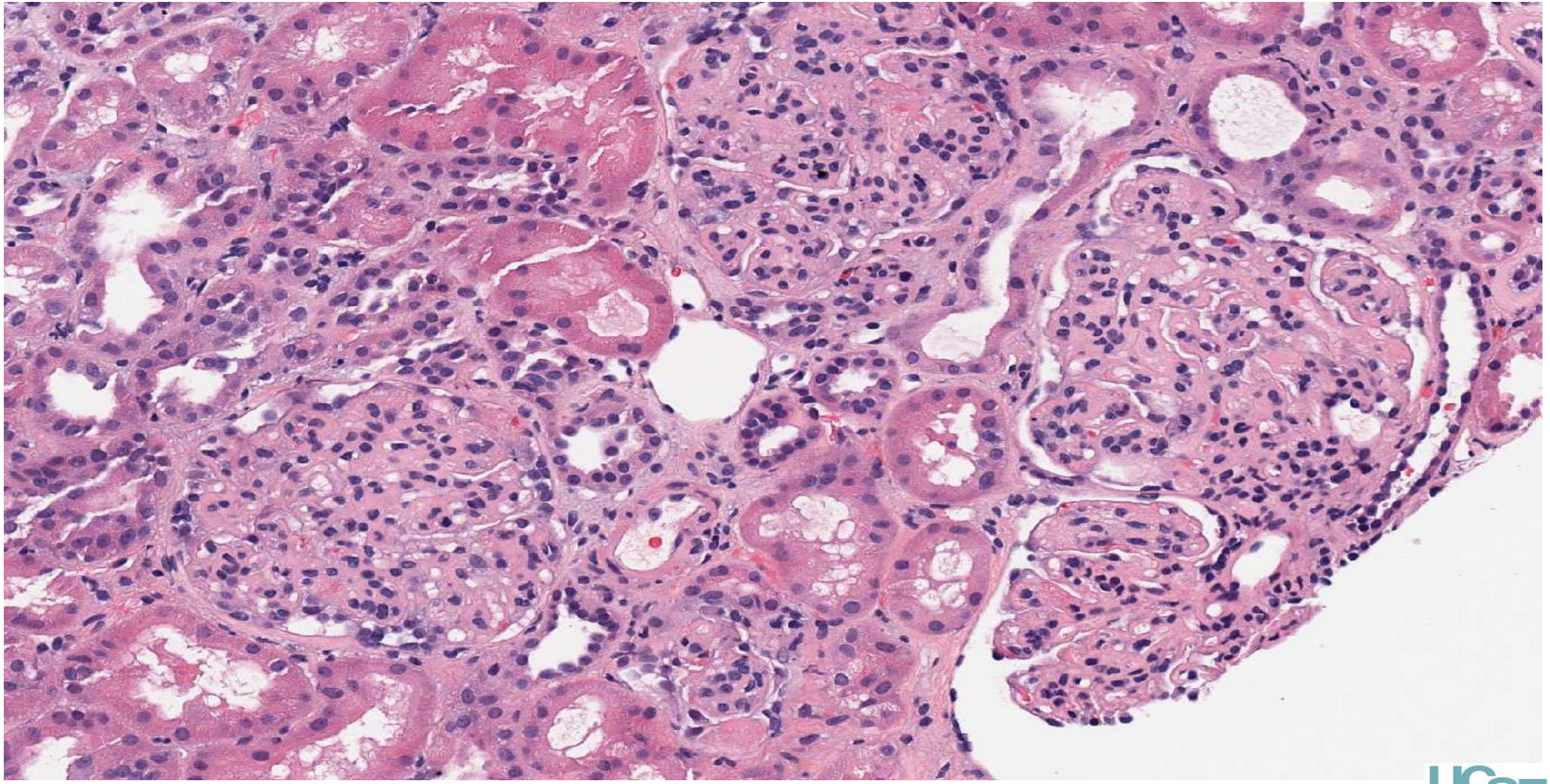
UCSF

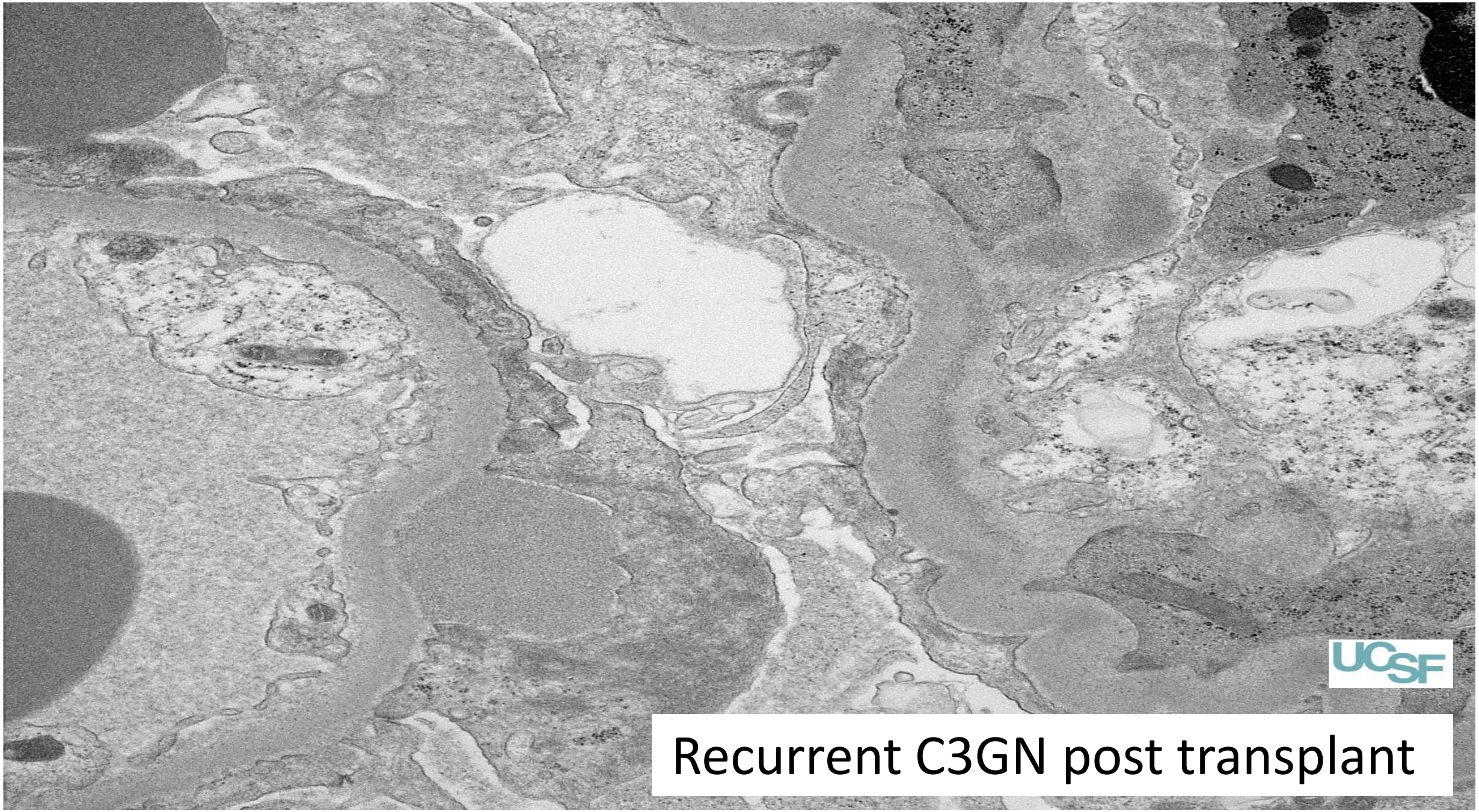

Recurrent C3GN post transplant

CFHR5 nephropathy (Familial C3GN)

- Caused heterozygous internal duplication of the CFHR5 gene in Cypriot families (autosomal dominant)
- Mesangioproliferative or MPGN pattern GN
- Subendothelial and mesangial deposits with occasional subepithelial deposits by EM
- Microscopic haematuria and episodes of synpharyngitic macroscopic haematuria (~50%)
- Serum C3 levels almost invariably normal
- Progression to ESKD common in adults (mostly in males)
- Ten patients with successful transplantation and one other with disease recurrence

Gale DP et al. Lancet 2010; 376: 794–801

Gale DP et al. Dis Model Mech 2011; 4: 721–726

UCSF

Treatment

- BP control and antiproteinuric therapy (ACE inhibitors)
- Steroids, other immunosuppressants
- Long-term plasma infusion
- Administration of CFH (if it becomes available)
- Therapeutic inhibition of complement C3 or C5
  - successful and unsuccessful treatment with Eculizumab in both C3GN and DDD

UCSF

C3 glomerulonephritis secondary to mutations in factors H and I: rapid recurrence in deceased donor kidney transplant effectively treated with eculizumab.

Garg, N., Y. Zhang, et al. (2018).

Nephrol Dial Transplant.

UCSF

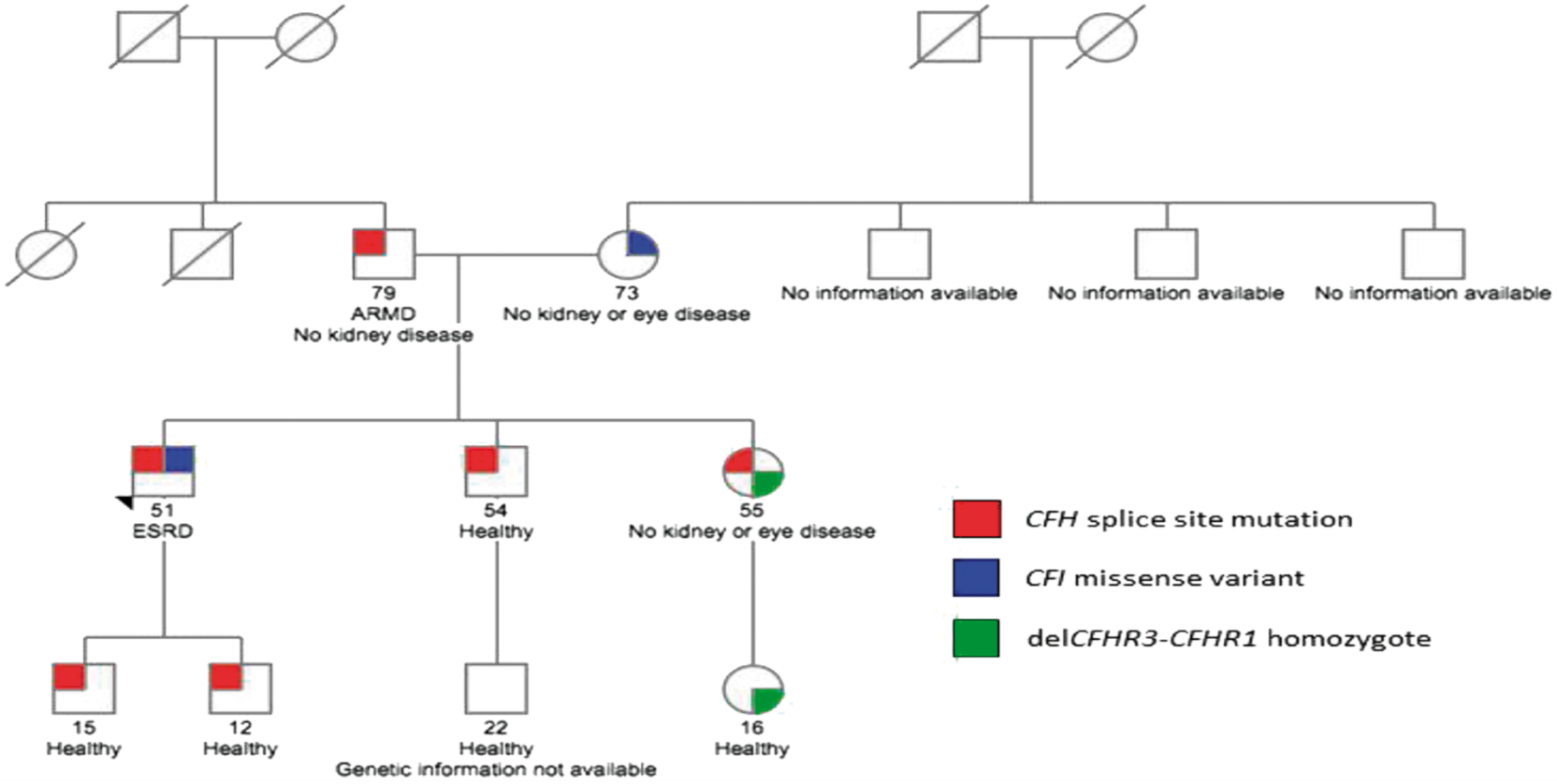

From: C3 glomerulonephritis secondary to mutations in factors H and I: rapid recurrence in deceased donor kidney transplant effectively treated with eculizumab

Nephrol Dial Transplant. Published online January 23, 2018. doi:10.1093/ndt/gfx369

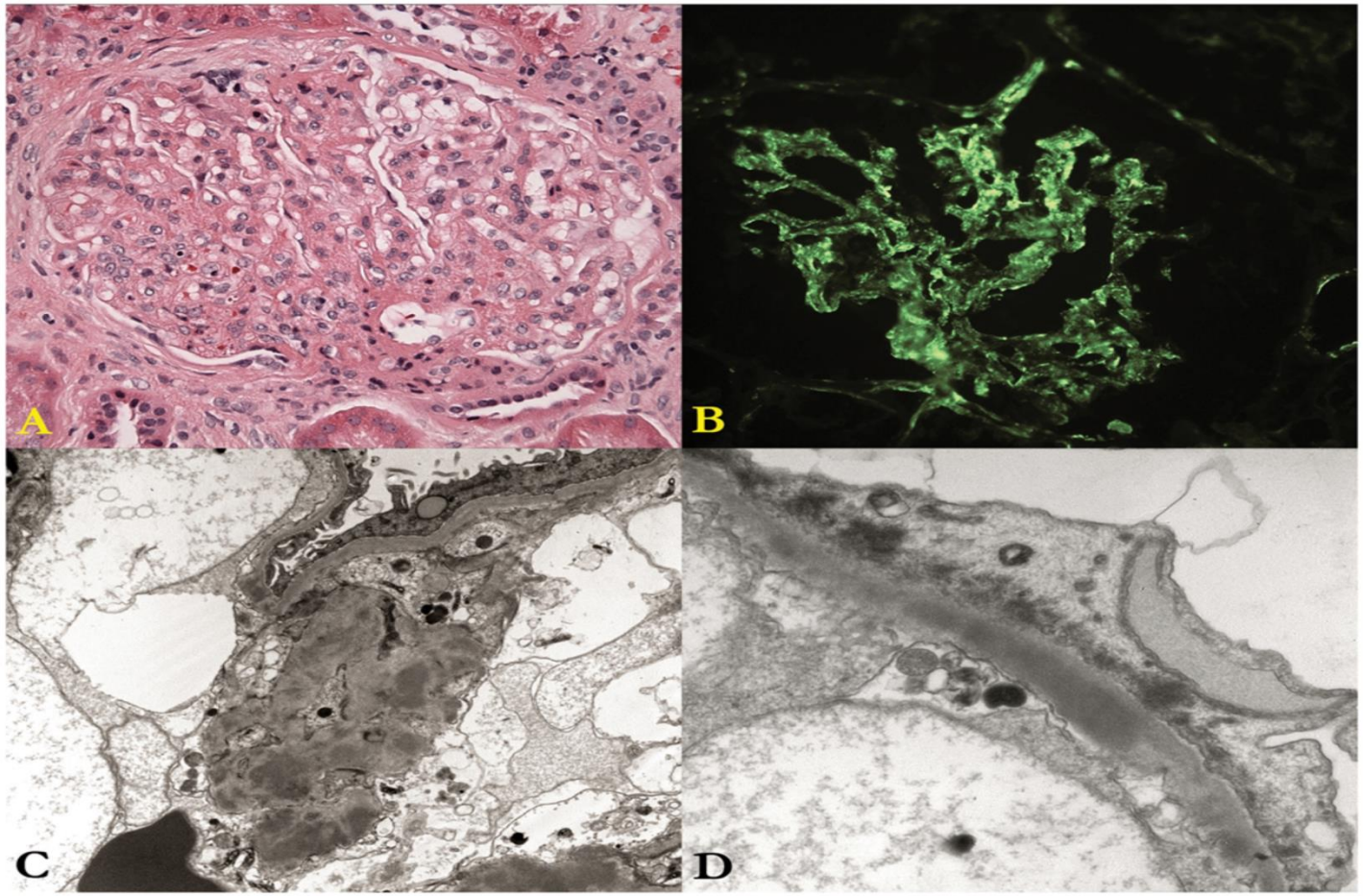

From: C3 glomerulonephritis secondary to mutations in factors H and I: rapid recurrence in deceased donor kidney transplant effectively treated with eculizumab

Nephrol Dial Transplant. Published online January 23, 2018. doi:10.1093/ndt/gfx369

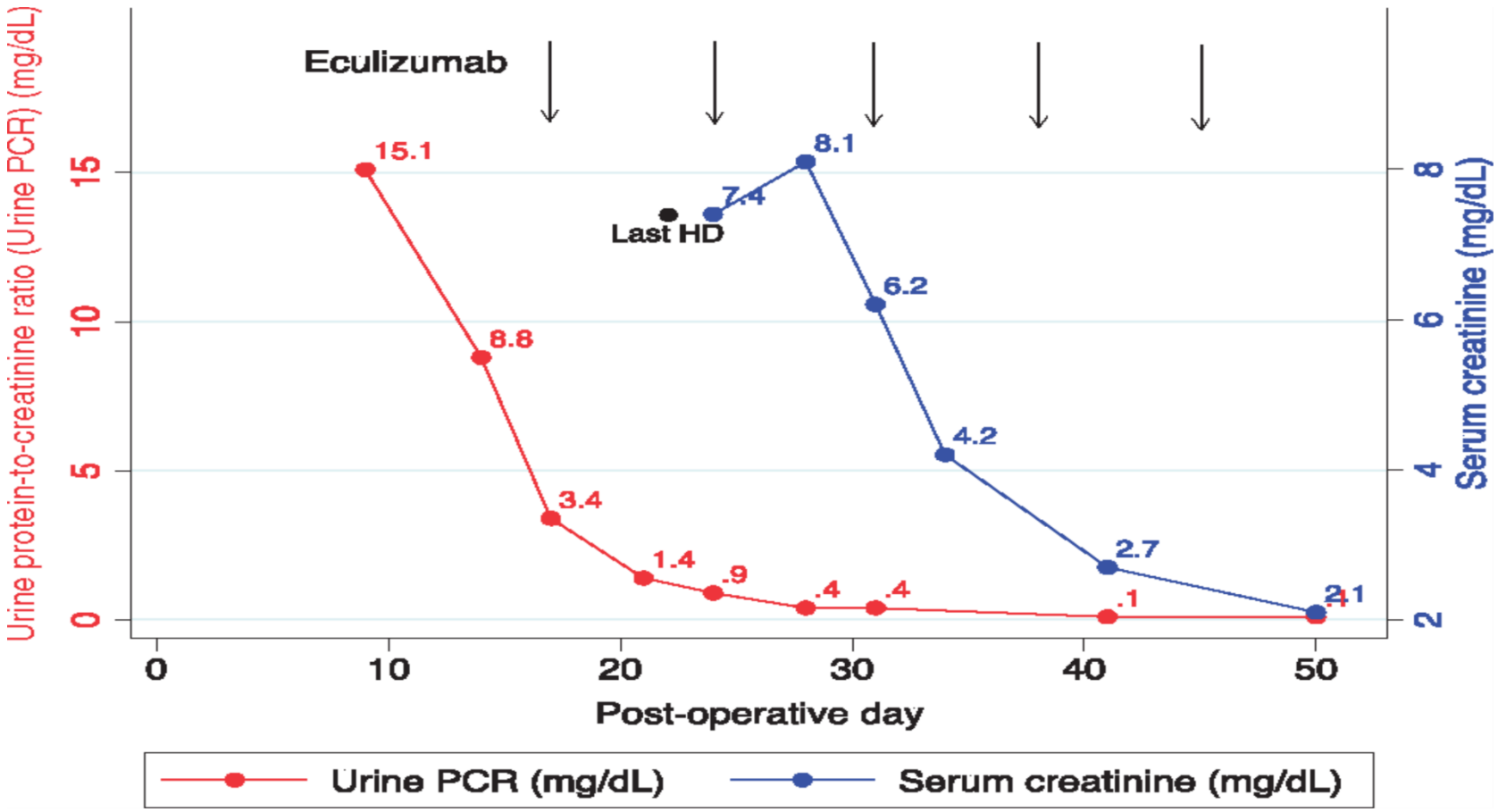

From: C3 glomerulonephritis secondary to mutations in factors H and I: rapid recurrence in deceased donor kidney transplant effectively treated with eculizumab

Nephrol Dial Transplant. Published online January 23, 2018. doi:10.1093/ndt/gfx369

Recurrent allograft C3 glomerulonephritis and unsuccessful eculizumab treatment

Kaartinen K et al. 2018. Clin Immunol 187: 104-106.

- C3Nef positive with C3 activation only
- Analyzing C3Nef-mediated C3 and C5 activation separately could help in choosing the right patients for eculizumab therapy

UCSF

Thank you!

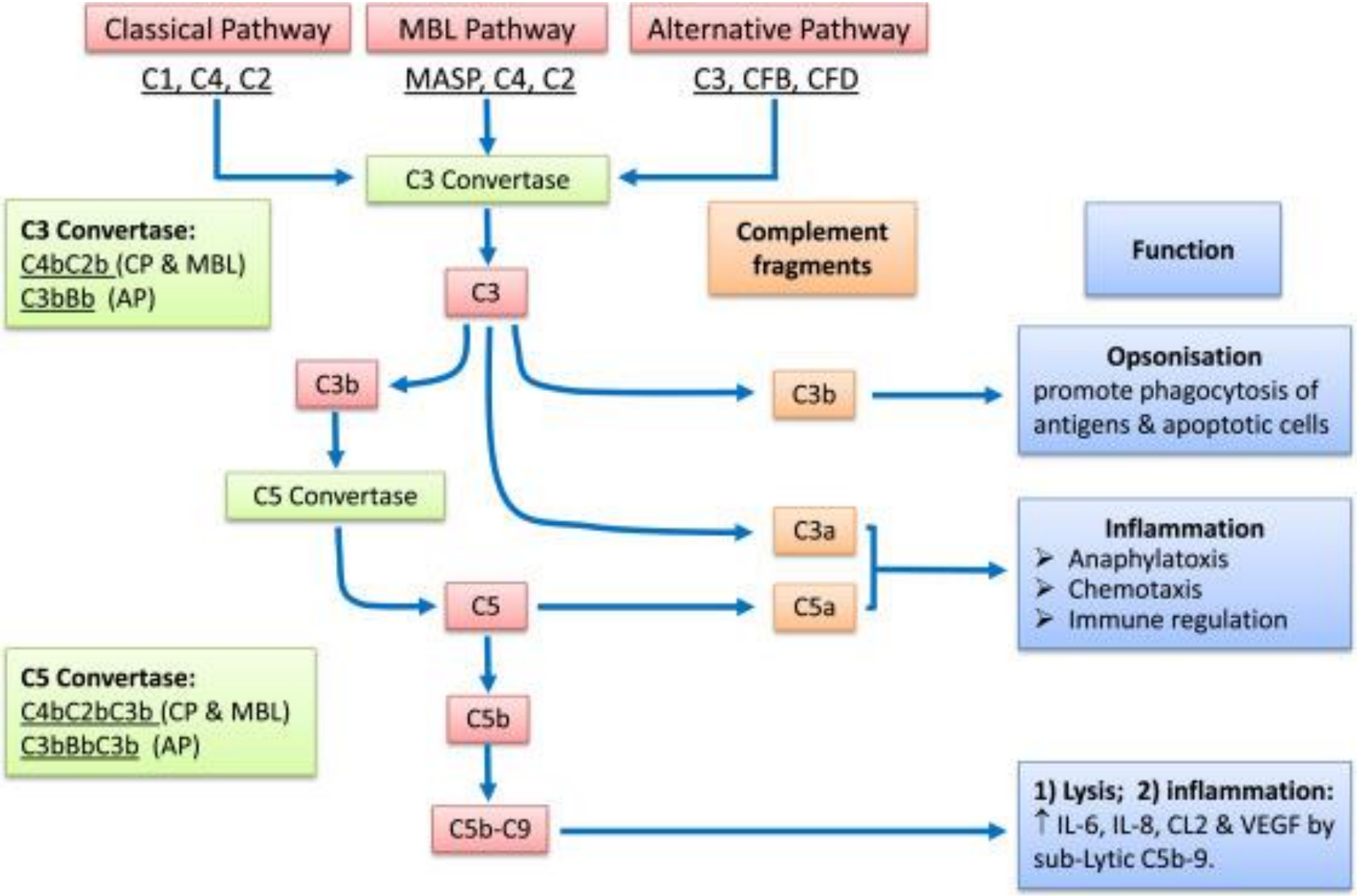
Classical Pathway
C1, C4, C2
MBL Pathway
MASP, C4, C2
Alternative Pathway
C3, CFB, CFD
C3 Convertase
C3 Convertase:
C4bC2b (CP & MBL)
C3bBb (AP)
Complement fragments
Function
C3
C3b
C3b
Opsonisation
promote phagocytosis of antigens & apoptotic cells
C5 Convertase
C3a
C5a
Inflammation
Anaphylatoxis
Chemotaxis
Immune regulation
C5
C5 Convertase:
C4bC2bC3b (CP & MBL)
C3bBbC3b (AP)
C5b
C5b-C9
1) Lysis; 2) inflammation:
↑ IL-6, IL-8, CL2 & VEGF by sub-Lytic C5b-9.