Pathology of Kidney Allograft Dysfunction

B. Ivanyi, MD
Department of Pathology,
University of Szeged, Szeged, Hungary

The renal biopsy is a powerful tool in the diagnostic evaluation of allograft dysfunction

Evaluation procedure

Standard

- At least two cores whenever possible
- Light microscopic stainings on serial sections (H&E, PAS, trichrome, methenamine silver)
- Immunostaining for complement 4d - ***indicator of antibody-mediated rejection***

Optional

- **LM**: elastin staining - ***chronic rejection-induced intimal fibrosis***
- **IF**: IgG, IgA, IgM, C3, C1q - ***GN***
  tubular HLA-DR expression - ***acute T-cell-mediated rejection***
- **EM** - ***chronic rejection, GN***
- Implantation biopsy for comparison

Objective

To review

- the pathology of rejection, CNI toxicity, polyomavirus nephropathy, and post-transplantation glomerulonephritis
- factors leading to end-stage kidney allograft disease

Solez et al. Banff 07 Classification of Renal Allograft Pathology. AJT 8:753, 2008

Rejection

Inflammatory response initiated by alloantigen recognition

Acute
T-cell mediated
Alloantibody mediated

Chronic
Alloantibody mediated
T-cell mediated

Acute T-cell-mediated rejection

Inflammatory response against HLA class II antigens expressed on

- peritubular and glomerular capillary endothelial cells
- tubular epithelial cells
- interstitial dendritic cells
- mesangial cells

Acute T-cell-mediated rejection

Inflammatory response against HLA class II antigens expressed on

- peritubular and glomerular capillary endothelial cells
- tubular epithelial cells
- interstitial dendritic cells
- mesangial cells

Effector mechanisms

$CD8^+$ CTL-mediated cytotoxicity	+++
Delayed type hypersensitivity	+
Antibody-dependent cytotoxicity	+

Acute T-cell-mediated rejection

Peritubular capillaries
Interstitium
Tubules
Tubulointerstitial rejection

± Arteries
Vascular rejection

± Glomeruli
Transplant glomerulitis

Tubulointerstitial rejection

Peritubular capillaritis: accumulation of lymphocytes ± monocytes

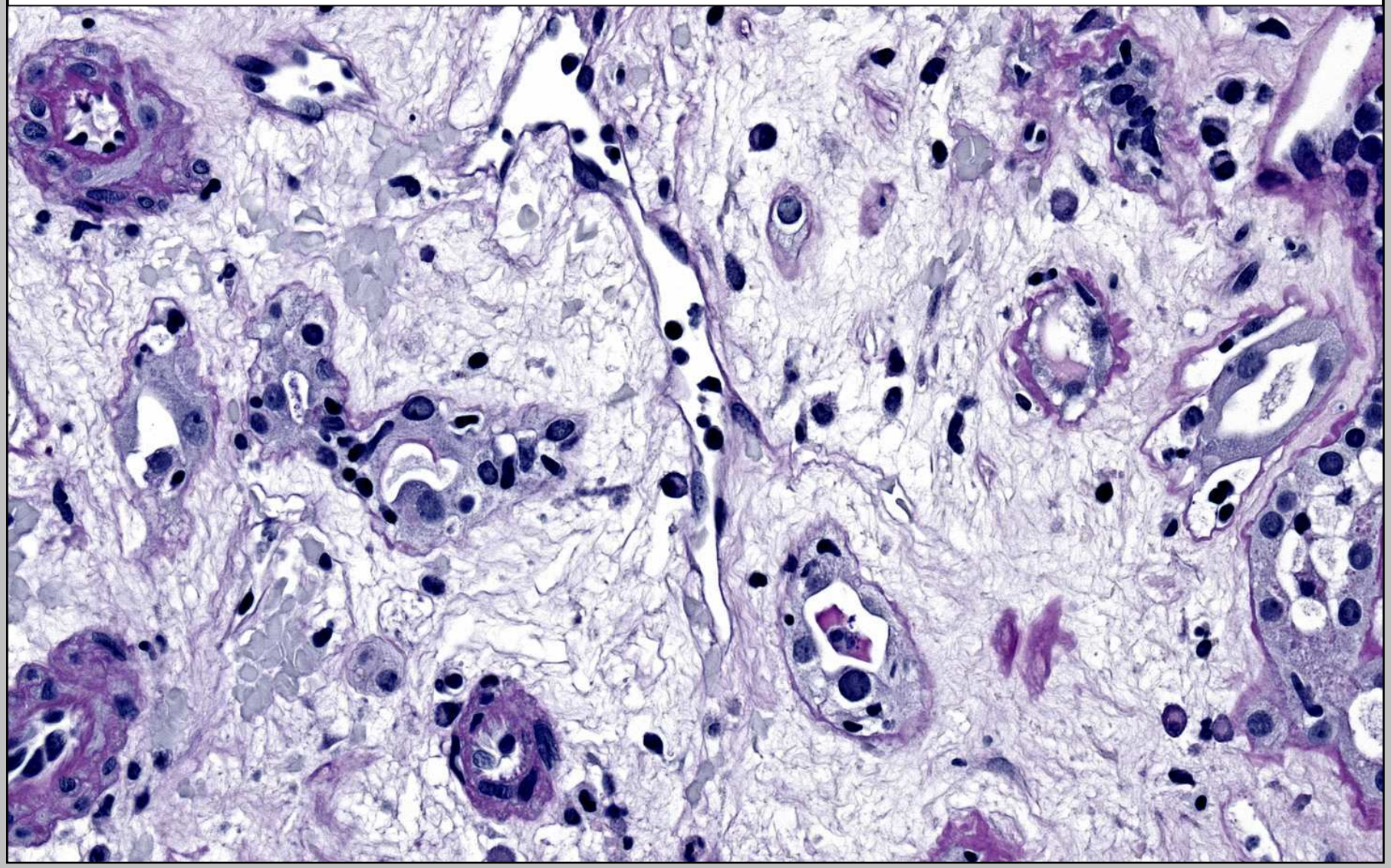

Peritubular capillaritis on EM

Hypertrophy of endothelial cells, accumulation and emigration of ly-s into the interstitium; CTL-mediated lysis

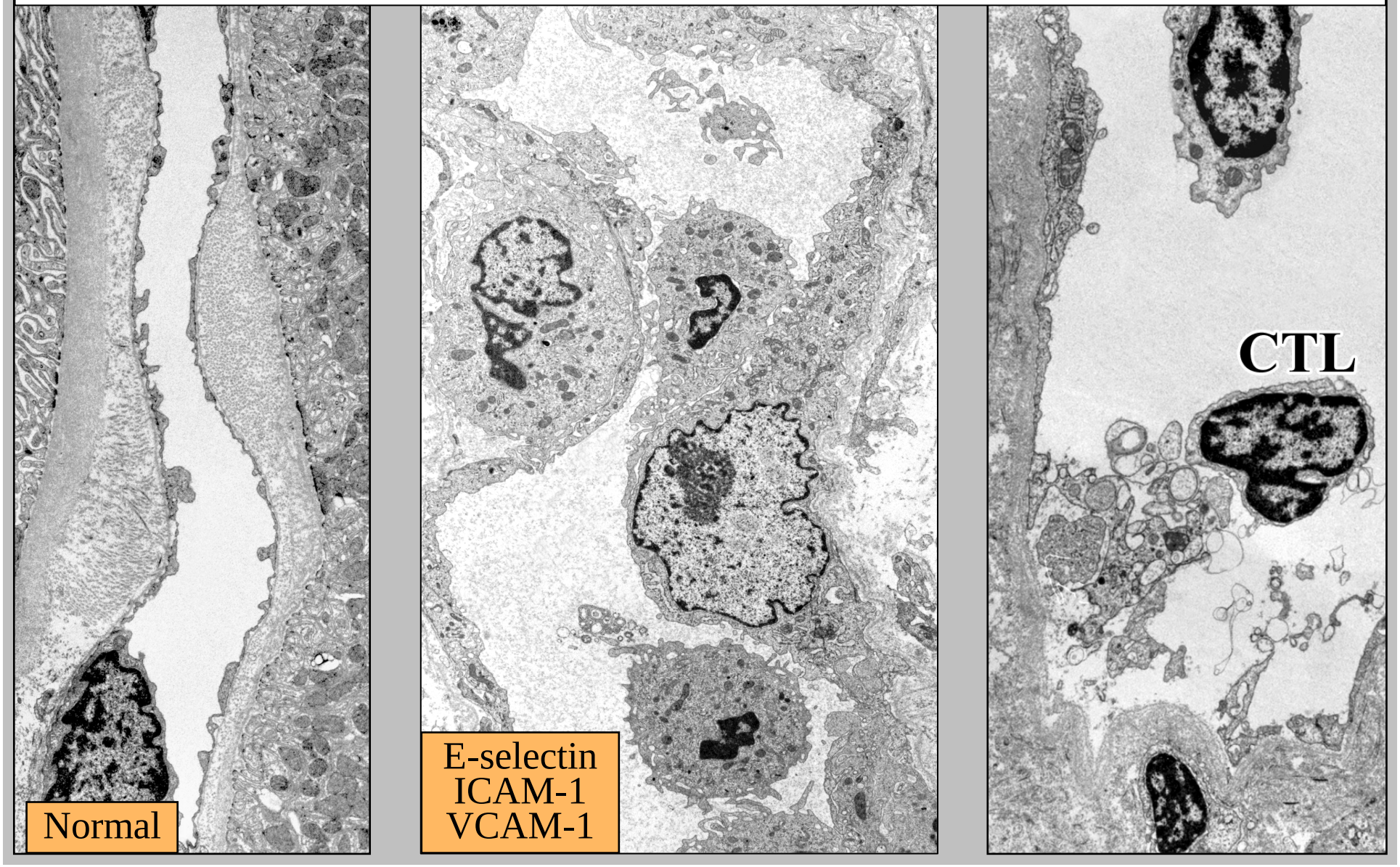

Tubulointerstitial rejection

Interstitial infiltrates rich in CTLs, oedema, tubular HLA-DR expression, and ***tubulitis***

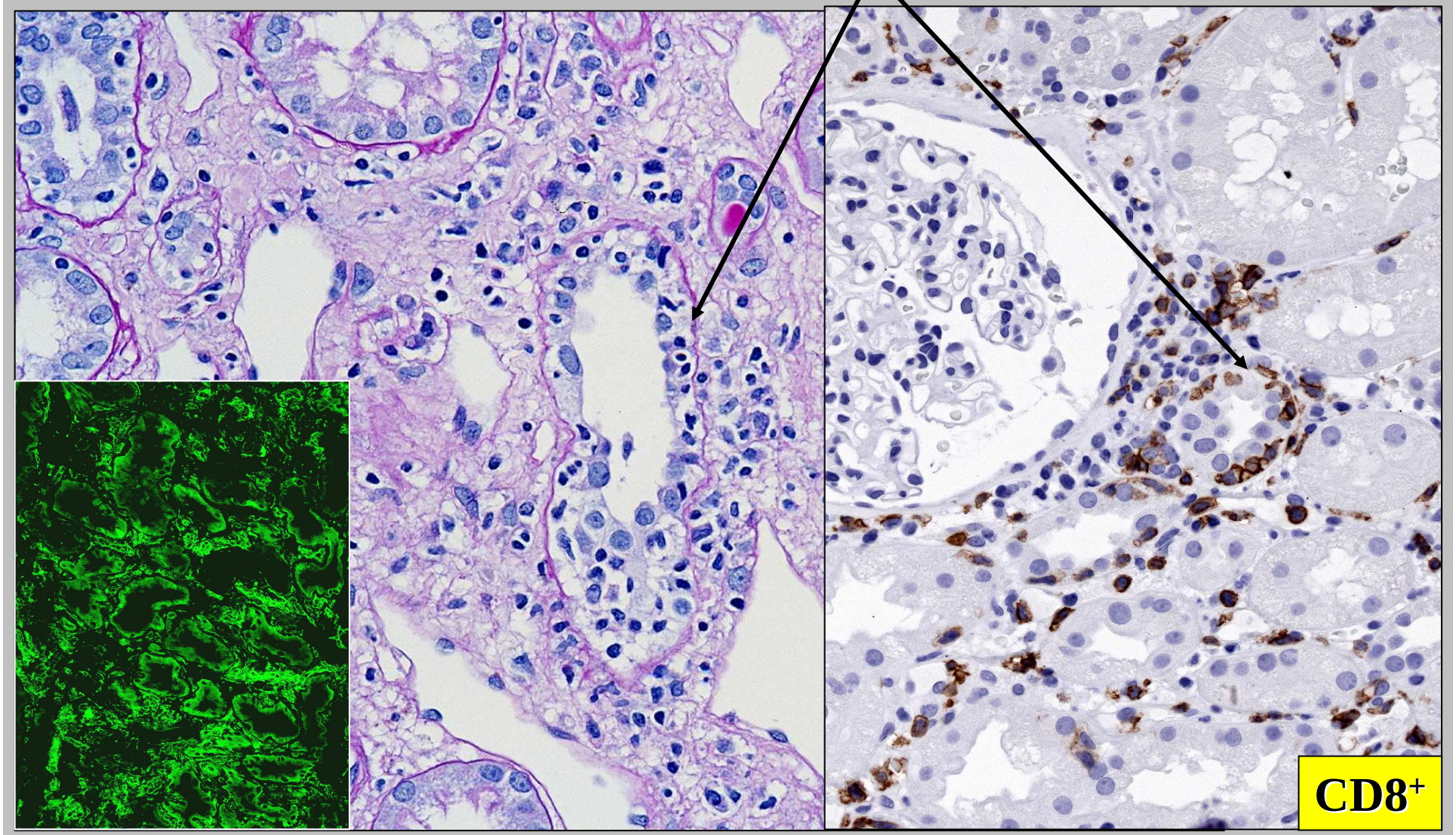

Tubulitis: tubular expression of chemokines induce CTLs to invade the tubules; CTLs injure tubular epithelial cells

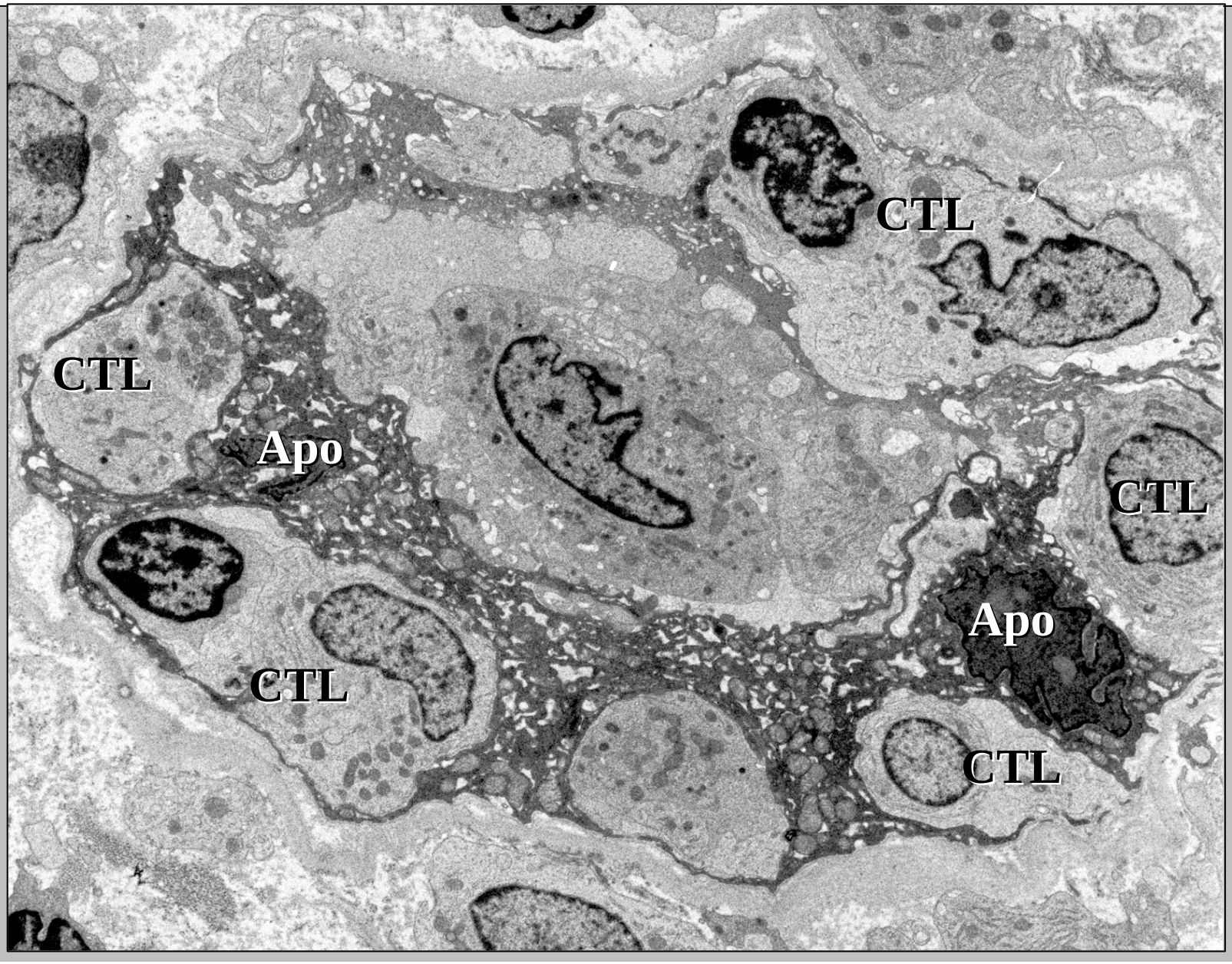

Subsiding tubulointerstitial rejection:

nodular infiltrates around newly formed lymphatic vessels; Tregs, $CD4^{+}$, $CD8^{+}$, $CD68^{+}$; scanty tubulitis; oedema Ø

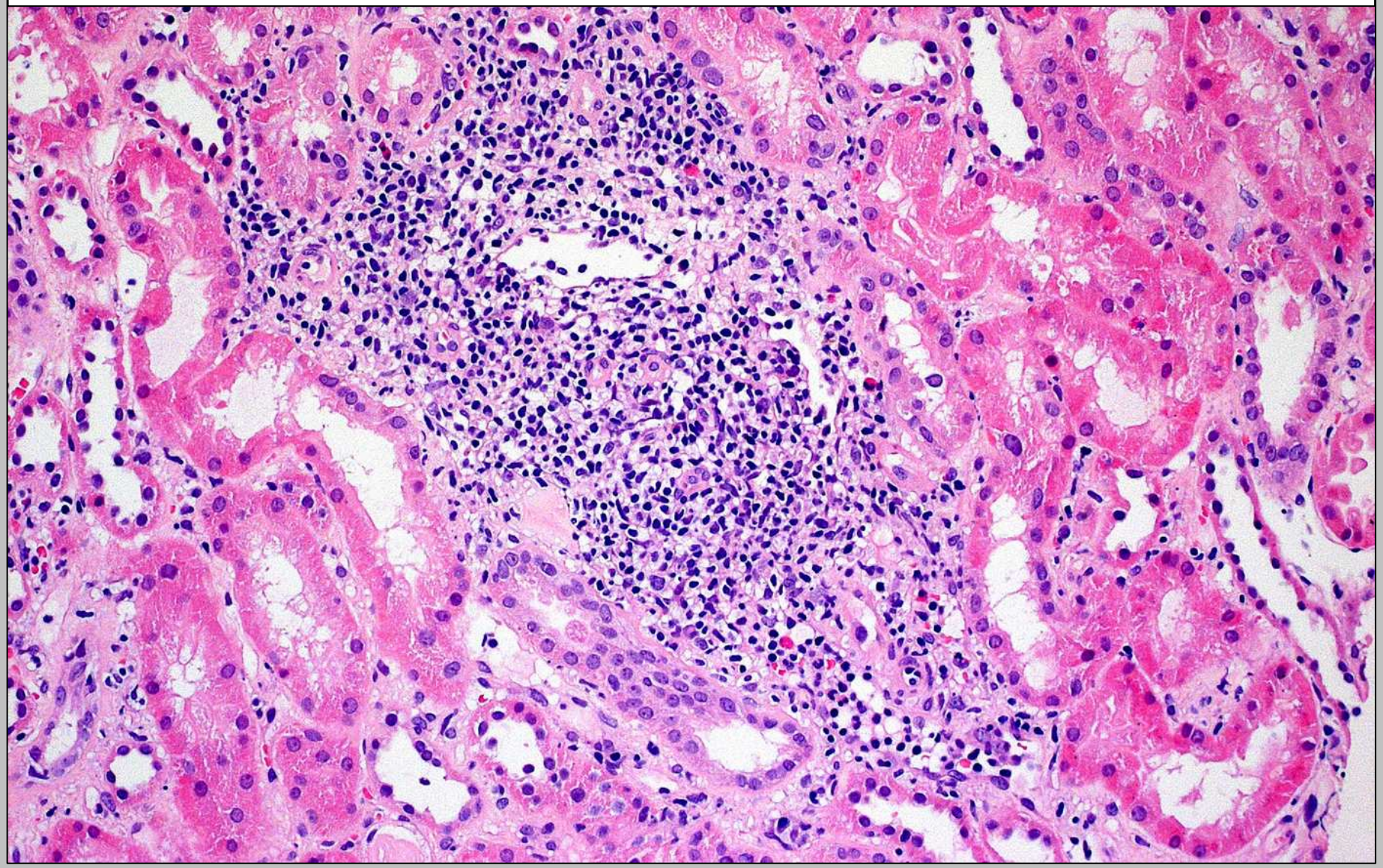

Differential diagnosis of tubulointerstitial rejection

- **Acute pyelonephritis**
  Infiltrates rich in neutrophils, neutrophilic tubulitis

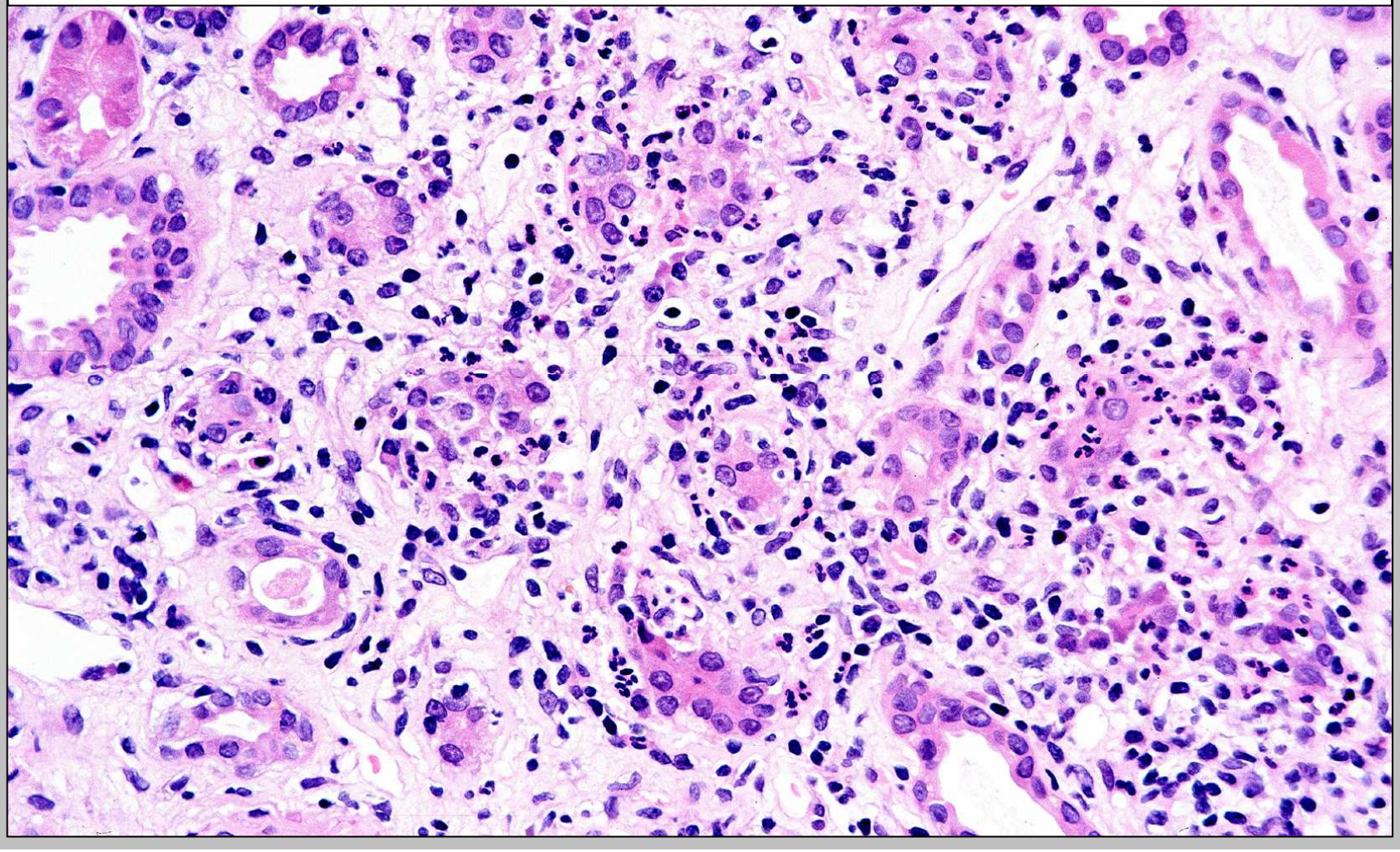

Differential diagnosis of tubulointerstitial rejection

- **Acute pyelonephritis**
  - neutrophilic tubulitis
- **Polyomavirus nephropathy**
  - nuclear inclusion bodies
- **Drug-induced TIN**
  - faint tubular HLA-DR staining
- **Post-transplant lymphoproliferative disease**
  - predominance of B-lymphocytes

Vascular rejection

- Infiltration of the intima by lymphocytes ± monocytes
- Involves the large arteries more frequently than the interlobular arteries

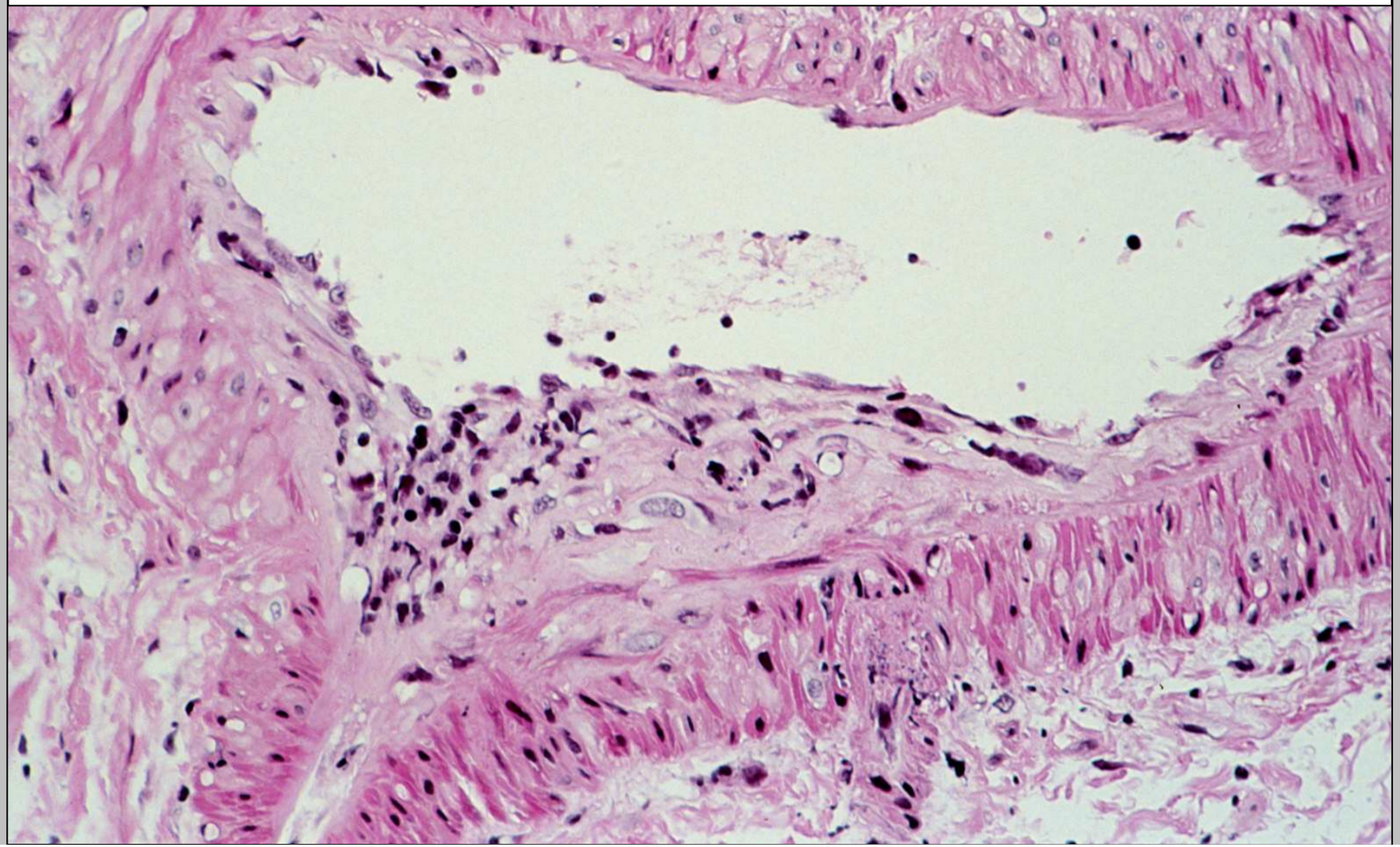

Differential diagnosis

Intimal arteritis is pathognomic for acute T-cell-mediated rejection

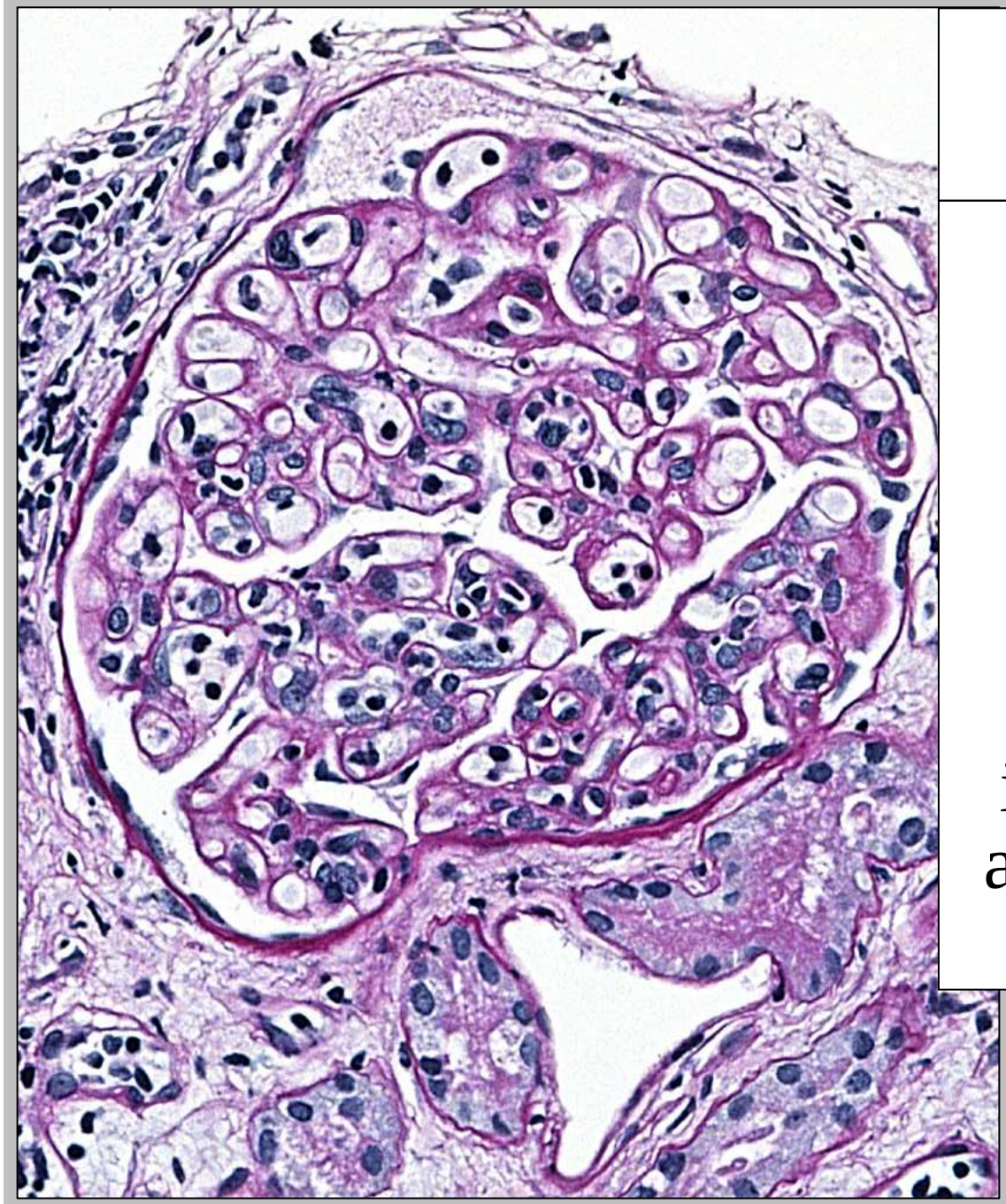

Transplant glomerulitis

Infiltration of the capillary loops by lymphocytes
± monocytes

Isolated transplant glomerulitis:
in 10% of cases with acute T-cell-mediated rejection

Differential diagnosis

Recurrent or *de novo* proliferative GN
(rejection: no glomerular immune deposits)

Clinical correlation of acute T-cell-mediated rejection

- Most common cause of a graft dysfunction in the first 3 months after Tx
- Sudden asymptomatic rise in the serum creatinine level

Outcome of acute T-cell-mediated rejection

- Tubulointerstitial rejection responds well to high-dose iv. steroid therapy
- Vascular rejection can be reversed with anti-lymphocyte antibody preparations
- If not: fibrous obliteration of arteries ⇒ graft loss

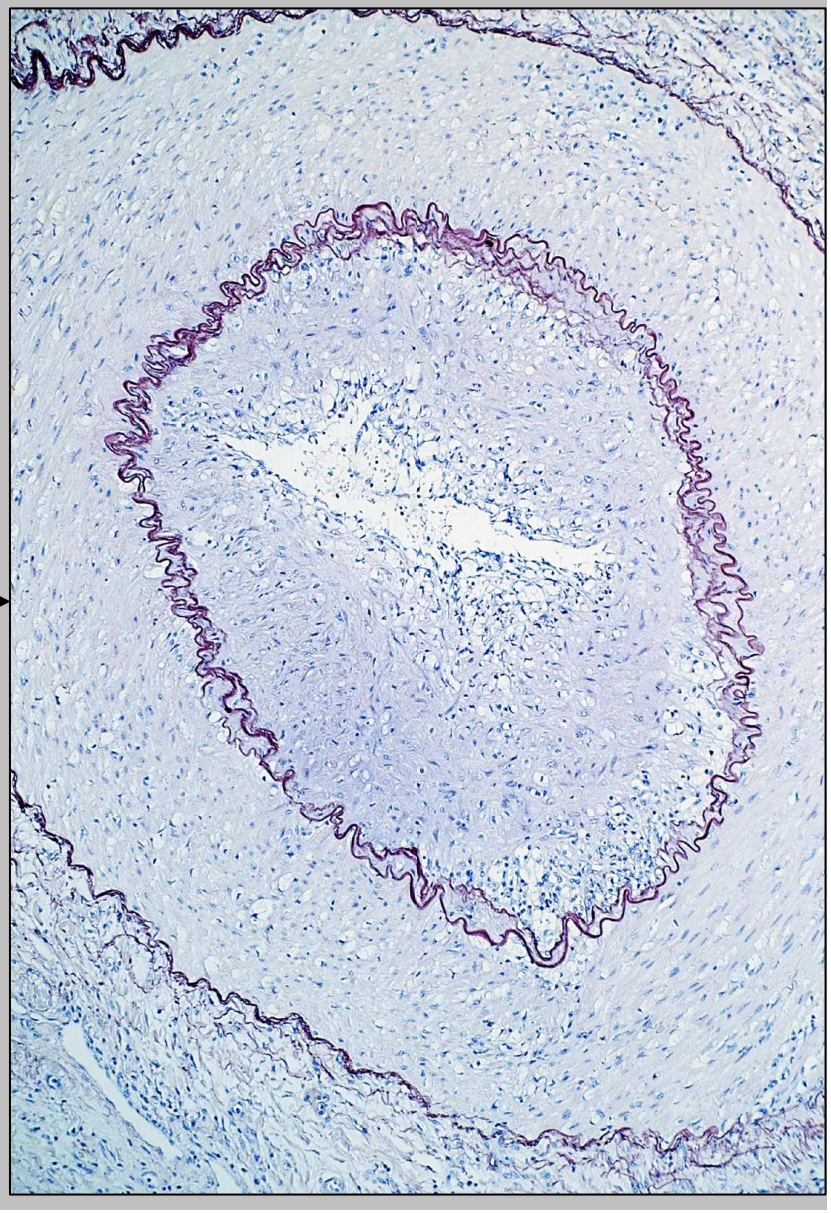

Acute alloantibody-mediated rejection

Donor-specific HLA class I antibodies

↓

Complement-mediated cytotoxic injury to the endothelial cells

Acute alloantibody-mediated rejection

Donor-specific HLA class I antibodies

- **Complement 4d** degradation product binds to PTC endothelial cells
- This stable molecule is detected by IF

Complement-mediated cytotoxic injury to the endothelial cells

Evaluation of C4d

Immunofluorescence on frozen sections is more sensitive than immunohistochemistry on paraffin sections

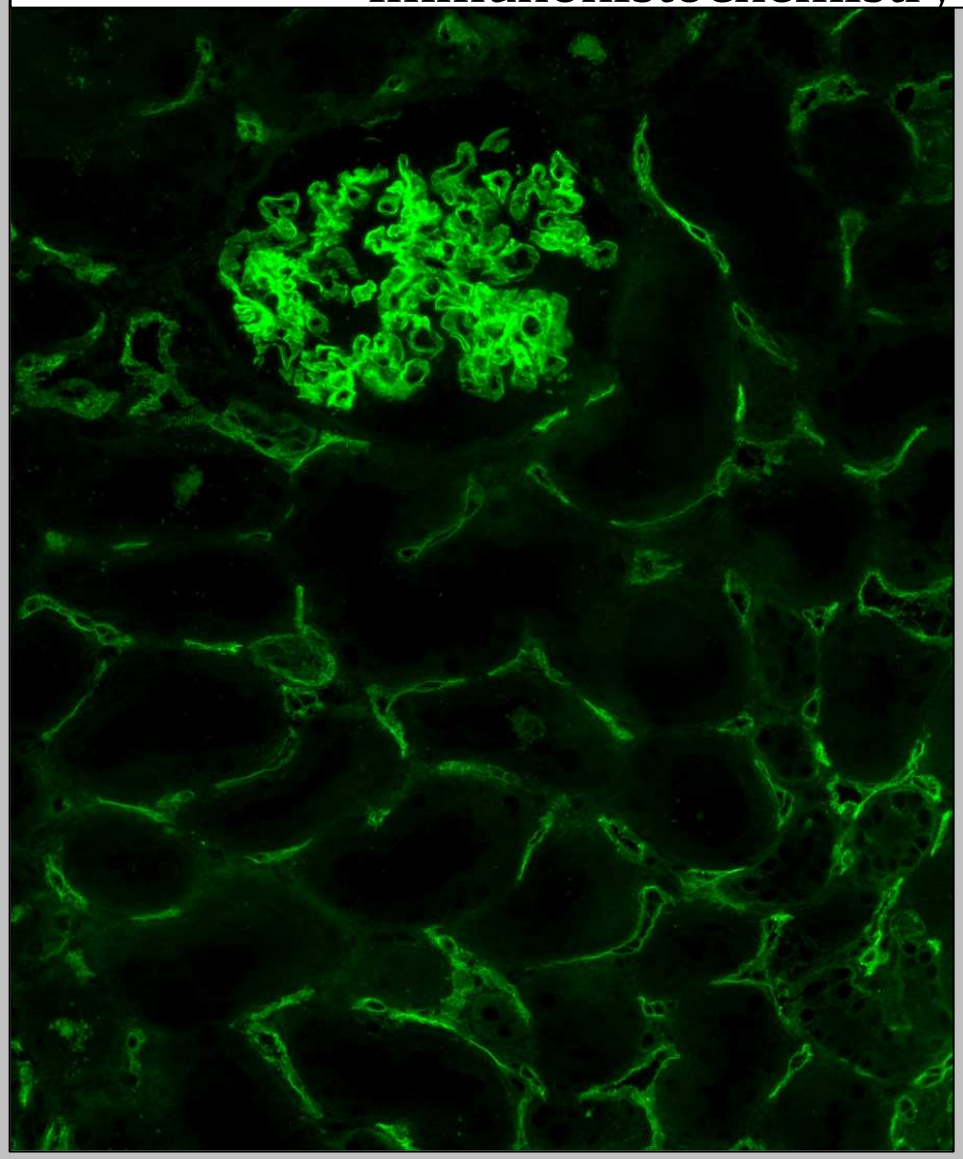

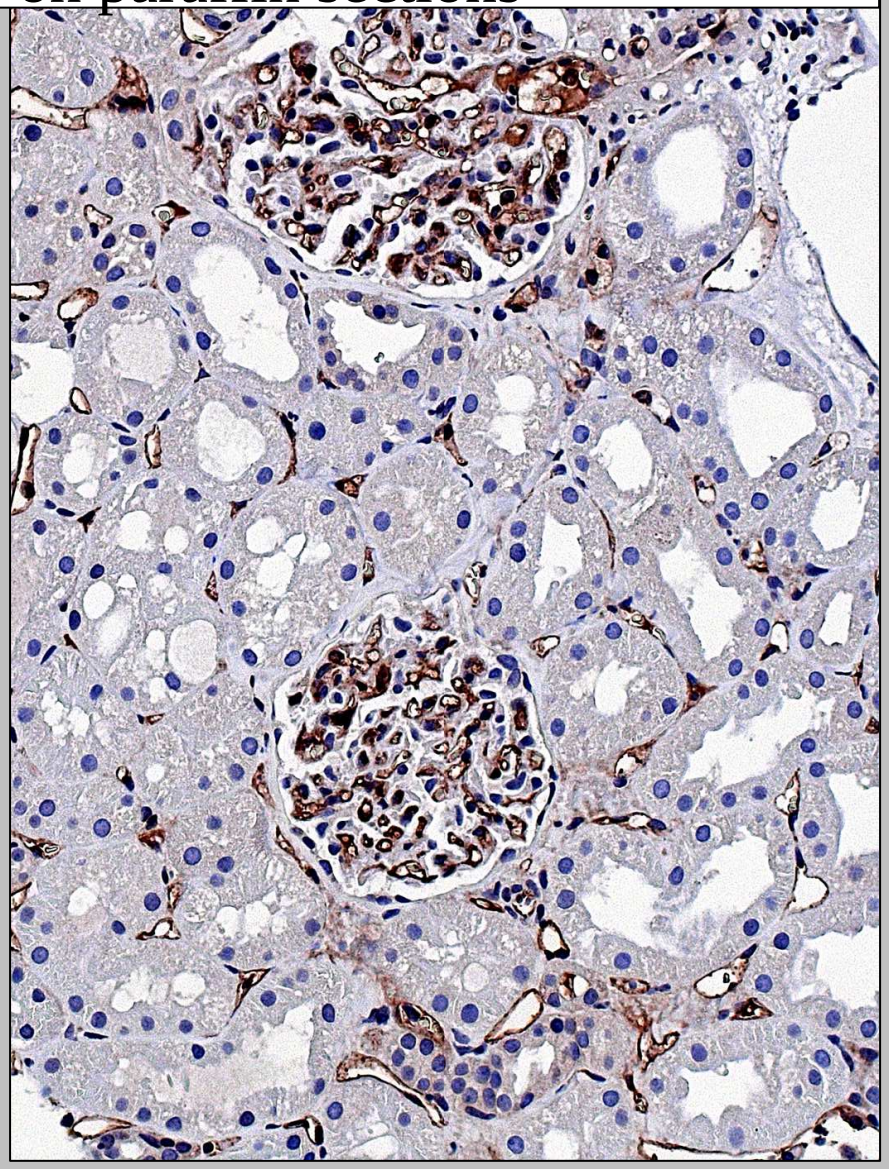

Diagnostic criteria of acute alloantibody-mediated reejction: C4d along PTCs; evidence of tissue injury; demonstration of donor-specific antibodies

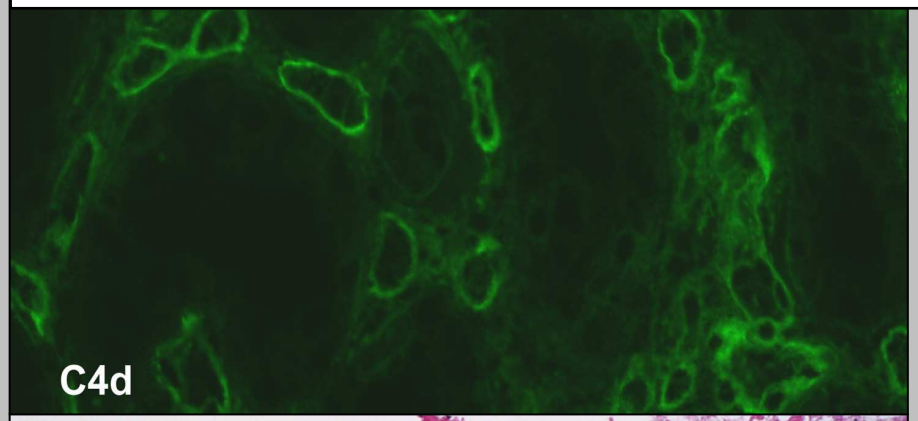

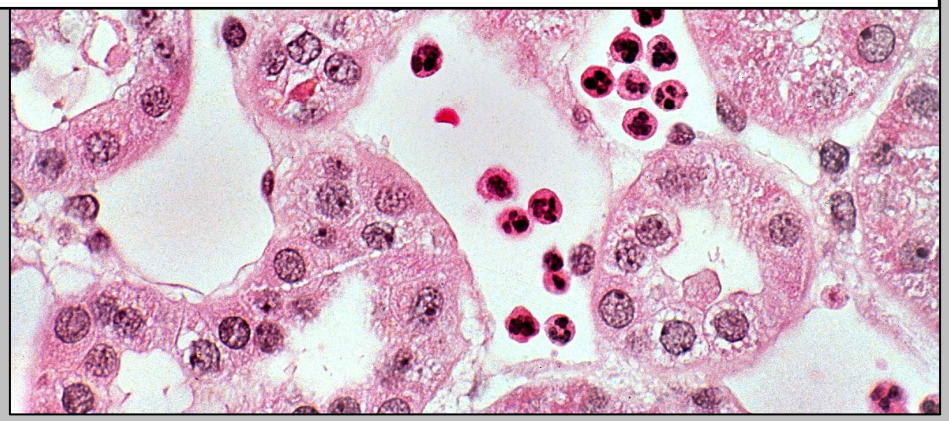

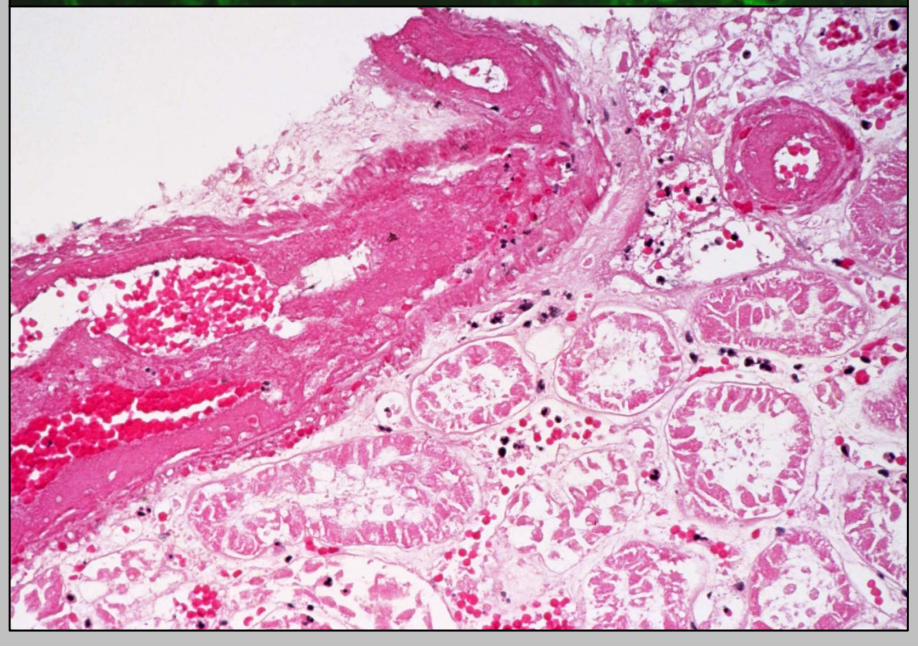

Evidence of tissue injury

1) ATN-like, minimal inflamm.
2) Capillary-NG margination and/or thromboses
3) Transmural arteritis and/or arterial fibrinoid necrosis

Racusen et al. AJT 3:1-7, 2003

Cytotoxic injury to PTC endothelial cells manifests in **lysis** ± **apoptosis**

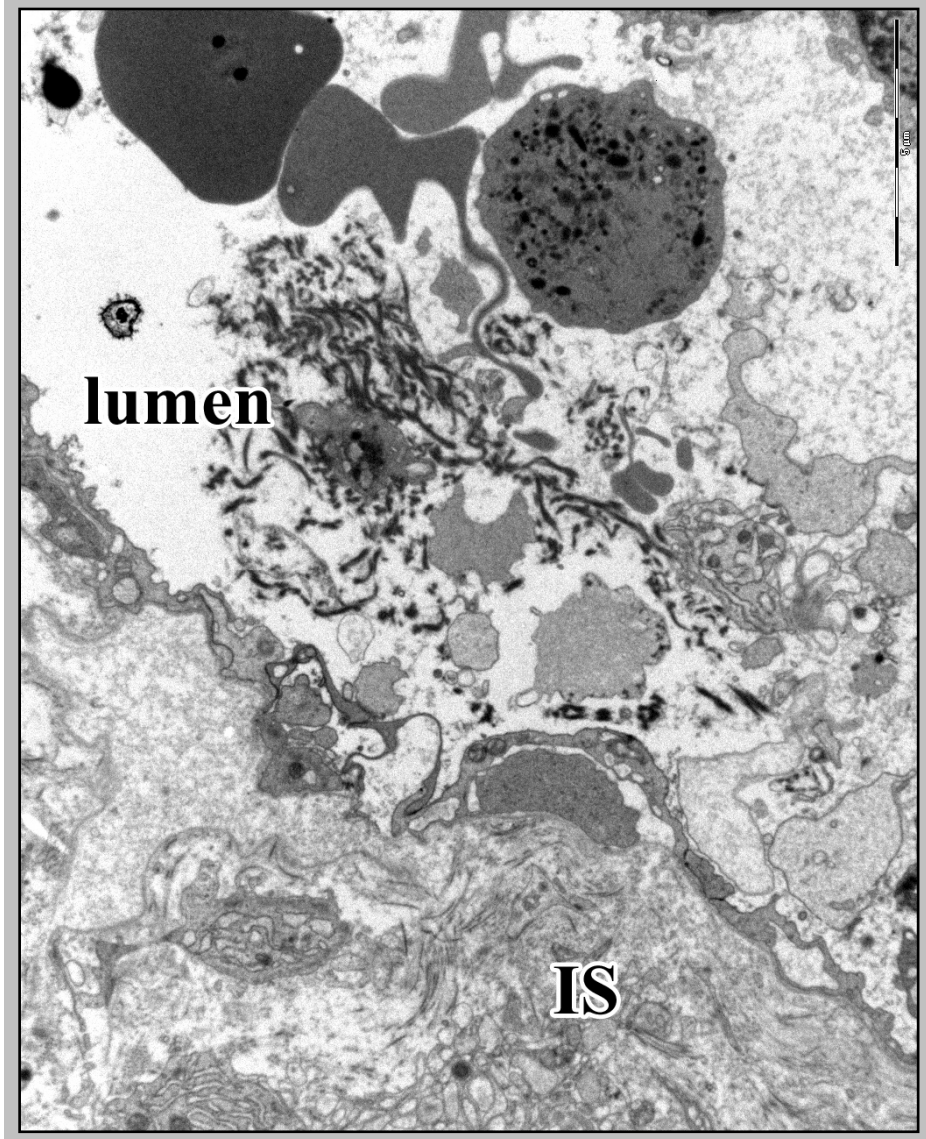

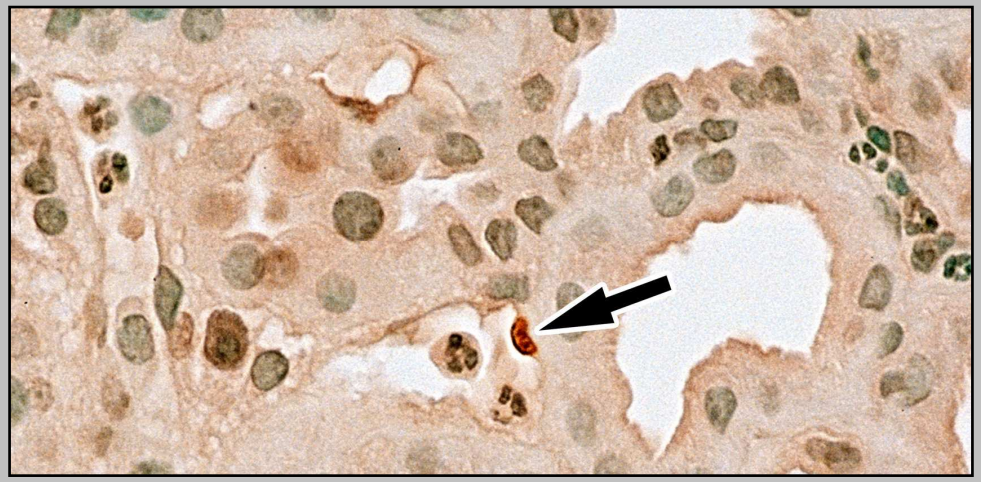

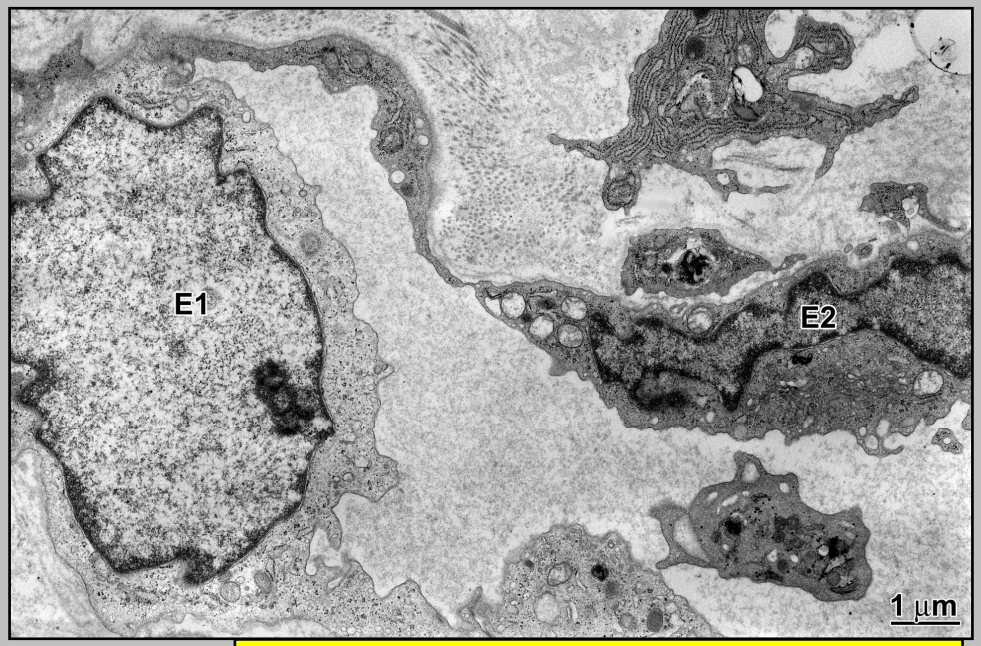

Liptak et al. AJT 5:2870, 2005

Differential diagnosis

- TMA secondary to CNI toxicity
- Anti-cardiolipin sy
- Recurrent HUS
- Viral infection due to CMV or parvovirus B19

Differential diagnosis

- TMA secondary to CNI toxicity
- Anti-cardiolipin sy
- Recurrent HUS
- Viral infection due to CMV or parvovirus B19

Clue

None of these displays C4d positivity along the peritubular capillaries

Clinical correlation

- Infrequent (2-8%)
- Most common in the first few weeks after Tx; oligoanuria develops within days
- Therapeutic efforts may reverse the rejection process
- Poor prognosis

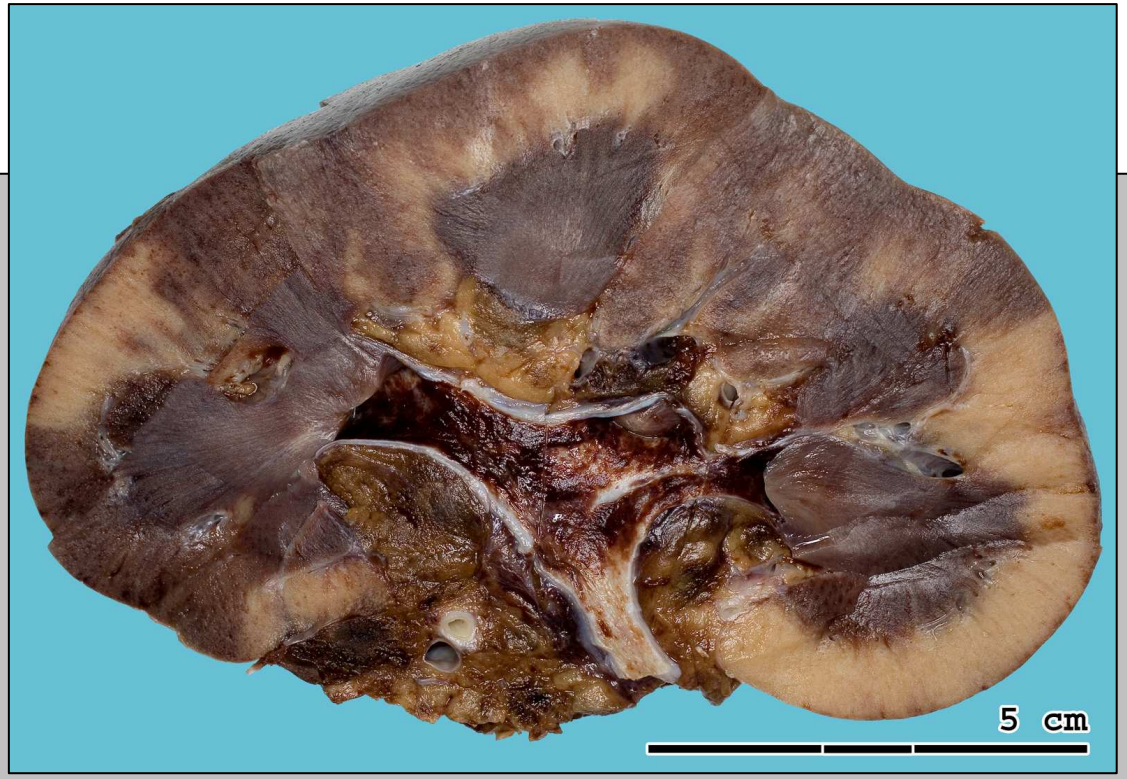

Chronic rejection

Ongoing, smouldering alloimmune damage to the allograft, mediated predominantly by alloantibodies

Vascular lesions are characteristic

Transplant arteriopathy
Transplant glomerulopathy
Transplant capillaropathy

Vascular lesions of chronic rejection
are associated with
interstitial fibrosis
and tubular atrophy (IF/TA)

Tx arteriopathy: new-onset intimal fibrosis

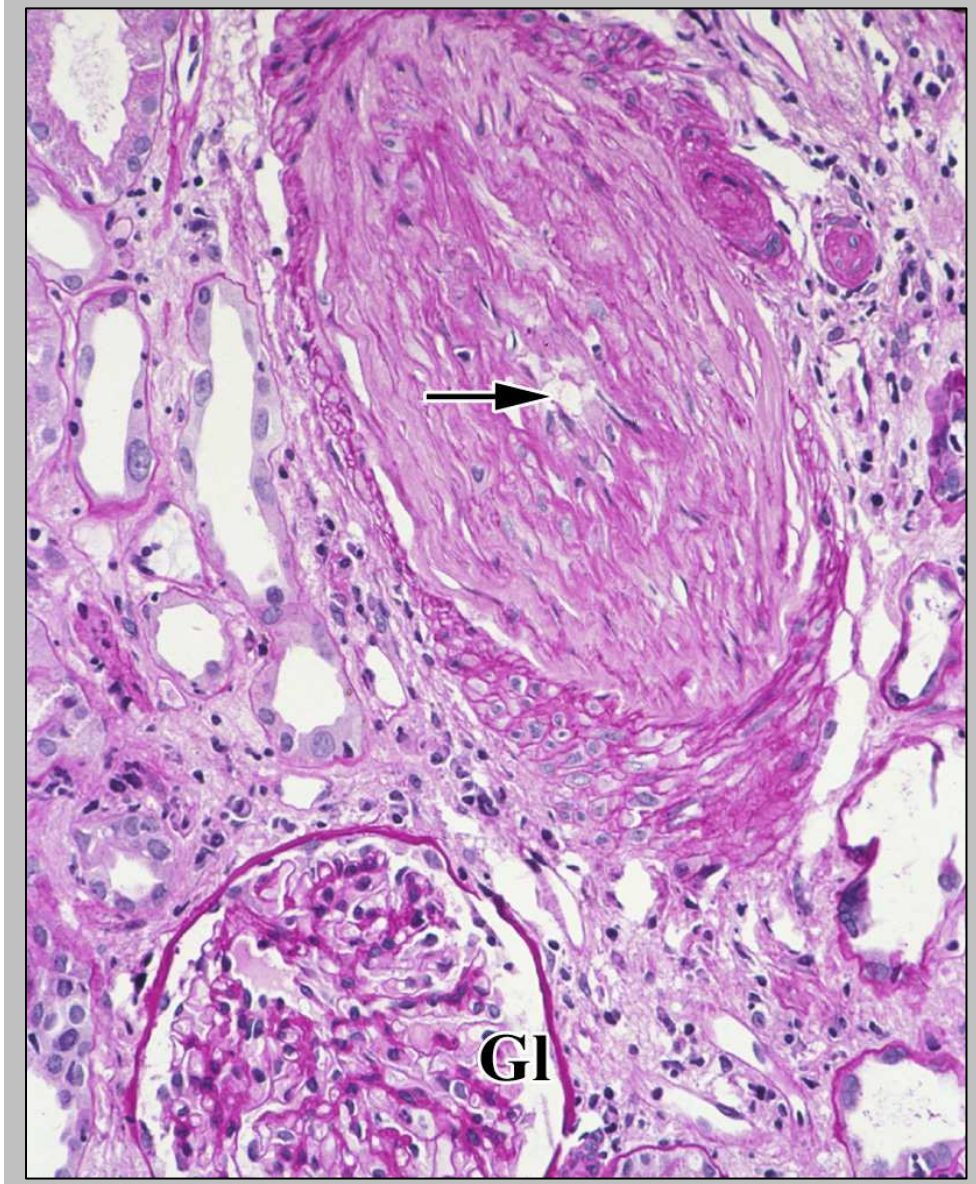

Absence of elastosis

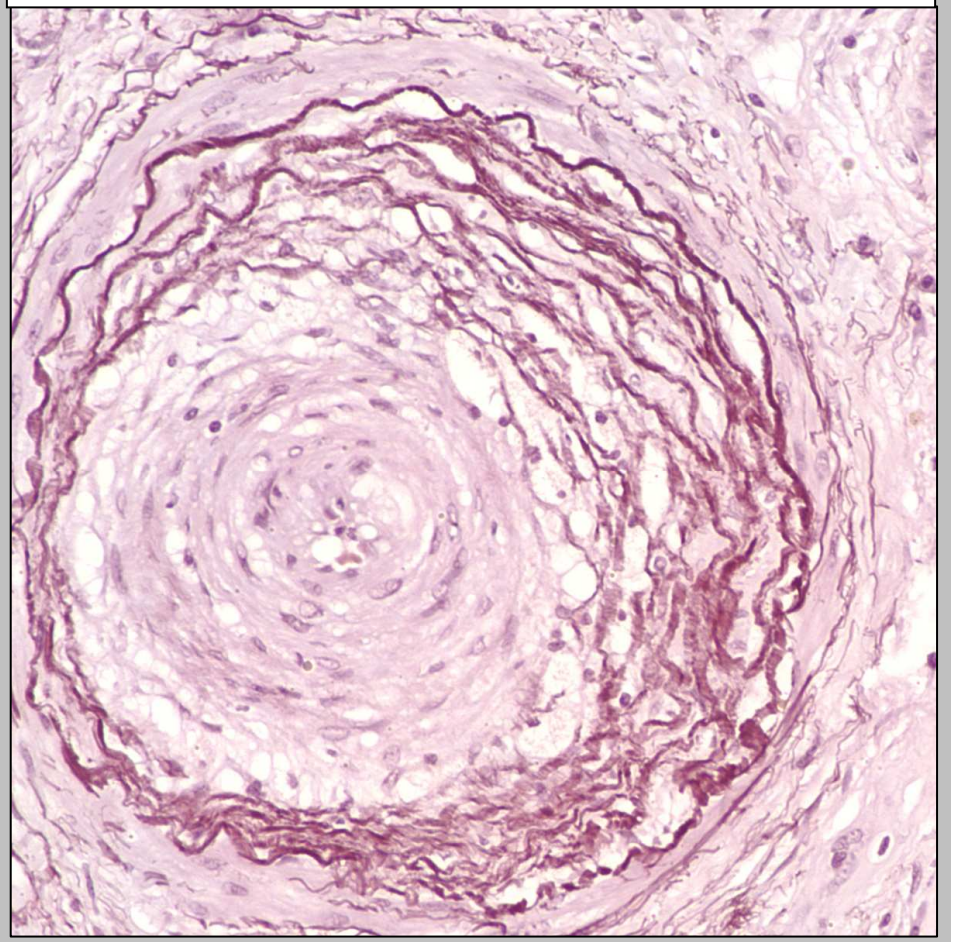

Tx arteriopathy is more pronounced in the arcuate and larger arteries than in the small arteries of the superficial cortex

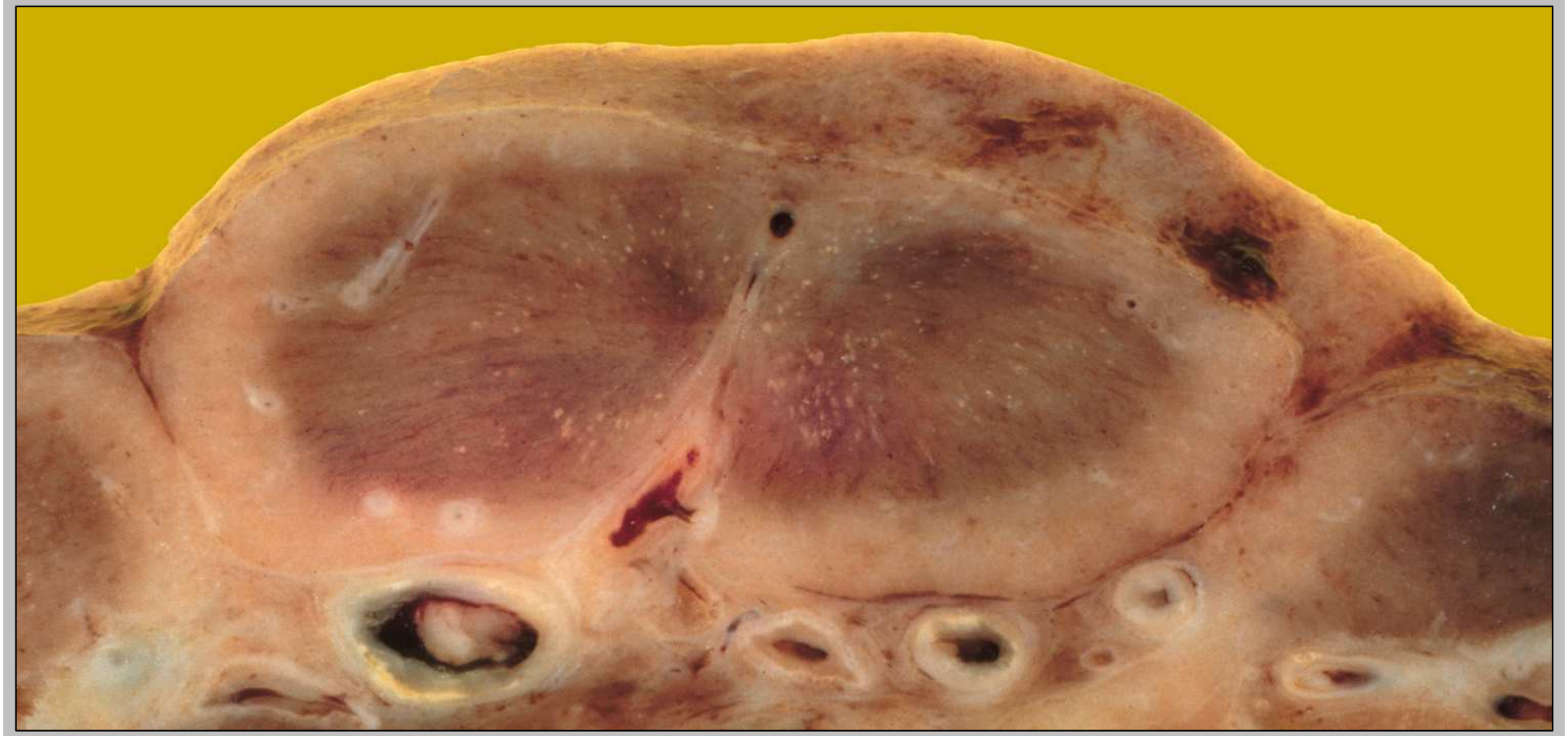

Consequence

Chronic progressive ischemic injury to the graft parenchyma

Tx glomerulopathy:
double-contoured loops;
EM: newly formed BM layer(s)

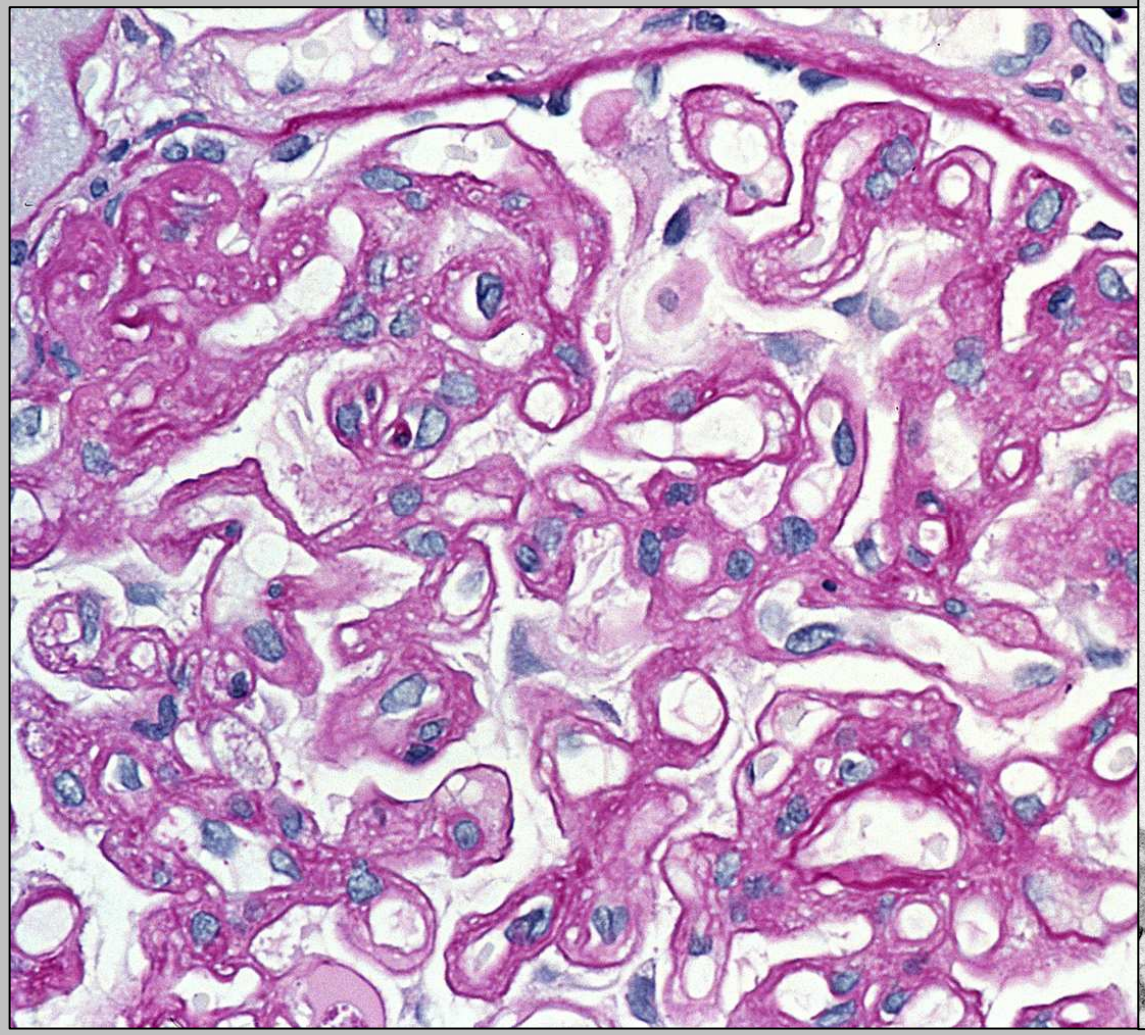

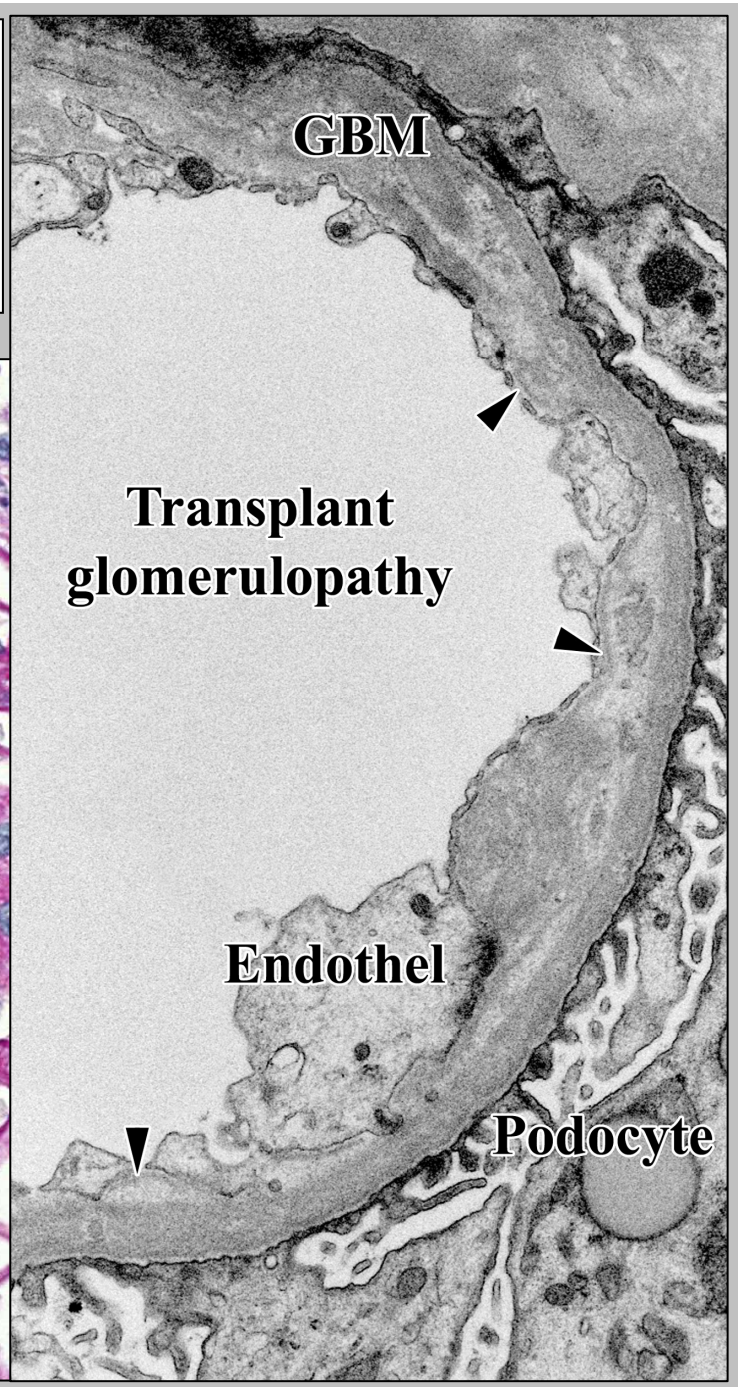

Consequences

Proteinuria

Focal glomerular obsolescence

Tx glomerulopathy may resemble to recurrent or de novo MPGN; no immunocomplexes on IF

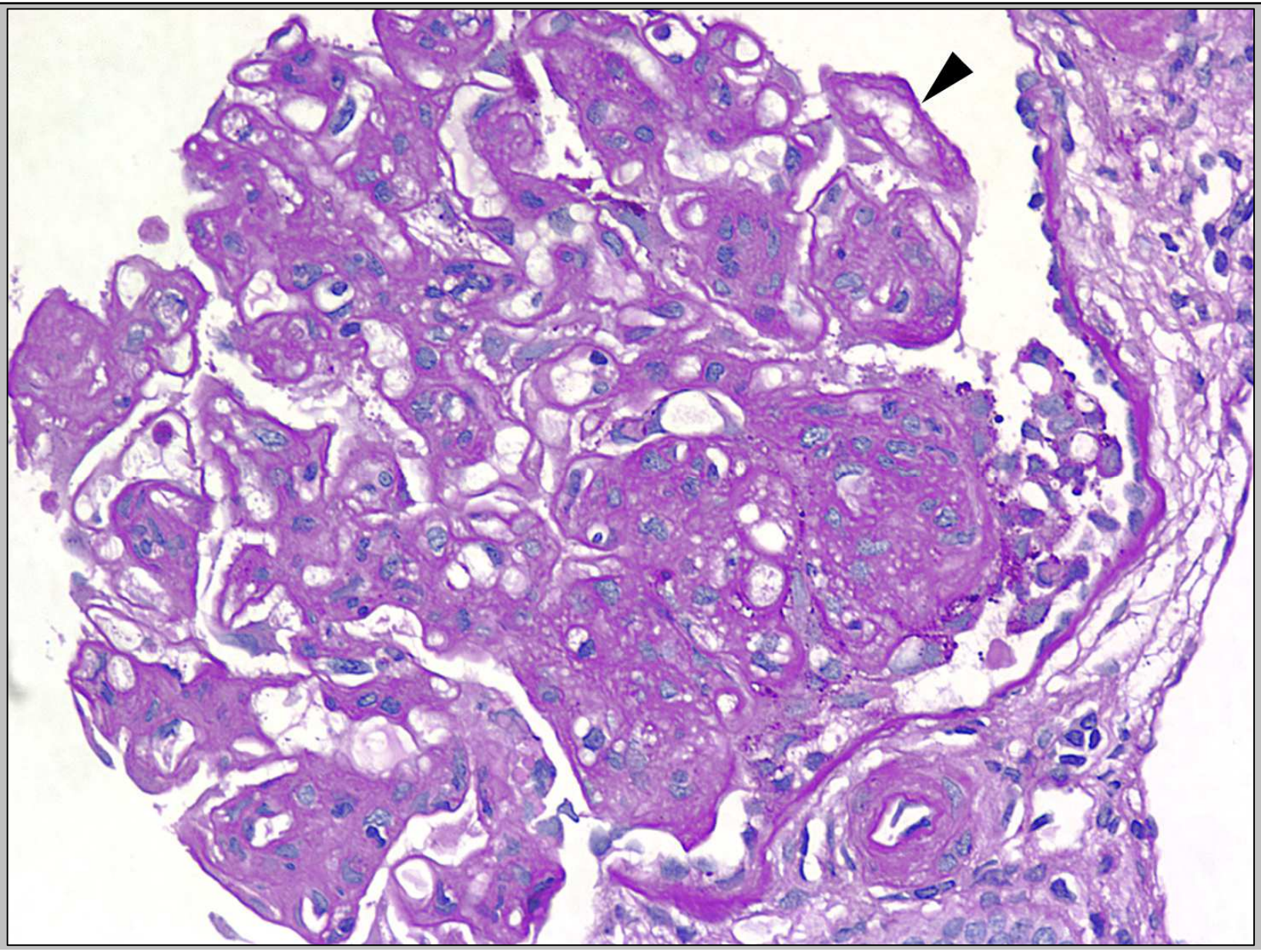

Tx capillaropathy: circumferentially laminated BM; pathognomic: 5 or more BM layers; C4d+ along PTCs

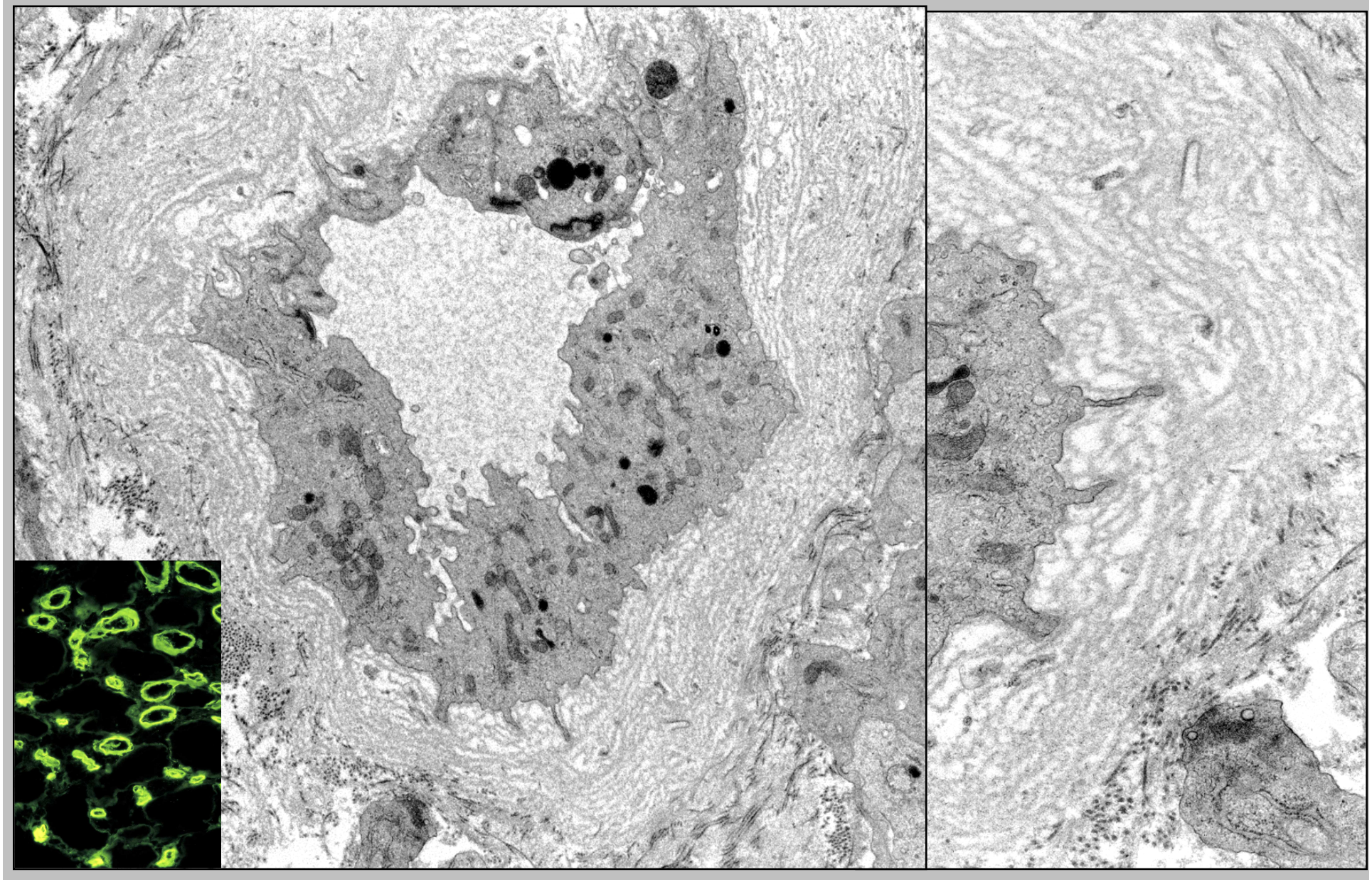

Tx capillaropathy on light microscopy: thickened and laminated BMs; EM is more sensitive in the verification of TxC

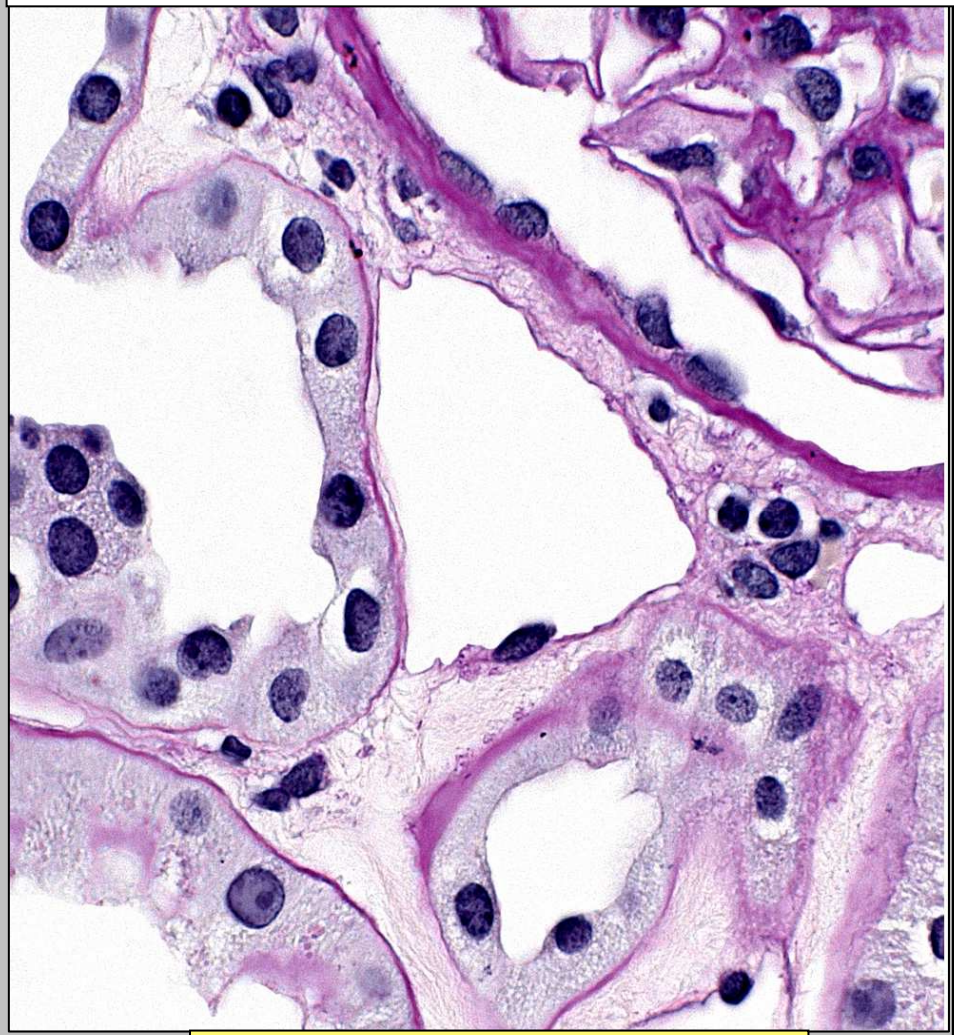

Well-functioning graft

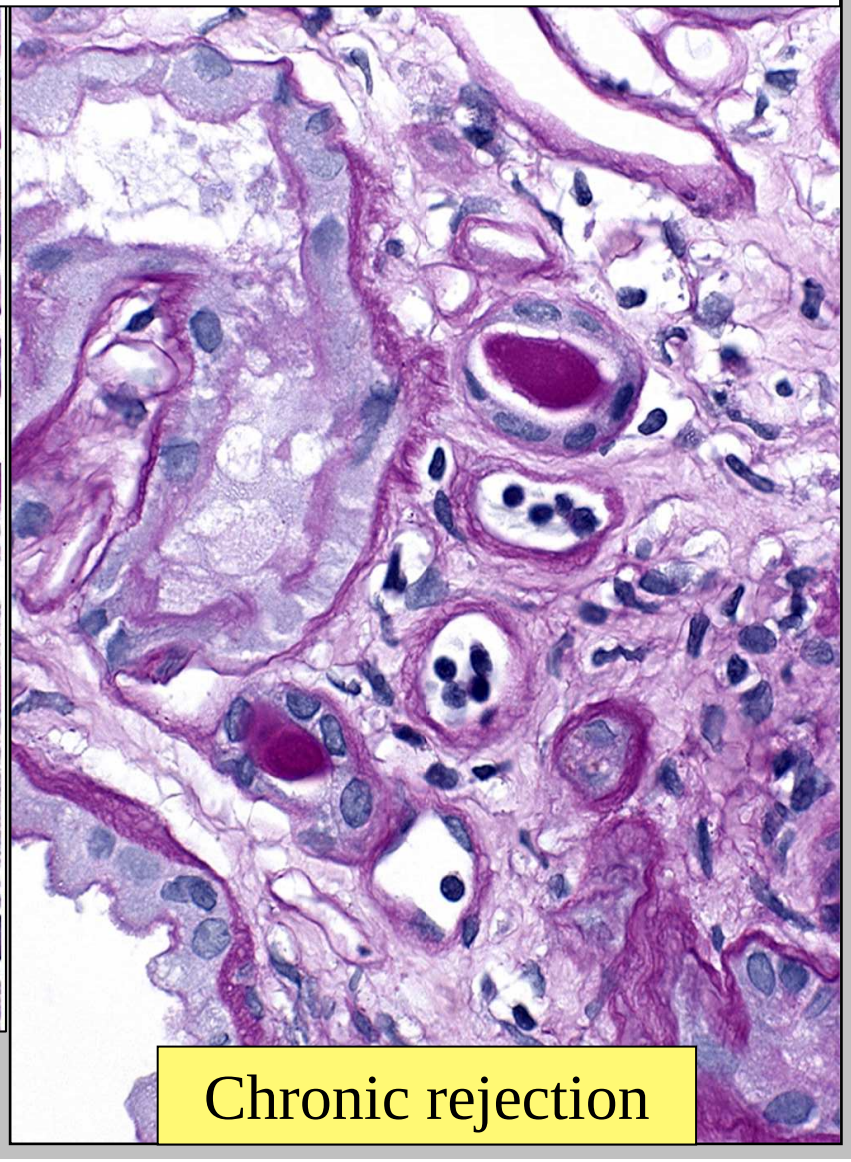

Chronic rejection

Consequence

A progressive decrease in the number of PTCs

Diagnostic triad of chronic antibody-mediated rejection

1) TxA, TxG, TxC either alone or in combination

2) Diffuse C4d deposition in PTCs

3) Presence of donor-specific antibody

Solez et al. AJT 7:1-9, 2006

Chronic active T-cell-mediated rejection

Lymphocytes in arterial intimal fibrosis

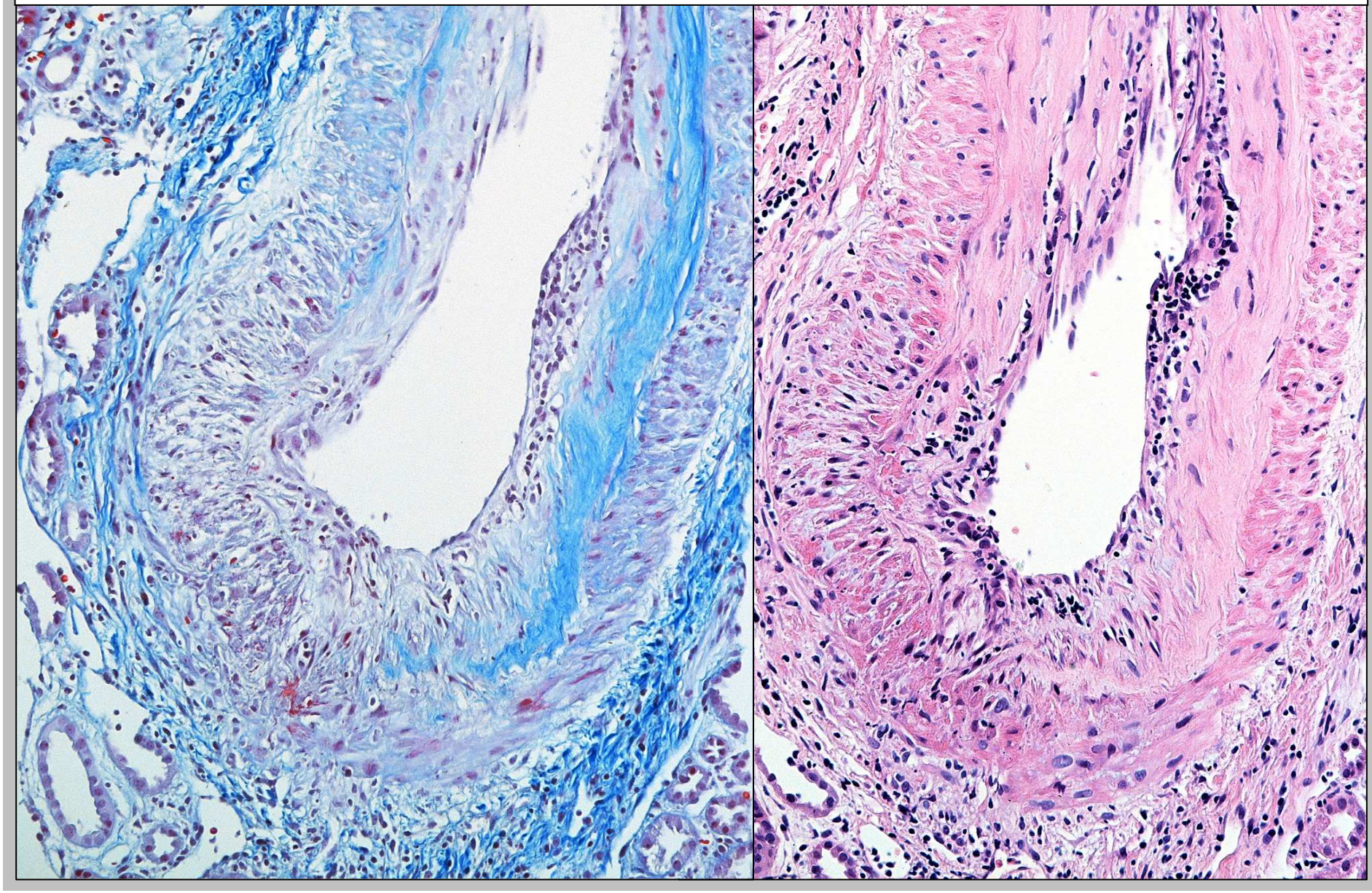

Clinical correlation of chronic rejection

- Major cause of graft loss after 1 year
- Insidious, progressive decline in the GFR, frequently accompanied by proteinuria (often in the nephrotic range) and hypertension

Calcineurin inhibitor toxicity

Cyclosporin and tacrolimus can cause acute or chronic nephrotoxicity; the lesions are identical

Acute toxicity

- Toxic tubulopathy
- Vascular toxicity
  - Acute arteriolopathy
  - TMA

Chronic toxicity

- Hyaline arteriolopathy

Liptak P, Ivanyi B. Nature Clin Pract Nephrol 2:398-404, 2006

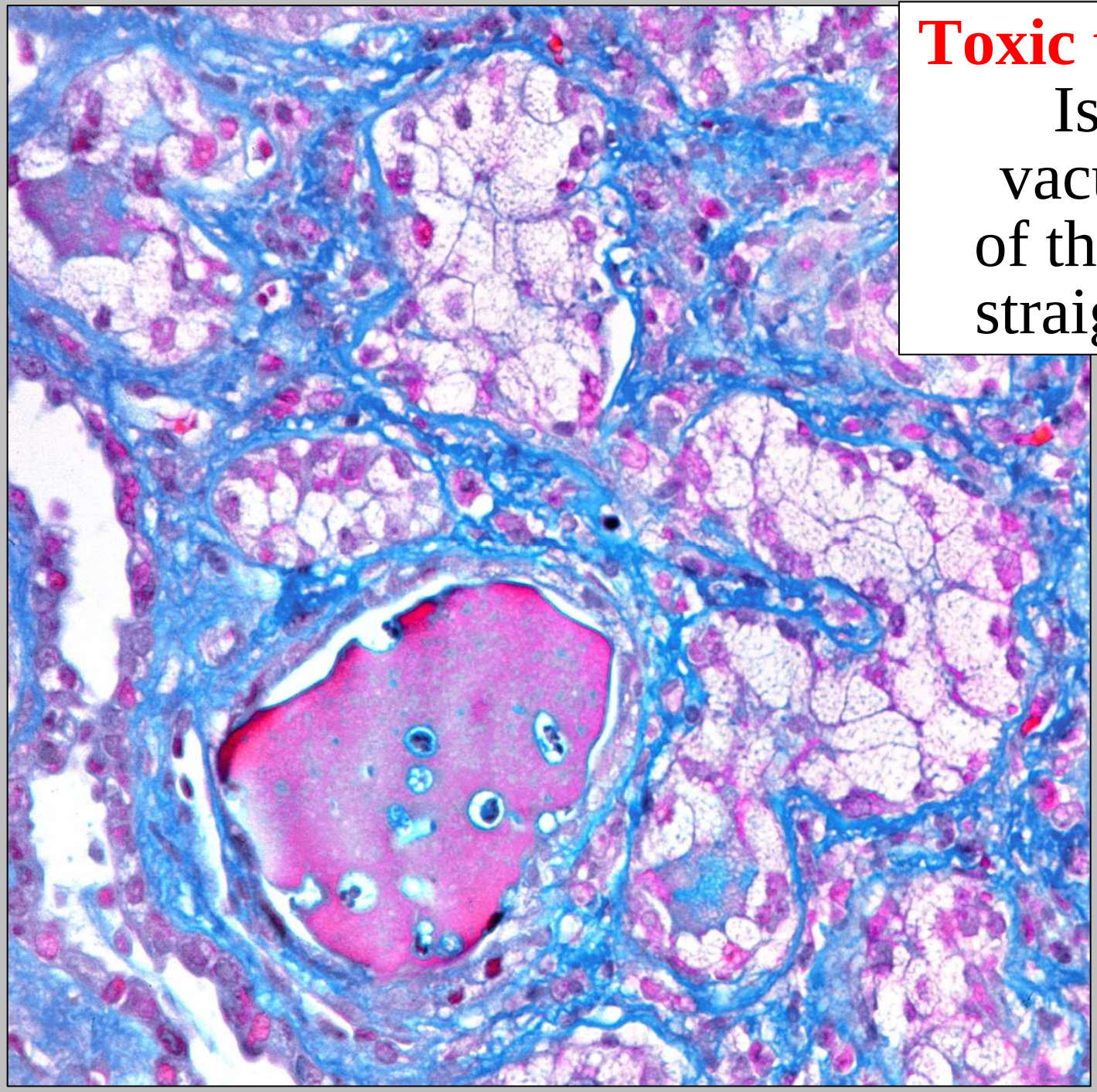

Toxic tubulopathy

Isometric vacuolization of the proximal straight tubules

Differential diagnosis

The features of this tubulopathy cannot be distinguished from those of

radiocontrast nephrotoxicity or

osmotic nephrosis,

conditions to be considered while making the diagnosis

Acute arteriolopathy: SMC injury; replacement of damaged myocytes by rounded plasma protein insudates

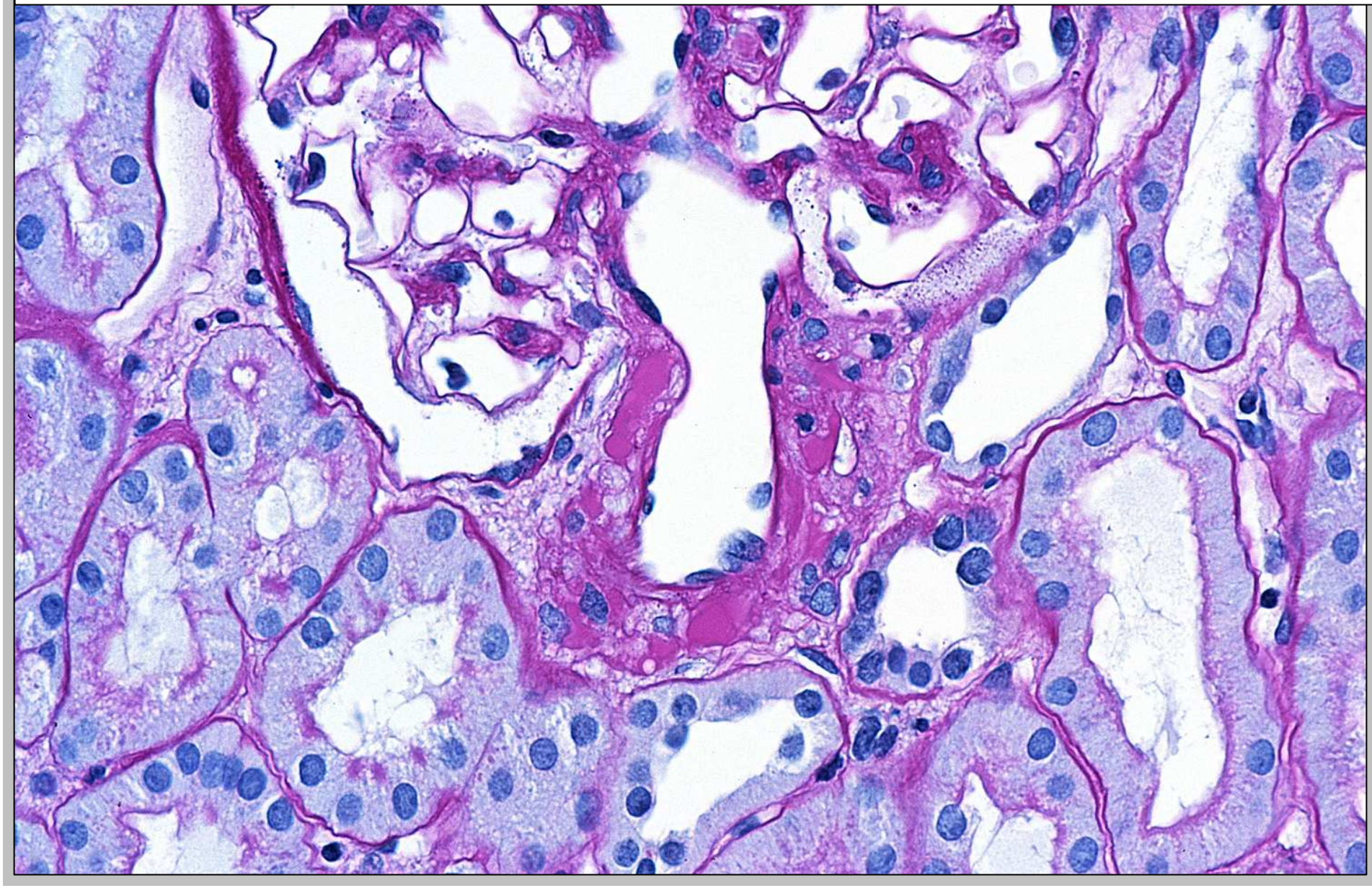

Clinical correlation

- Acute dysfunction
- The serum drug level is usually elevated
- Toxic tubulopathy is reversible
- Acute arteriolopathy may be irreversible

TMA: thrombi in glomerular capillary loops

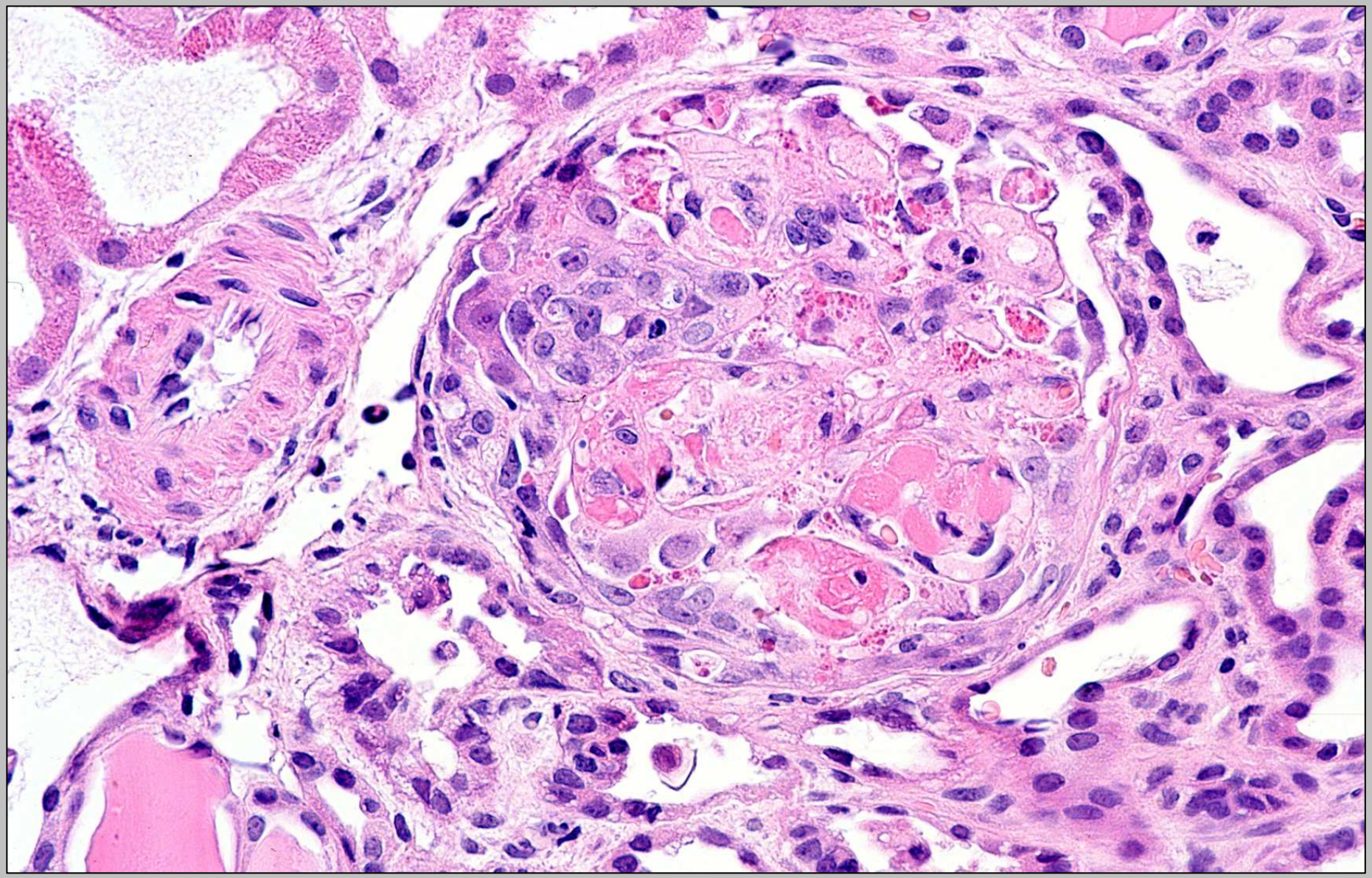

Differential diagnosis

- CNI-induced TMA cannot be differentiated from other forms of TMA by morphology alone

- Pronounced arterial changes are not typical of CNI-induced TMA

- **Acute humoral rejection (C4d+)**
- **Recurrent HUS**

Clinical correlation

- Rare
- Resembles the HUS
- If the lesions are associated with extensive thrombosis, graft loss develops

Chronic toxicity: hyaline arteriolopathy

- The damaged SMCs are replaced by beaded hyaline deposits that bulge into the adventitia
- The insudates are positive for IgM and C3

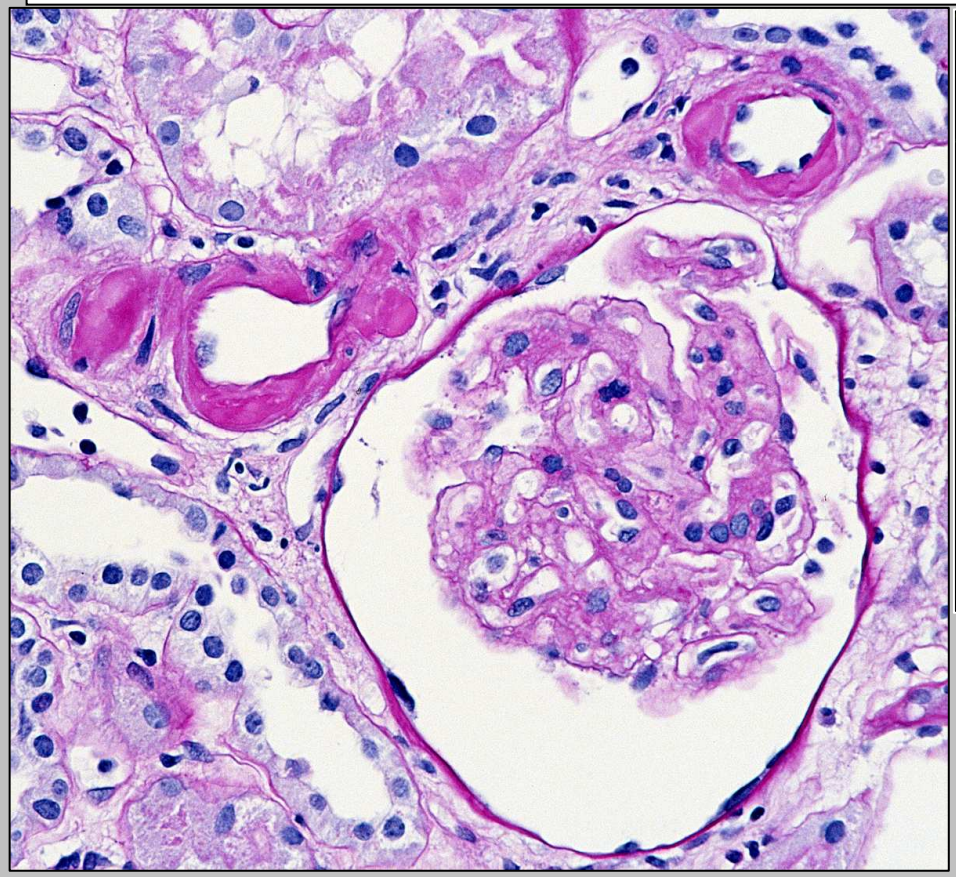

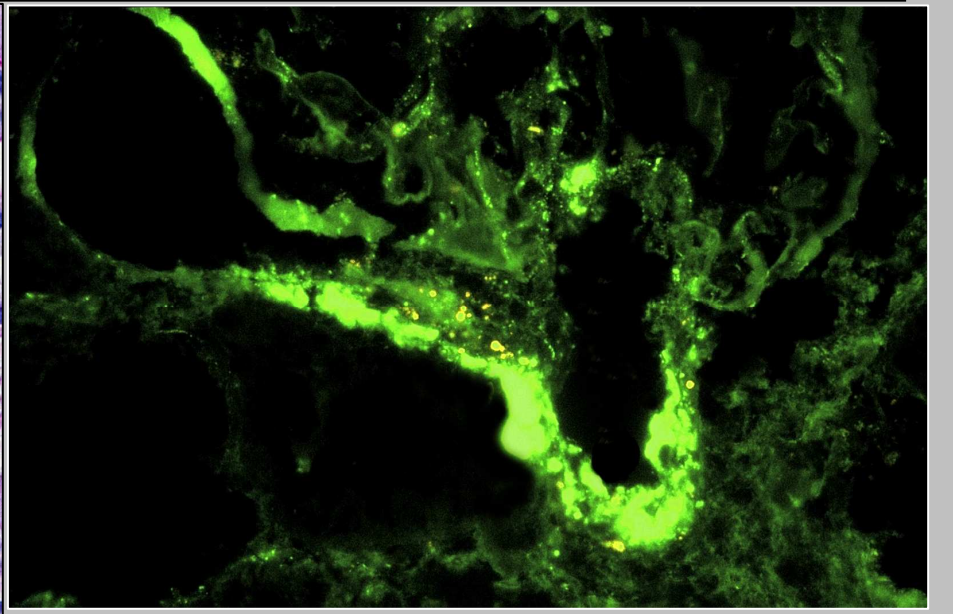

Hyaline material (H) is present at sites where media SMCs have dropped out previously. E - swollen endothelial cells, A - apoptotic SMCs.

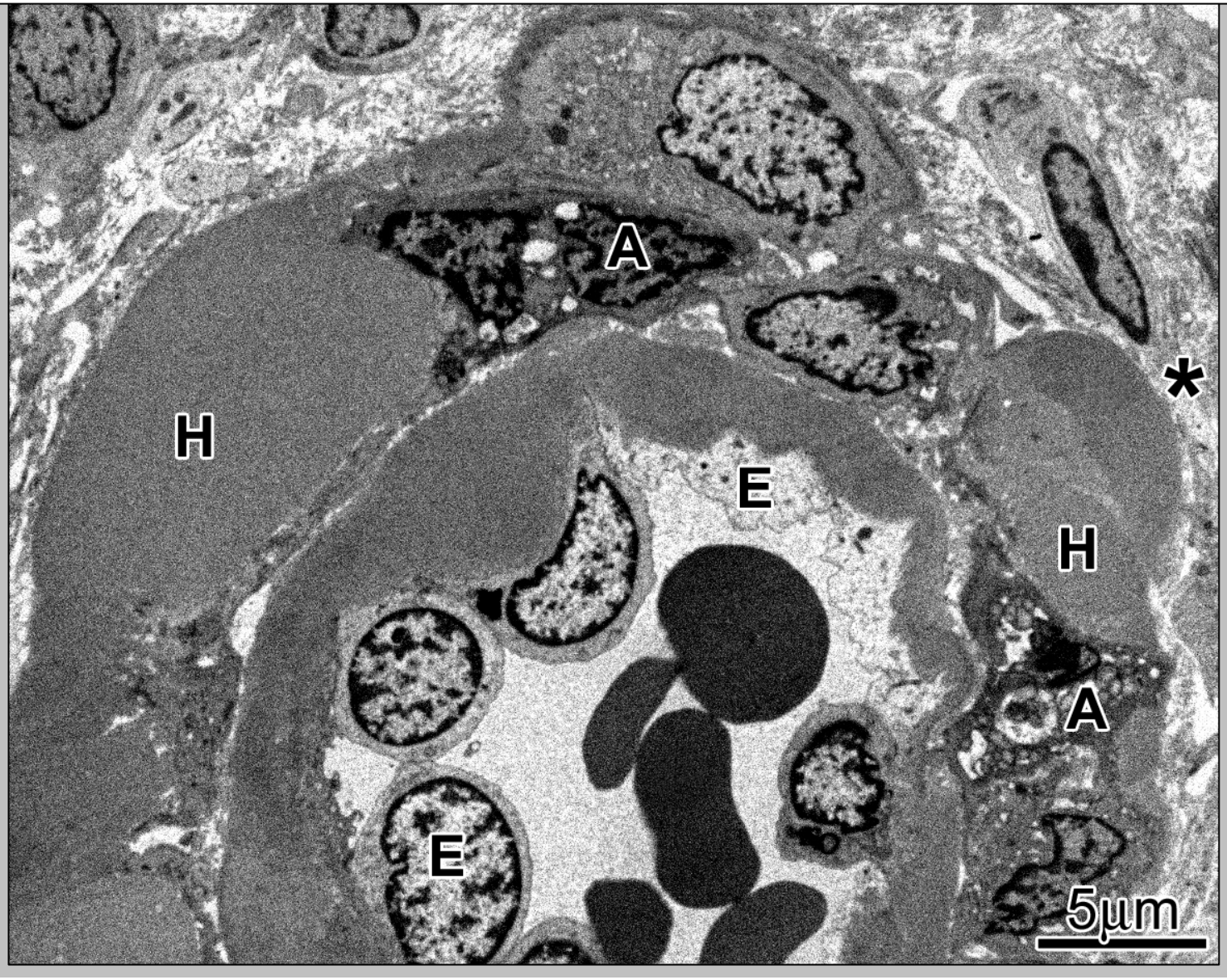

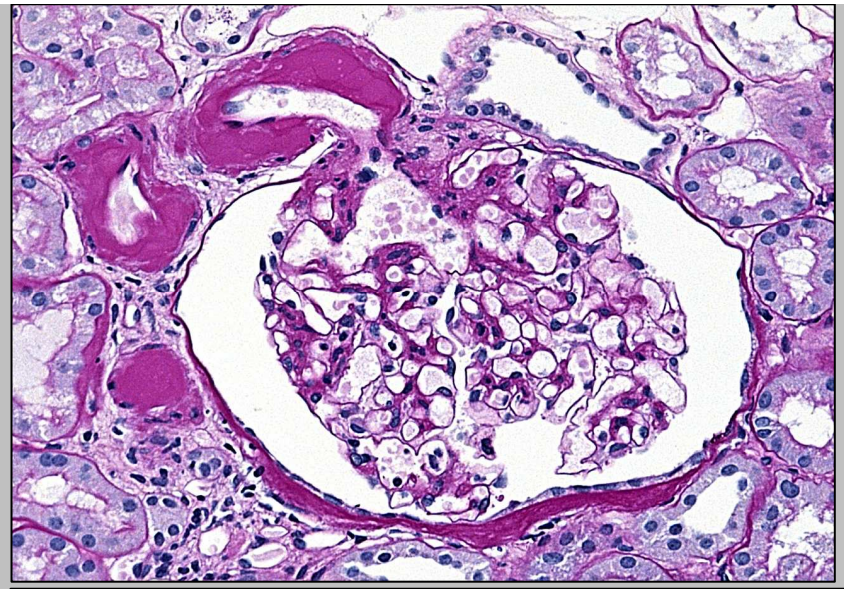

Hyaline arteriolopathy is associated with striped IF/TA

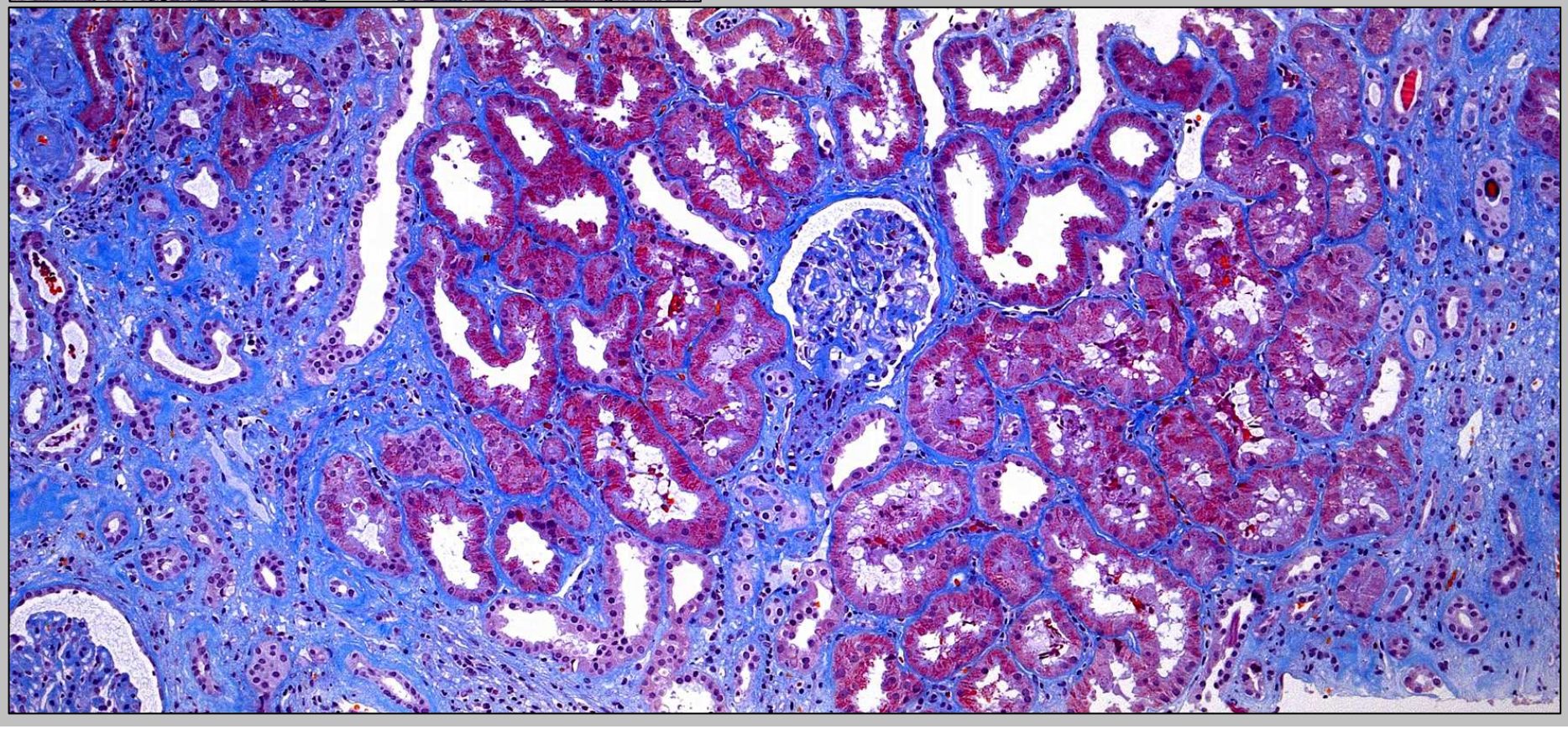

Differential diagnosis

Hyalinosis in ageing, hypertension and diabetes:

- Mainly subendothelial and rarely extends into the adventitia
- Necrosis of the SMCs is not observed

Clinical correlation

- Chronic toxicity occurs several months after Tx; the incidence increases with time
- A slow, insidious rise in the serum creatinine level
- The kidney damage is irreversible

Ageing/hypertension: intimal fibroelastosis; subendothelial arteriolar hyalinosis; patchy segmental/global glomerulosclerosis; IF/TA

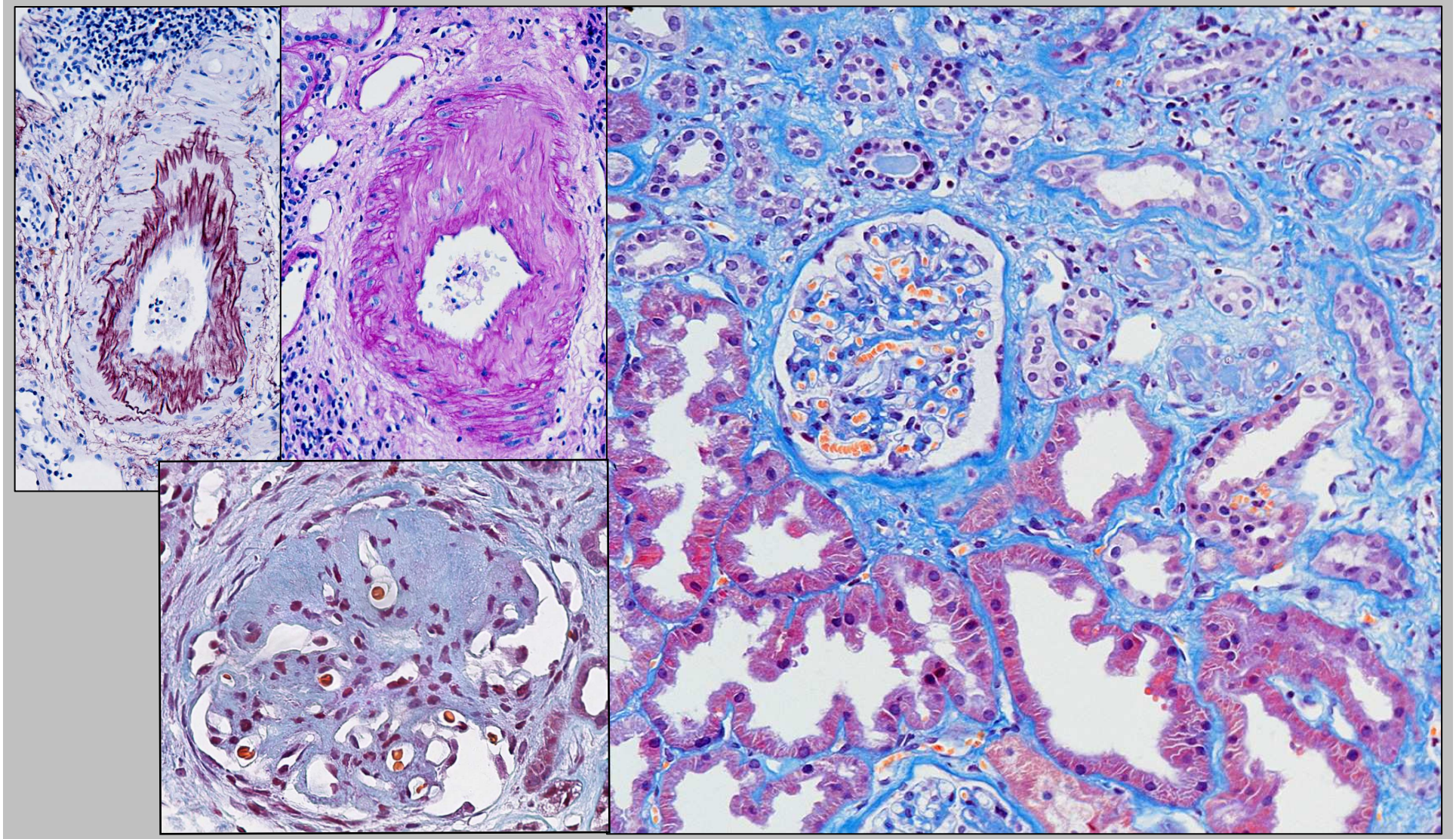

Polyomavirus nephropathy

- The BK polyomavirus exhibits tropism for the renal tubular epithelium, where it establishes latent infection
- Vigorous immunosuppression can lead to reactivation of the infection and the development of PVN
- The definitive diagnosis requires an allograft Bx

Drachenberg et al. Hum Pathol 36:1245-1255, 2005

Viral replication results in cytopathic changes
(nuclear enlargement, inclusion bodies, tubular cell injury)

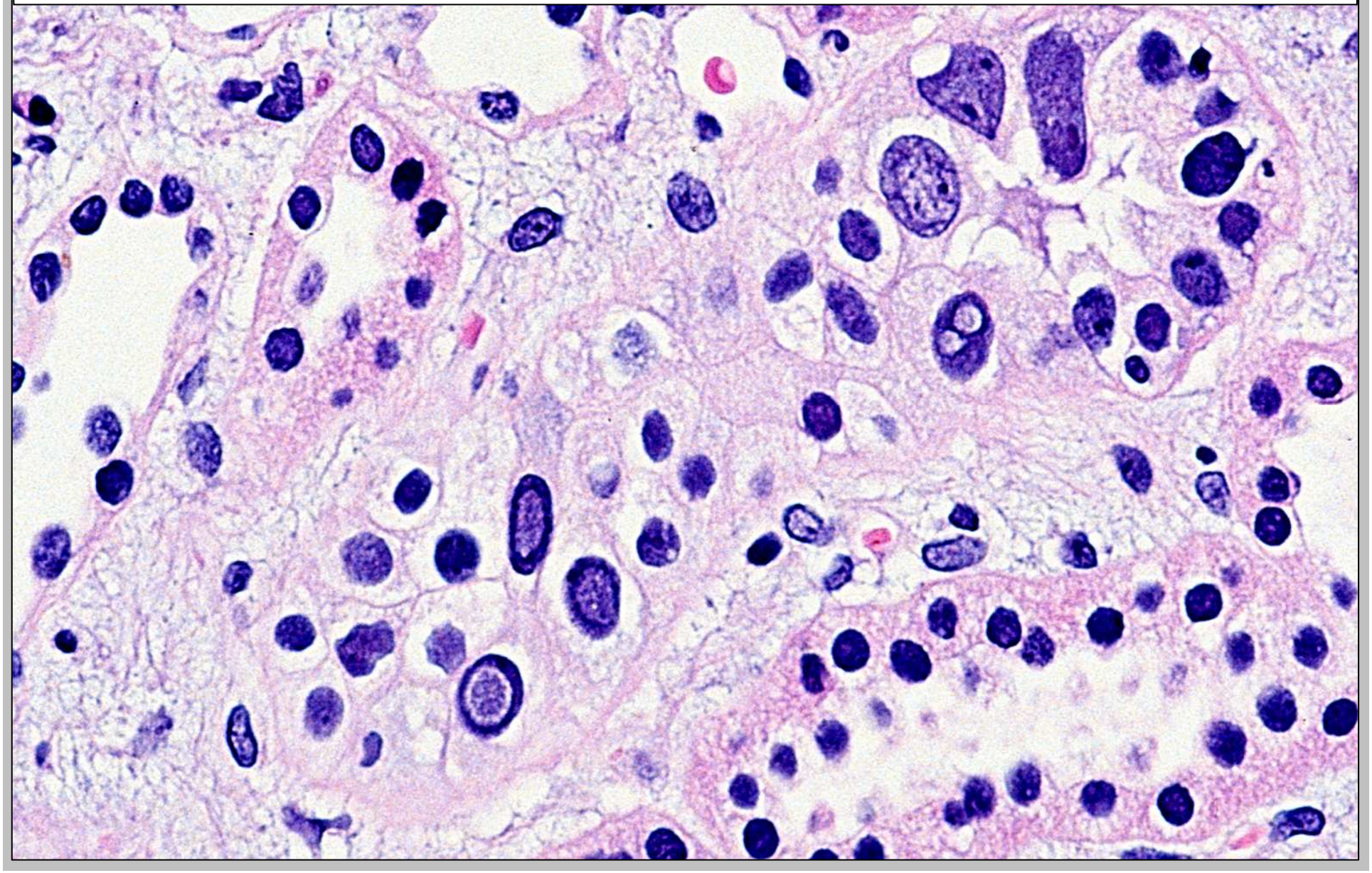

Massive replication leads to cytolysis of tubular epithelial cells and interstitial inflammation

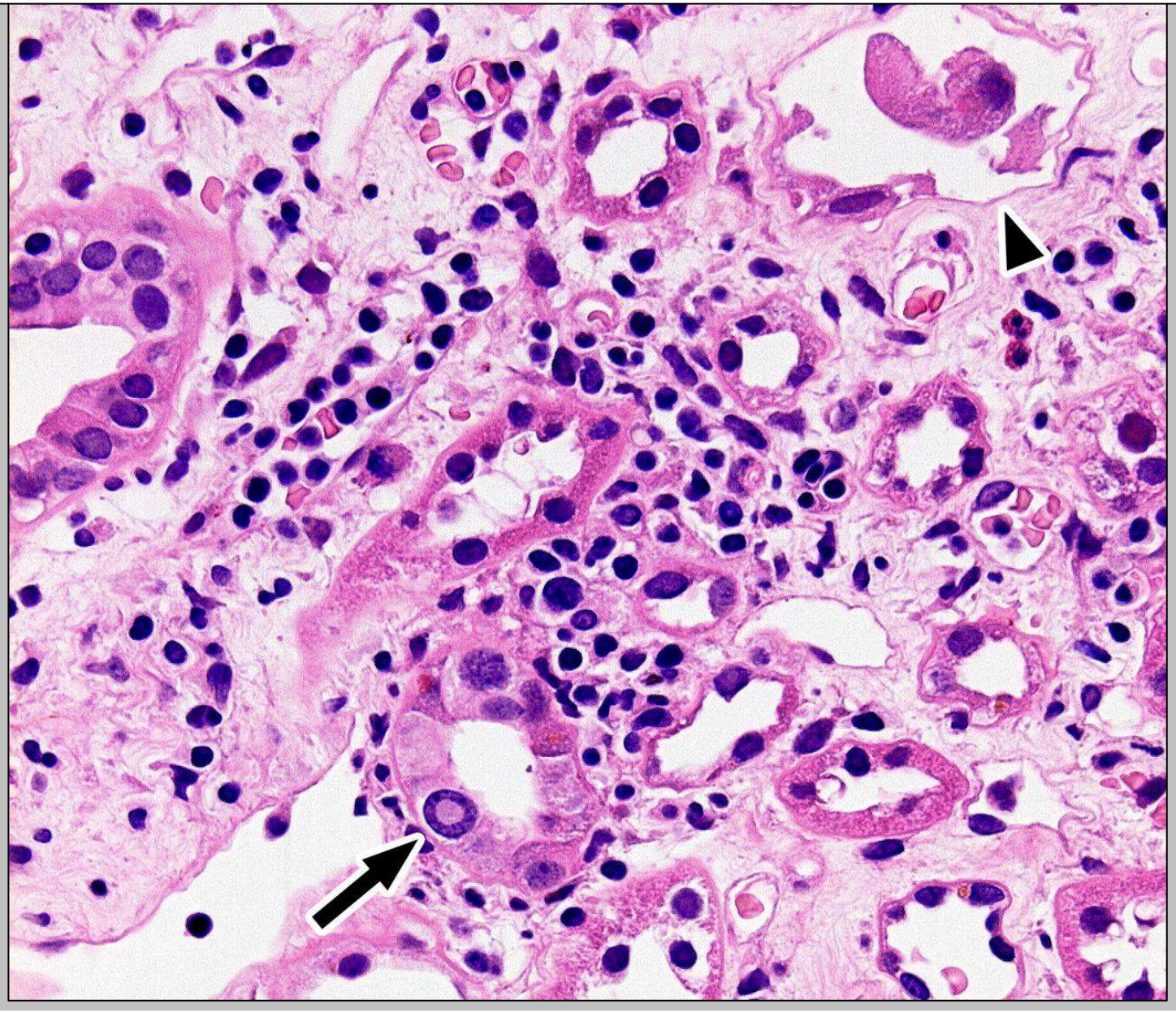

Immunostaining with SV40 large T-cell antigen confirms the diagnosis

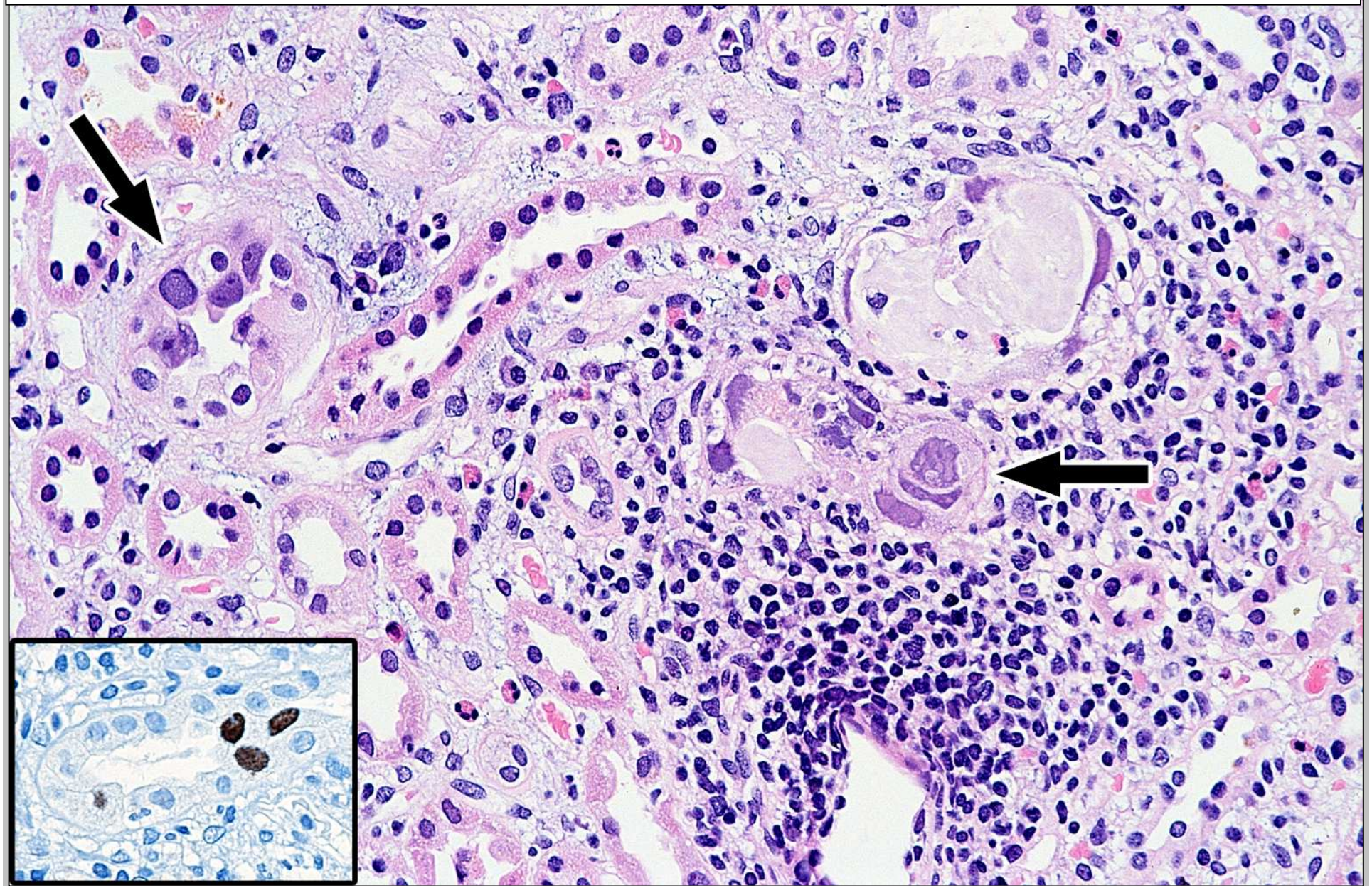

EM is also diagnostic: the virions are 40 nm in diameter, arranged in a paracrystalloid structure

Differential diagnosis

- **Other viral infections** (adenovirus: 70-90 nm; CMV: 100-110 nm)
- **Acute rejection** (lack of nuclear inclusion bodies, intense tubular HLA-DR expression)
- **Chronic rejection** (lack of nuclear inclusion bodies, negative confirmatory tests)

Liptak et al. Nature Clin Pract Nephrol 2:631-636, 2006

Histologic patterns and clinical stages of PVN

Pattern A

Viral cytopathic changes with no or only minimal inflammation

Early stage

- No dysfunction
- Urinary decoy cells
- Favorable prognosis

Hirsch et al. Transplantation 79:1277-1286, 2005

Histologic patterns and clinical stages of PVN

Pattern A

Viral cytopathic changes with no or only minimal inflammation

Pattern B

Cytopathic and cytolytic changes with interstitial inflammation

Early stage

- No dysfunction
- Urinary decoy cells
- Favorable prognosis

Fully developed stage

- A gradually decreasing renal function
- Graft loss can exceed 50%

Hirsch et al. Transplantation 79:1277-1286, 2005

Histologic patterns and clinical stages of PVN

Pattern A

Viral cytopathic changes with no or only minimal inflammation

Early stage

- No dysfunction
- Urinary decoy cells
- Favorable prognosis

Pattern B

Cytopathic and cytolytic changes with
IS inflammation

Fully developed stage

- A gradually decreasing renal function
- Graft loss can exceed 50%

Pattern C

IF/TA
Variable cytopathic and inflammatory changes

Late/sclerosing stage

- A severe dysfunction
- Graft loss is likely

Hirsch et al. Transplantation 79:1277-1286, 2005

Summary of acute lesions

T-cell-mediated rejection

- Peritubular capillaritis
- IS infiltrates rich in CTLs
- Lymphocytic tubulitis
- ± Intimal arteritis
- ± Glomerulitis

CNI toxicity

- Isometric vacuolation of tubules
- Early-stage hyalinization of individual myocytes in afferent arterioles

Alloantibody-mediated rejection

- C4d+ along PTCs
- Evidence of tissue injury:
  - arterial fibrinoid necrosis
  - microthrombi
  - neutrophilic capillaritis
  - ischemic tubular damage

Summary of chronic lesions

Rejection

- Arterial intimal fibrosis
- Double-contoured glomerular capillary loops
- PTC BM lamination
- IF/TA
- C4d+ along PTCs

CNI toxicity

- Hyaline arteriolopathy
- Patchy glomerular sclerosis
- Striped IF/TA

Ageing/hypertension

- Intimal fibroelastosis in arteries
- Nonspecific arteriolar hyalinosis
- Patchy glomerular sclerosis
- IF/TA

Polyomavirus NP

- Cytopathic effects (inclusion bodies and tubular epithelial injury)
- A varying degree of IS inflammation, IF/TA

Post-transplantation glomerulonephritis

- Recurrences of GN tend to occur in the first few weeks after Tx
- *De novo* GN usually manifests at least a year after Tx

Post-transplantation glomerulonephritis

- FSGS, MPGN, IgAN and idiopathic diarrhea-negative HUS recur fequently
- Membranous nephropathy, FSGS, anti-GBM nephritis in Alport patients, and drug-induced TMA are the most common *de novo* diseases
- Recurrent or *de novo* GN often coexists with acute and/or chronic rejection and/or chronic CNI- toxicity, and contribute together to allograft loss

Ivanyi B. Nature Clin Pract Nephrol 4:446-457, 2008

Recurrent FSGS

Proteinuria developed some days after the implantation.
1st Bx, EM: effacement of foot processes.
2. Bx (3 mo later). The FSGS lesion in two glomeruli

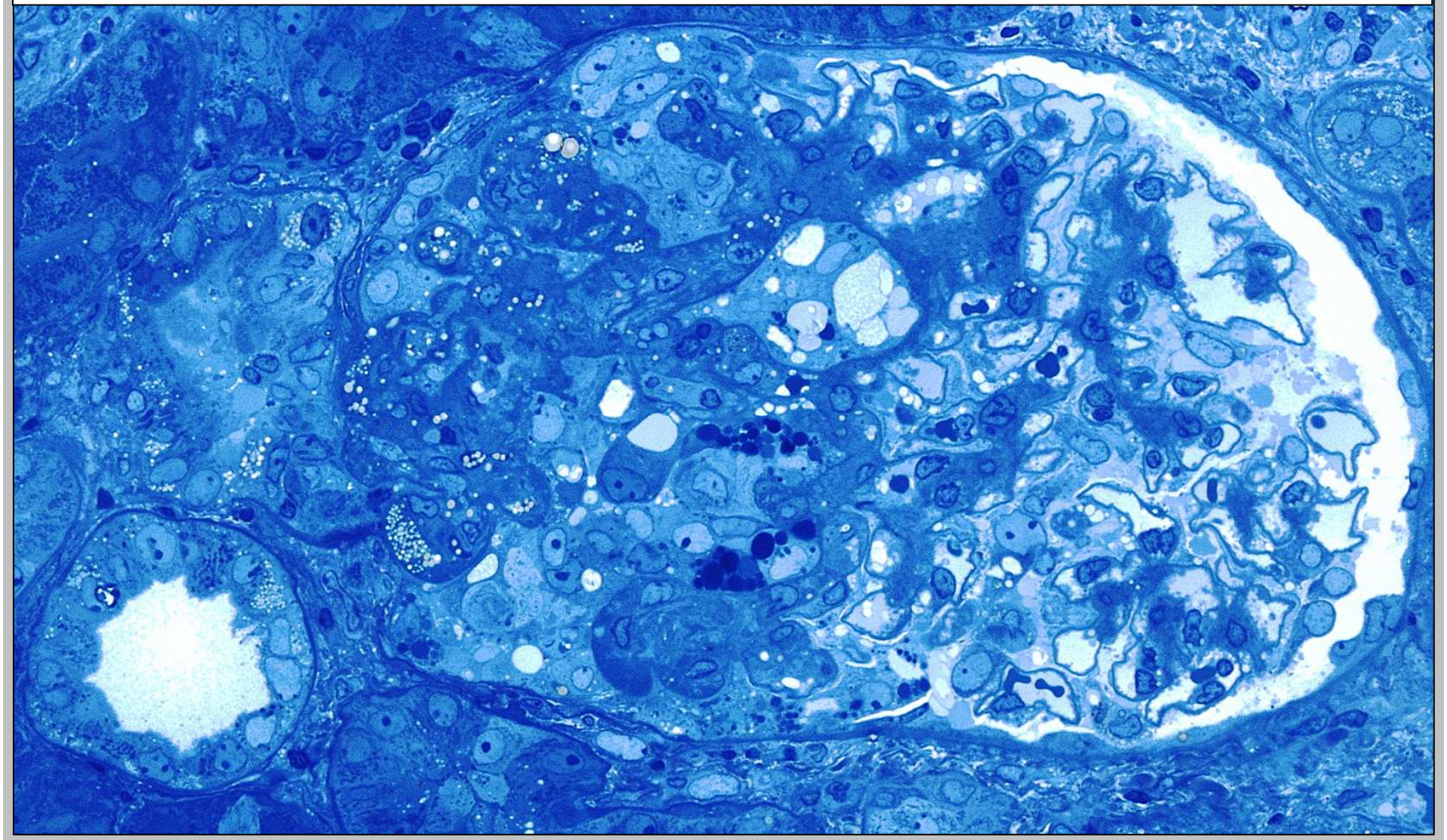

Coexistence of transplant GP and membranous NP

Bx performed because of nephrotic sy that developed 26 mo after Tx.

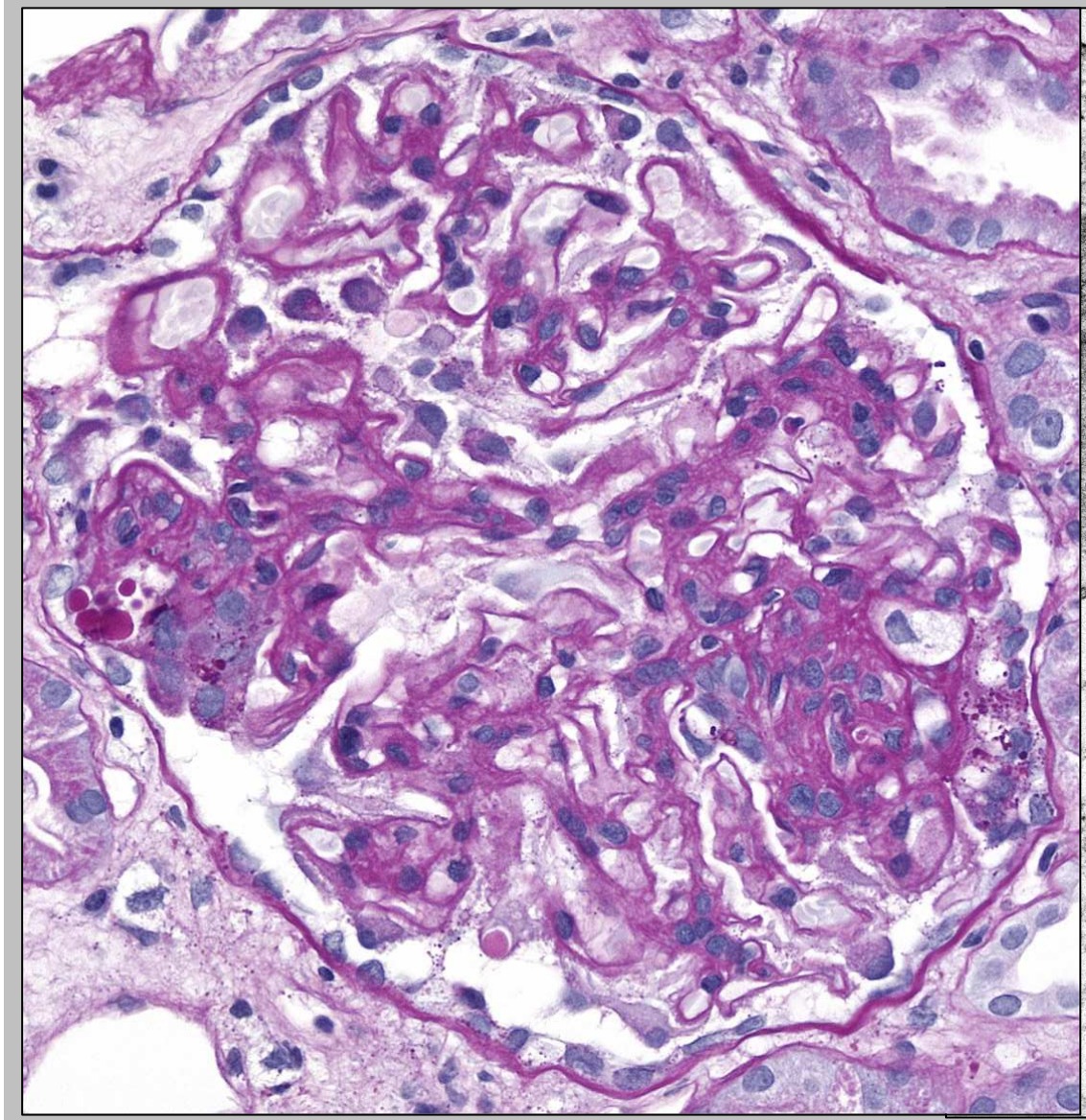

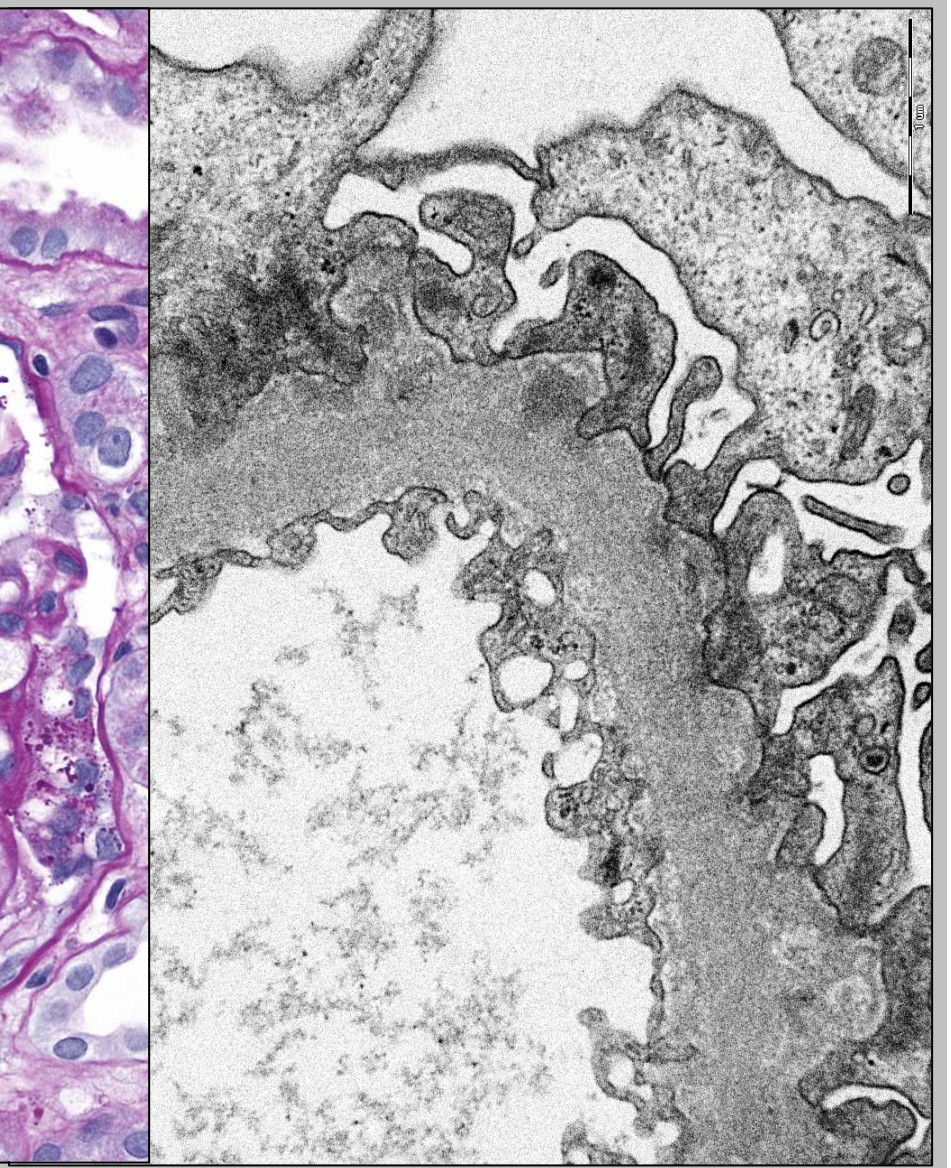

Kidney allograft from a deceased donor



~10 years later: end-stage allograft disease

Kidney allograft from a deceased donor

Early insults

Late insults

Additional insults

The insults cumulate: end-stage allograft disease

Nankivell BJ, Chapman JR. Transplantation 2006;81:643-654

Tx

Early insults

- Ischemia reperfusion injury
- Acute tubular necrosis
- Acute/subclinical rejection
- Acute CNI toxicity

Late insults

Additional insults

End-stage allograft disease

Tx

Early insults

- Ischemia reperfusion injury
- Acute tubular necrosis
- Acute/subclinical rejection
- Acute CNI toxicity

Late insults

- Chronic rejection
- Chronic CNI toxicity
- Polyomavirus NP
- Hypertension
- Recurrent/*de novo* glomerular disease

Additional insults

End-stage allograft disease

Tx

Early insults

- Ischemia reperfusion injury
- Acute tubular necrosis
- Acute/subclinical rejection
- Acute CNI toxicity

Late insults

- Chronic rejection
- Chronic CNI toxicity
- Polyomavirus NP
- Hypertension
- Recurrent/*de novo* glomerular disease

Additional insults

- Architectural degradation
- Cortical ischemia
- Persistent chronic inflamm.
- Accelerated ageing
- Cytokine excess
- Epithelial-mesenchymal transition and fibrosis

End-stage allograft disease

Renal allograft removed for end-stage kidney allograft failure

The kidney is shrunken, the cortex is no longer separated from the medulla, and the large arteries display severe atherosclerosis

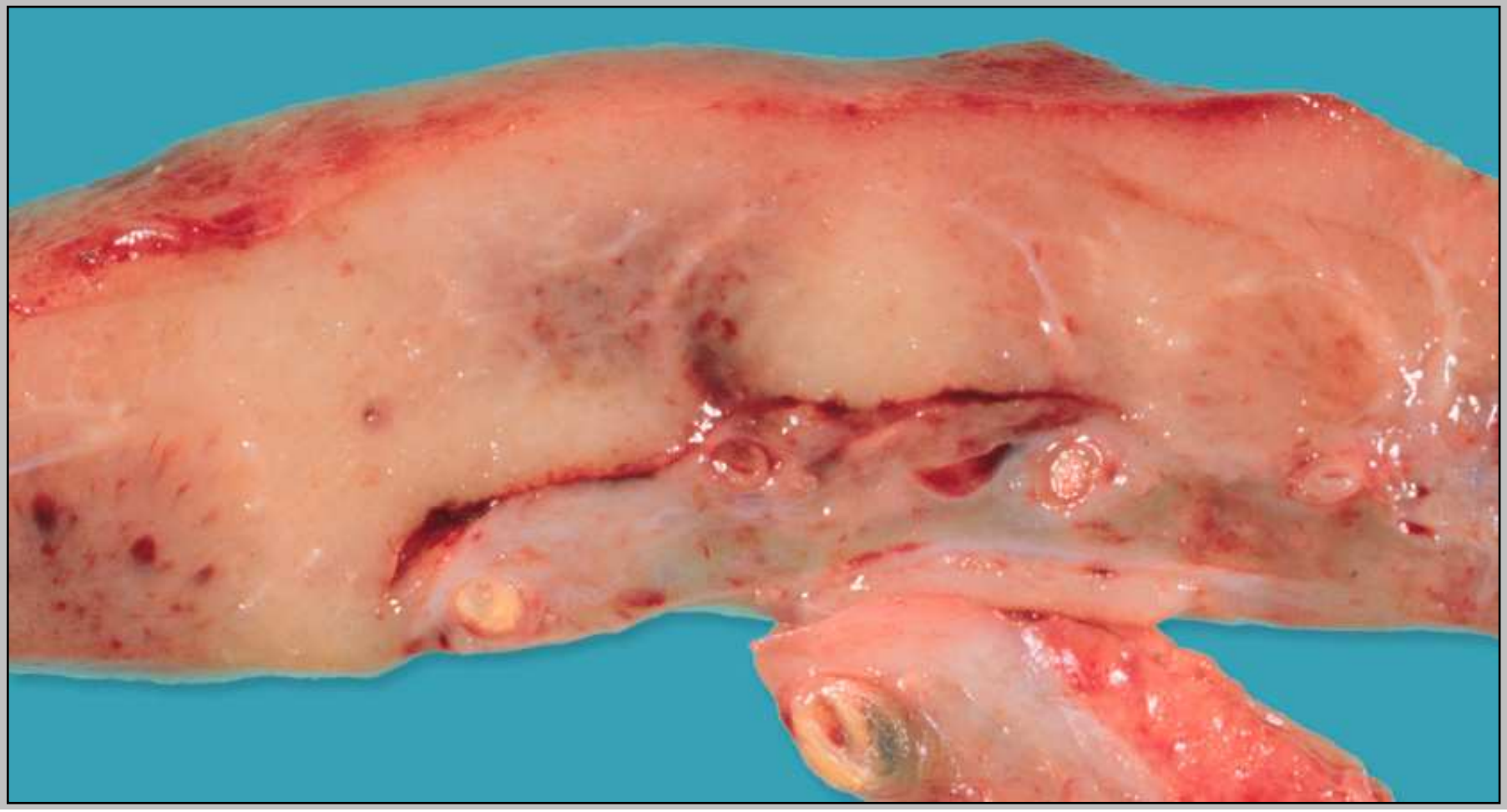

Conclusions

The application of

- light microscopic stainings on serial sections
- the full immunofluorescence panel (C4d, HLA-DR, IgG, IgA, IgM, C3)
- tissue sampling for optional EM
- comparison with a time-zero biopsy

enables the pathologist to achieve etiologic diagnoses