Budapest august 2012;
B Vervaet, P Dhaese, M De Broe ,Univ Antwerp
C Verkoelen (+) Erasmus Univ Rotterdam

Nephrolithiasis or kidney stone formation

- Common disorder in industrialized countries (10%)
  - Alterations in nutritional behaviour → excessive intake of meat
- Composition
  - Anorganic phase: calcium oxalate monohydrate (COM): 75%
  - Organic phase: proteins (OPN)
- Development
  - Crystallization as a result of supersaturation
  - Retention: crystal-cell interactions
- Defence mechanisms
  - Ca handling of the kidney
  - Urinary crystallization inhibitors (poly-anionic)
  - Non-adherent epithelium

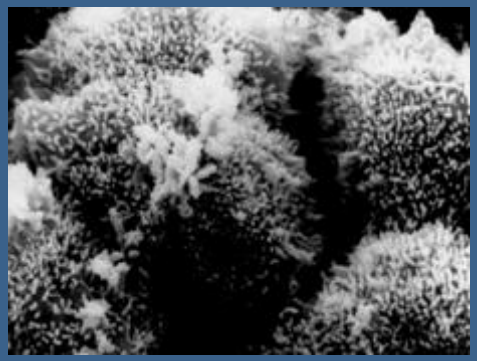



Diseases associated with calcium containing renal stones (nephrocalcinosis)

- Primary hyperparathyroidism 7.0%
- Idiopathic hyperalciuria 33.0%
- Hyperuricosuria 26.0%
- Renal tubular acidosis 3.4%
- Hyperoxaluria 4.6%
- Sarcoidosis
- Renal Transplantation 72.0%
- Dent's disease
  Bartter's syndrome
  Cystic fibrosis
- Post intestinal bypass surgery 78.0%
- Hypophosphataemia with nephrolithiasis
- Hypomagnesaemic hypercalciuric nephrocalcinosis
- Liddle's syndrome
- Lowe's syndrom
- X-linked hypophosphataemia SYMPTOM
- Williams' syndrome
- Wilson's disease

Nephrocalcinosis

Depending on technique: CT, ultrasound, X-ray, histology

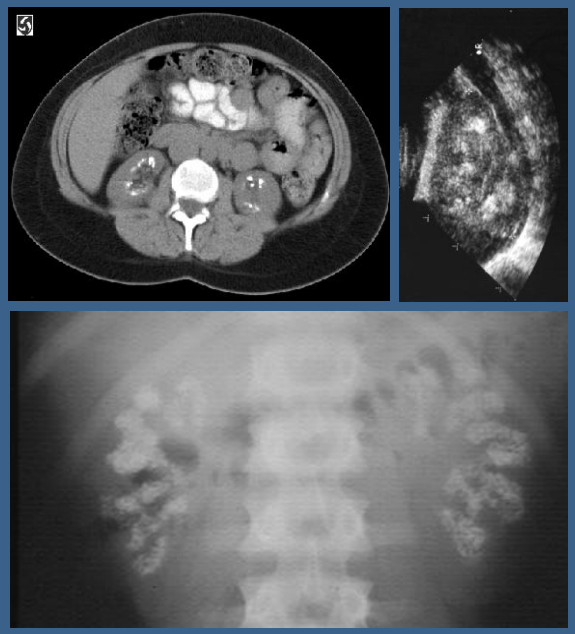

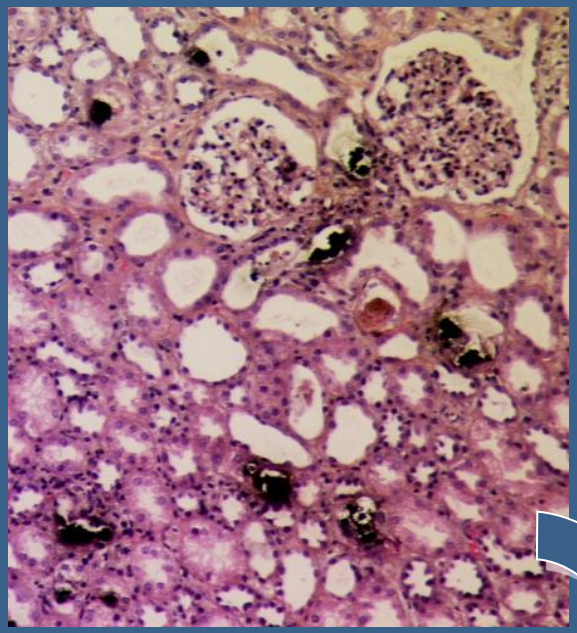

→ INTRATUBULAR NEPHROCALCINOSIS

'histological observation of calcium oxalate or calcium phosphate crystals retained within the tubules of the kidney'

Primary human tubular cell cultures

Cell culture system

Helbert et al. Kidney Int 59:554-561, 2001
Helbert et al. Kidney Int 52:414-428, 1997

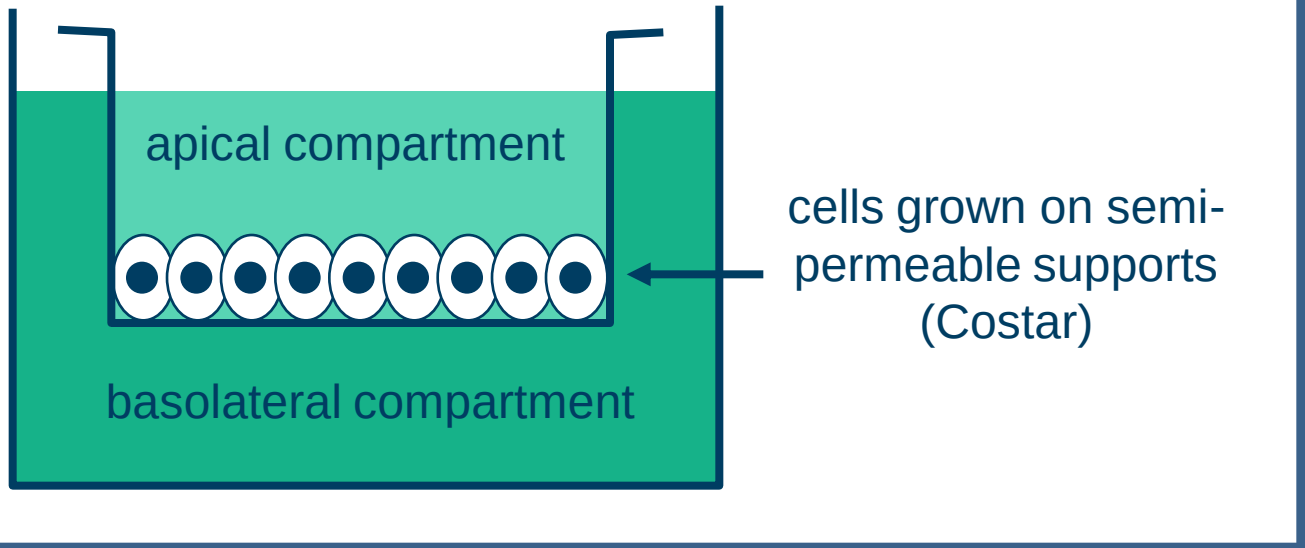

Semi-permeable support

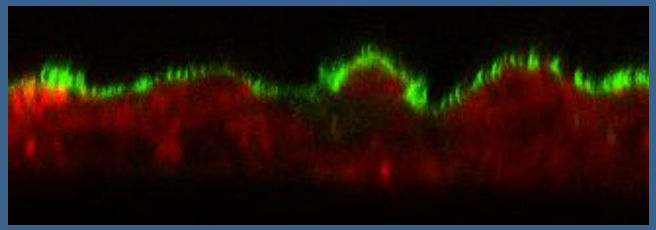

Transepithelial resistance

Well plate

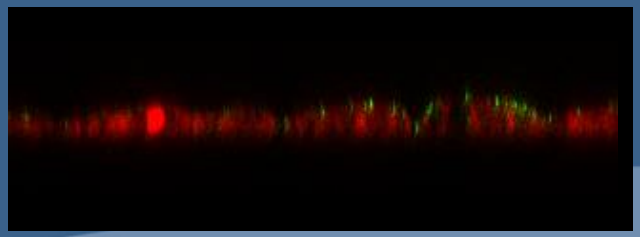

INITIATION

Fixed particle mechanism:

'*Crystals are retained by adhesion to the tubular epithelium*'

***Finlayson & Reid**, Invest Urol 1978; 15:442-448*
***Kok & Khan**, Kidney Int 1994; 46:847-854*
***Robertson**, Nephron Physiol 2004; 98:21-30*

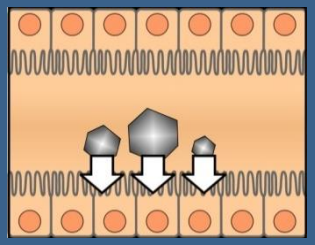

Phenotypical characteristics of the crystal binding epithelium?

- General cellular phenotype → DEDIFFERENTIATED

2. Subconfluent primary human cell cultures bind crystals

Number of cells

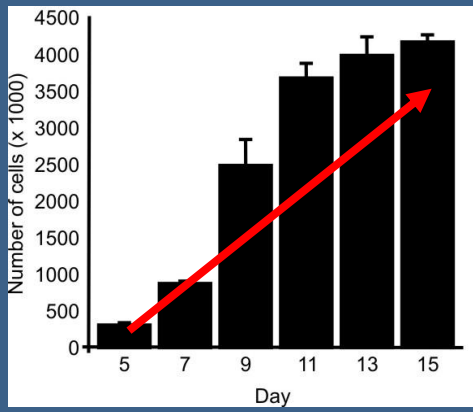

Transepithelial resistance

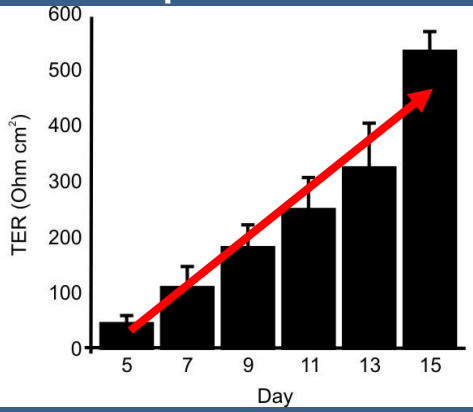

Crystal adherence

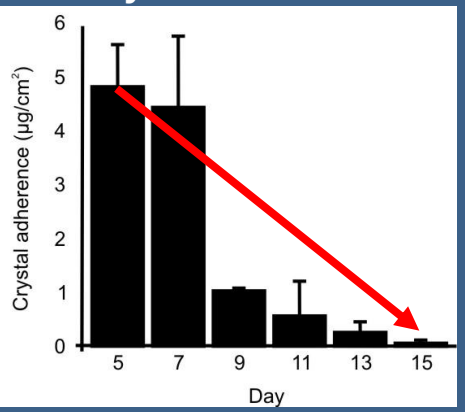

Subconfluent → confluent

Verhulst et al, J Am Soc Nephrol. 2003;14(1):107-15

INITIATION

Fixed particle mechanism:

'*Crystals are retained by adhesion to the tubular epithelium*'

Finlayson & Reid, *Invest Urol 1978; 15:442-448*
Kok & Khan, *Kidney Int 1994; 46:847-854*
Robertson, *Nephron Physiol 2004; 98:21-30*

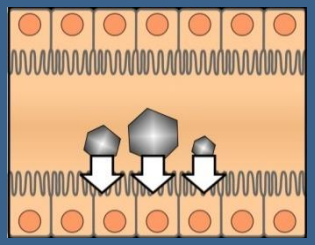

Phenotypical characteristics of the crystal binding epithelium?

- Luminal membrane phenotype → CRYSTAL BINDING MOLECULES

Phospholipids: phosphatidylserine

Proteins: - collagen IV
- osteopontin
- nucleolin related protein
- annexin 2

Glycocalix: Sialic acid residues
Glycosaminoglycans: hyaluronan

Bigelow et al. J Urol 1996; 155:1094-1098
Bigelow et al. Am J Physiol 1997; 272:F55-F62
Wiessner et al. Kidney Int 2001; 59:637-644
Kohri et al. Eur Urol 1991; 19:249-252
Yamate et al. Eur Urol 1996; 30:388-393
Yamate et al. Urol Int 1999; 62:81-86
Yamate et al. J Urol 1998; 160:1506-1512
Sorokina et al. J Biol Chem 1999; 62:81-86
Sorokina et al. J Am Soc Nephrol 2004; 15:2057-2065
Kumar et al, J Am Soc Nephrol. 2003;14(2):289-97
Carr et al, Cell Mol Life Sci 2006; 63:367-377
Lieske et al, Am J Physiol 1996; 270:F192-F199
Lieske et al, Am J Physiol 1997; 273:F224-F233
Verkoelen et al, Kidney Int 2000; 58:1045-1054

→NOT ON NORMAL LUMINAL MEMBRANE
→NO UNIVERSAL CRYSTAL BINDING MOLECULE
→NEGATIVE CHARGE

OPN, CD44 and hyaluronan expression

OPN

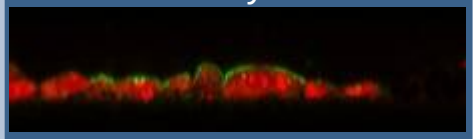

Day 5

OPN (green)
+ cell staining (red)

Day 5

Day 9

OPN (red)

CD44

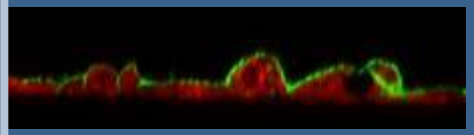

Day 5

CD44 (green)
+ cell staining (red)

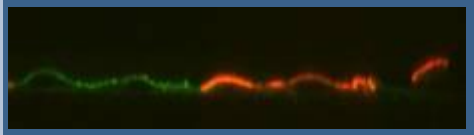

Day 5

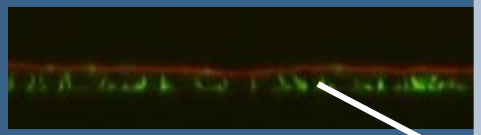

Day 9

CD44 (green) / EMA (red)

Baso-
lateral

Hyaluronan

Confocal
microscopy of
localization of
HA and CD44

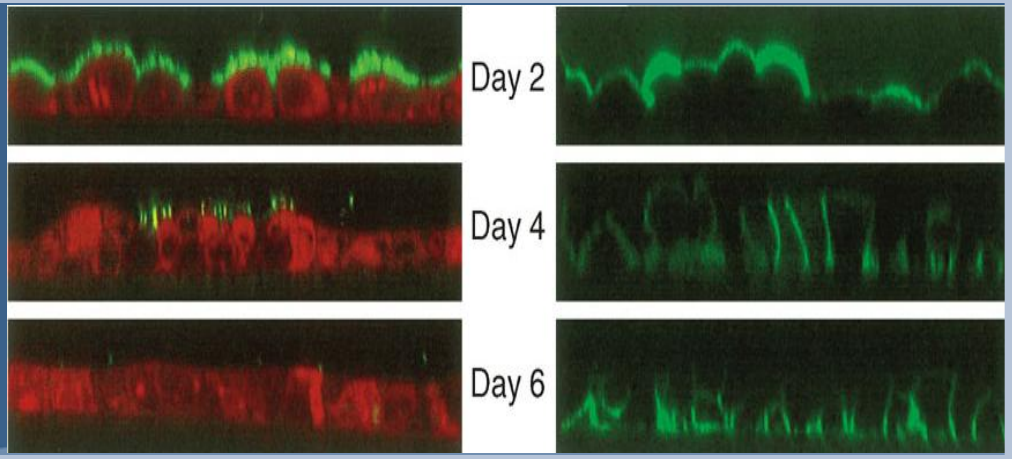

Verhulst A. et al. J Am Soc Nephrol 13:1210-1218, 2002

Hyaluronan ,glycosaminoglycan (GAG) composed of repeating disachacharide units

Support,migration,proliferation differentiation,interst. fluid,

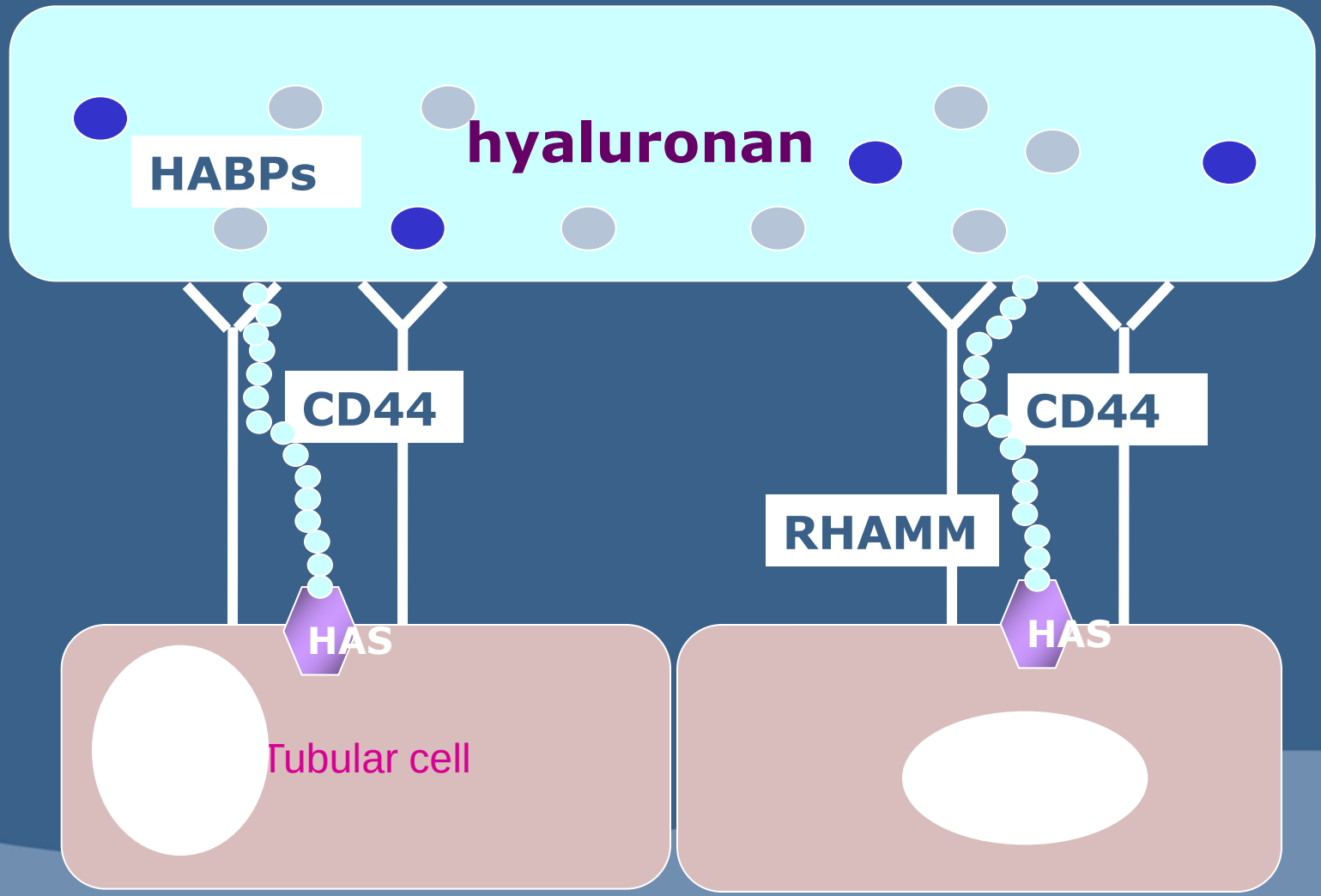

Localisation in the kidney

Hyaluronan is apically secreted and expressed by proliferating or regenerating renal tubular cells

Production of high Mr glycoconjugates by Madin-Darby canine kidney strain I (MDCK-I) cells cultured on permeable supports in a two-compartment culture system, and analyzed by metabolic labeling studies using [^{3}H] glucosamine in combination with specific enzyme digestion and Sephacryl S-1000 size exclusion chromatography

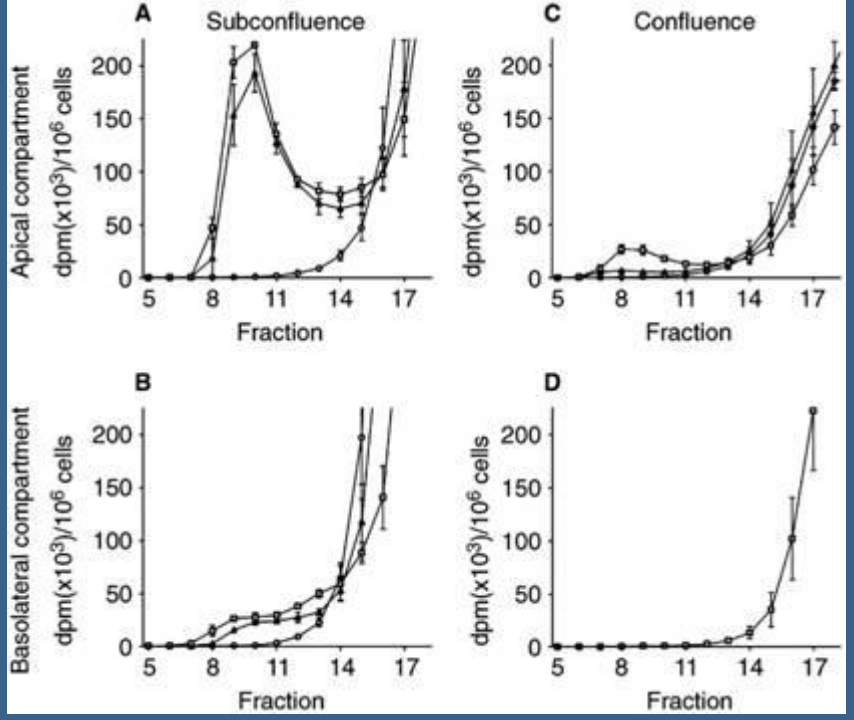

Confocal microscopy images of the membrane localization of hyaluronan (A) and C44 (B)

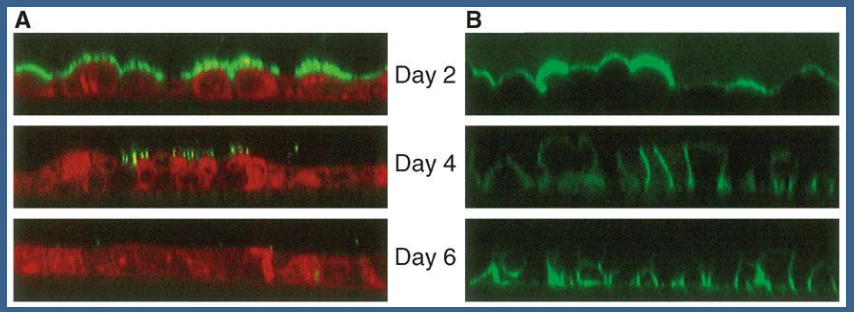

Hyaluronan staining in the cortex of a renal tissue biopsy specimen of a patient suffering from acute tubular necrosis, showing expression of hyaluronan at the luminal membrane of tubular cells and also in the cortical interstitium

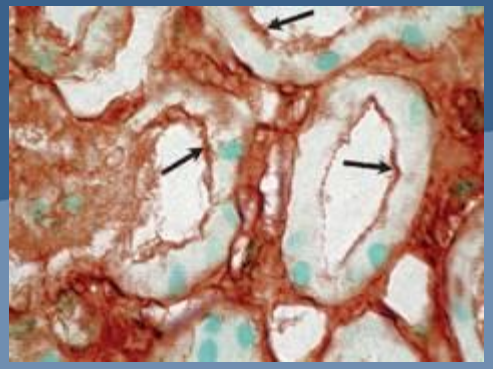

Asselman M et al: Kidney Int 68: 71-83, 2005
Verhulst A et al: JASN 13: 1210-18, 2002

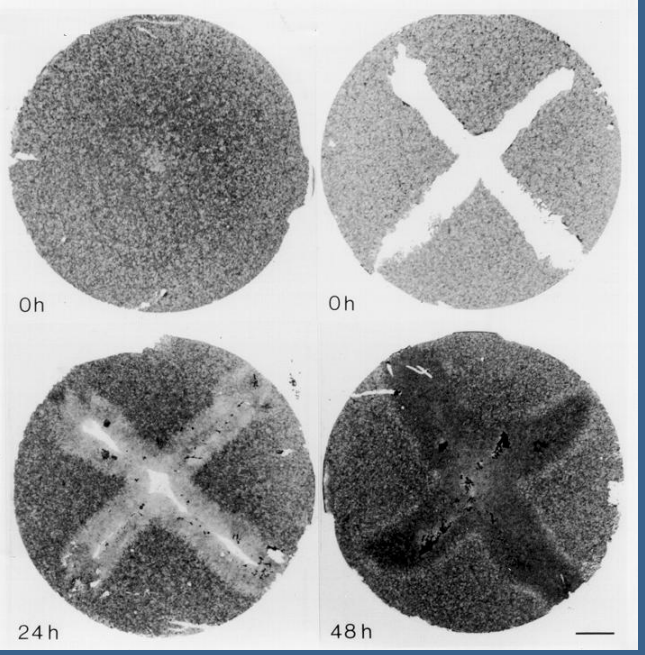

Injury and repair (MDCK cells)
Crystal binding

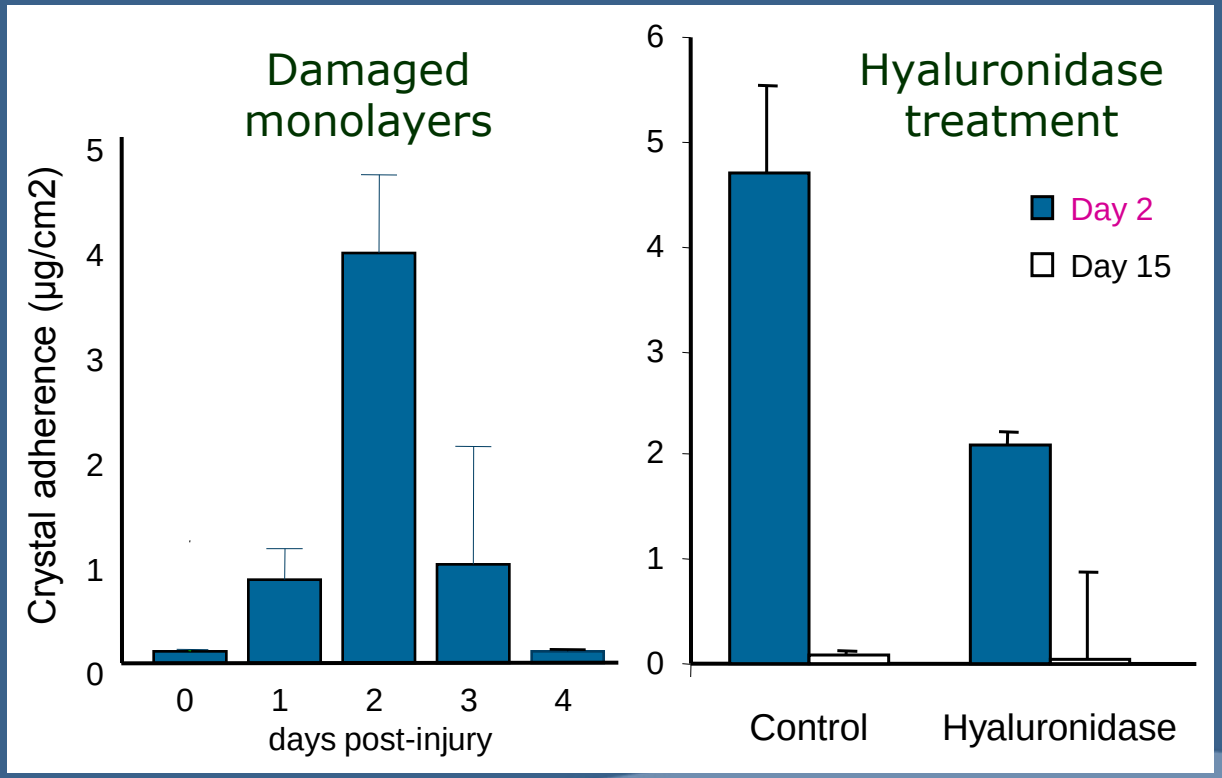

Verkoelen C et al. Kidney Int 1995, 48: 129-138

Crystal retention capacity of the renal epithelium

Cell Culture rat and man

- Intact epithelium is not susceptible to crystal-cell interactions
- Crystal-cell interactions occur in damaged regenerating cell layers
- Expression of proteins/molecules with crystal binding properties
  - Osteopontin
  - Hyaluronic acid ,and their receptor CD44
  - Annexin II
  - Nucleolin related protein (acidic peptide sequence)

Crystalluria

IN VIVO
Rats treated with
Ethylene glycol

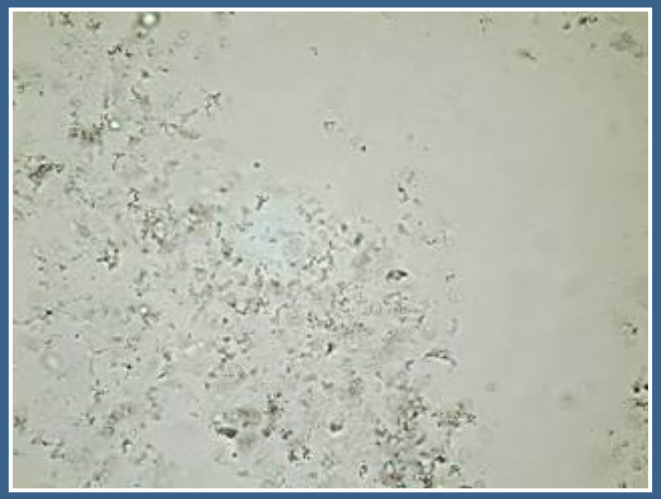



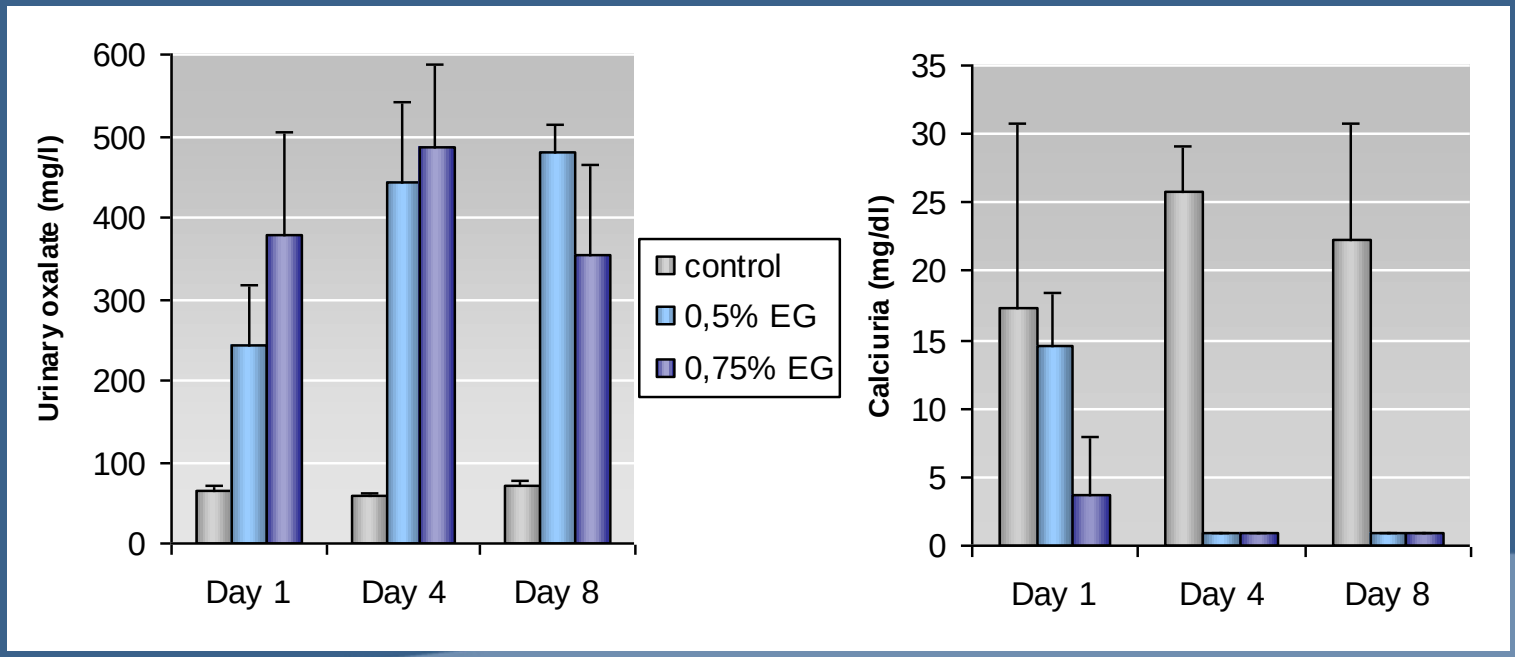

Asselman M, Verhulst A et al: JASN 14: 3155-3166, 2003

Renal damage and regeneration after ethylene glycol

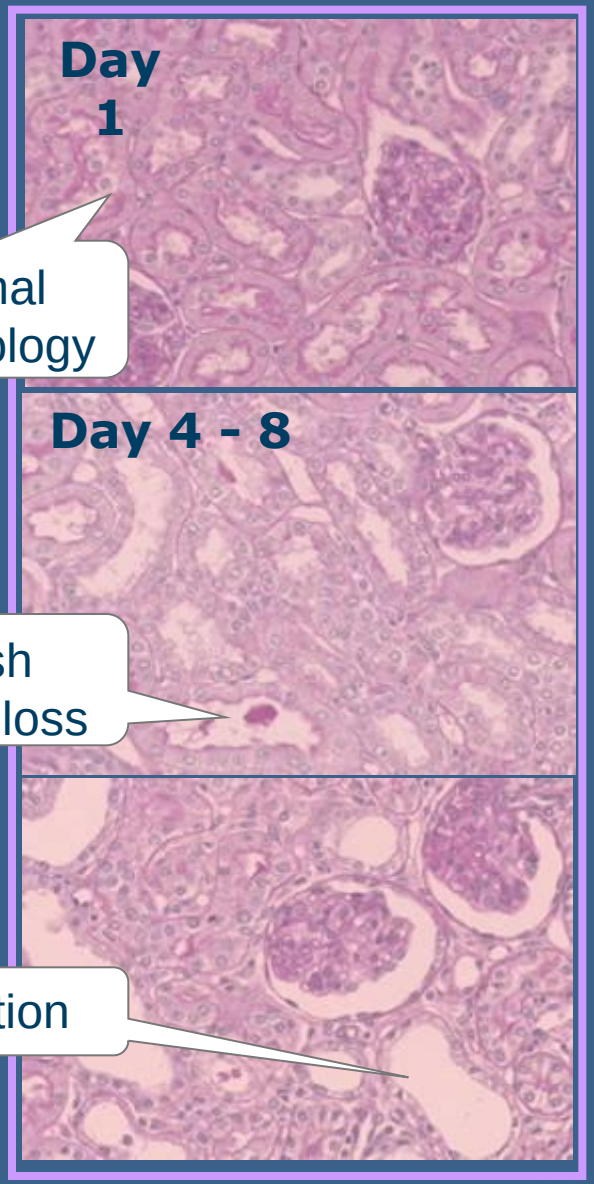

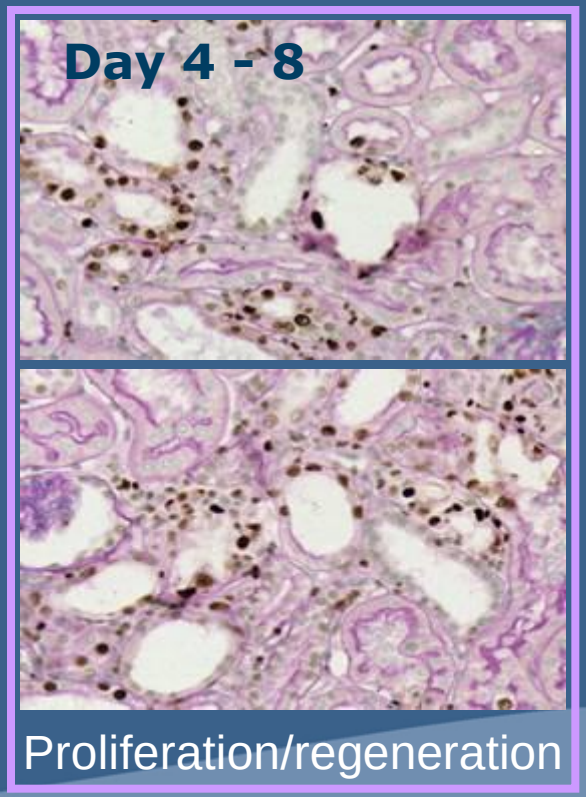

Asselman M, Verhulst A et al: JASN 14: 3155-3166, 2003

Crystal retention

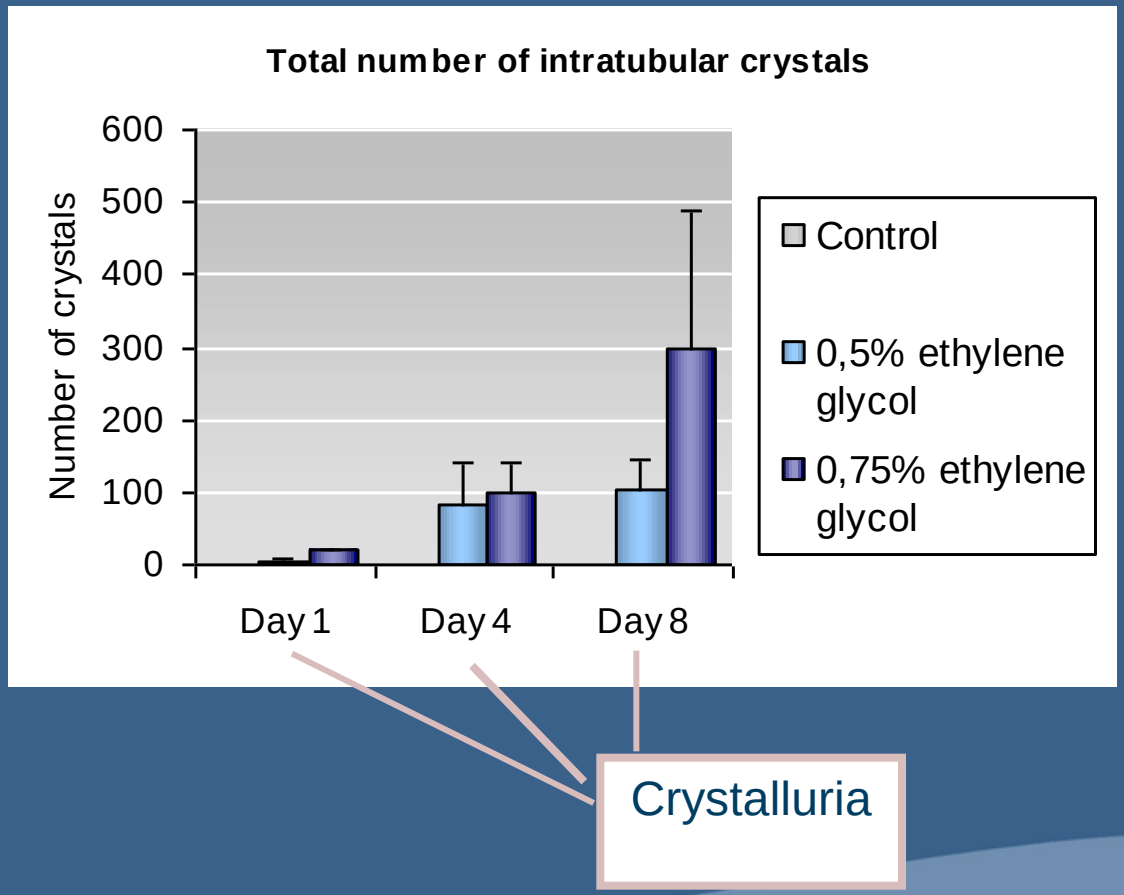

Asselman M, Verhulst A et al: JASN 14: 3155-3166, 2003

Crystal retention

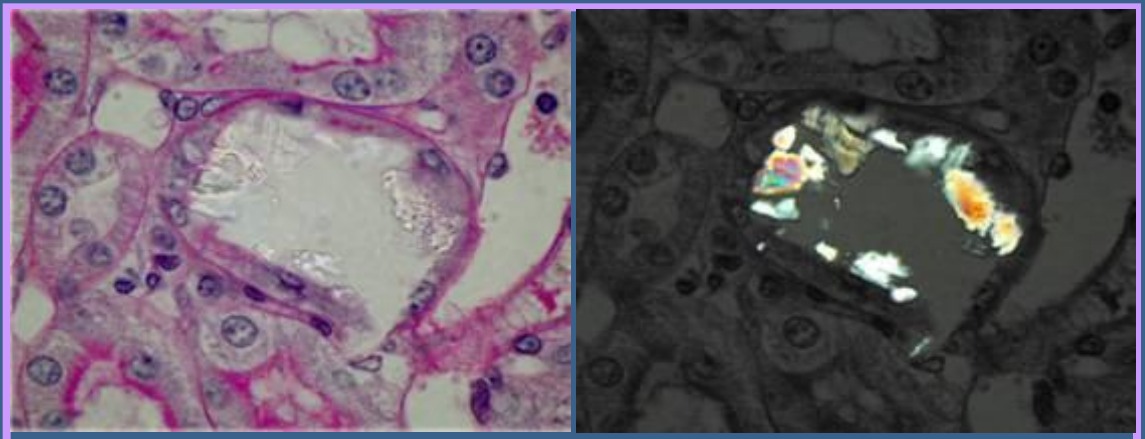

Crystal adhesion to flattened cells

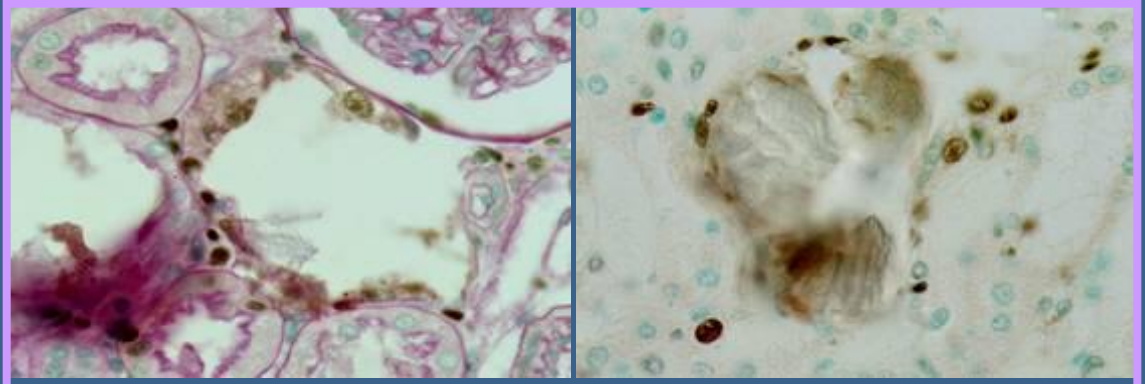

Crystal adhesion to flattened, regenerating cells

Asselman M, Verhulst A et al: JASN 14: 3155-3166, 2003

Crystal adhesion to OPN, HA and CD44 expressing tubules, regenerating/ dedifferentiated cells

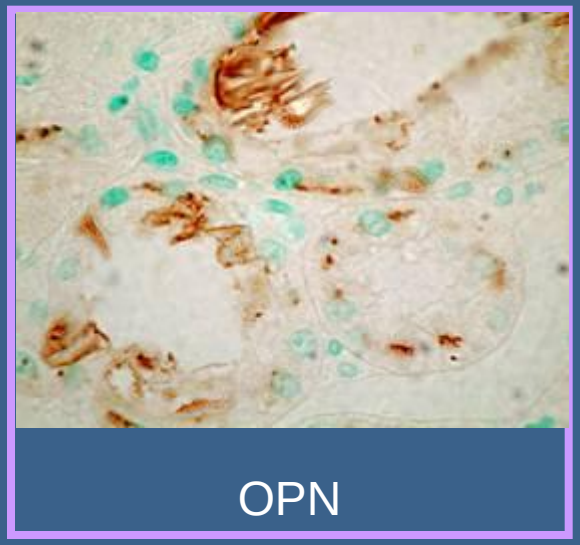

OPN

HA

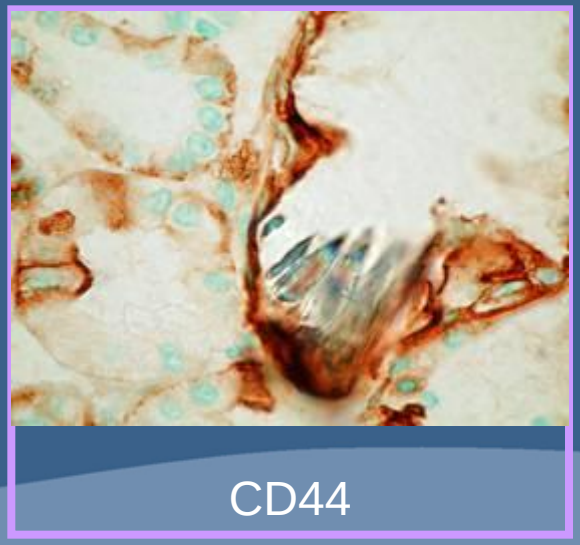

CD44

Asselman M, Verhulst A et al: JASN 14: 3155-3166, 2003

Diseases associated with calcium containing renal stones (nephrocalcinosis)

• Primary hyperparathyroidism	7.0%
• Idiopathic hyperalciuria	33.0%
• Hyperuricosuria	26.0%
• Renal tubular acidosis	3.4%
• Hyperoxaluria	4.6%
• Sarcoidosis	
• Renal Transplantation	72.0%
• Dent's disease Bartter's syndrome Cystic fibrosis	
• Post intestinal bypass surgery	78.0%

OPN- and HA-expression (serial sections, 1000x)

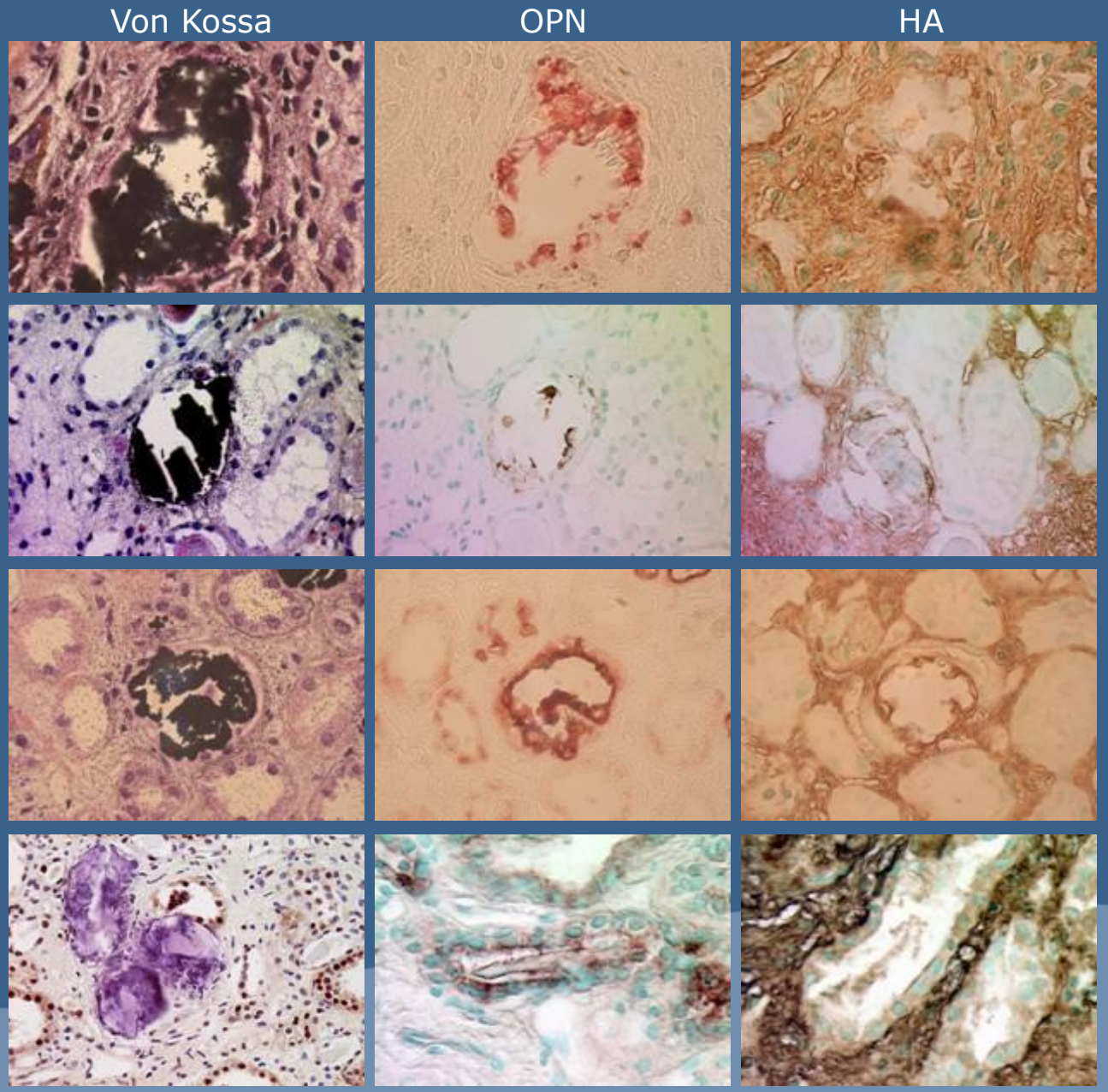

Expression of OPN and HA in foetal kidneys

- Up to 70 % of premature born infants suffer from postnatal renal calcifications
- Expression of HA and OPN in foetal kidneys

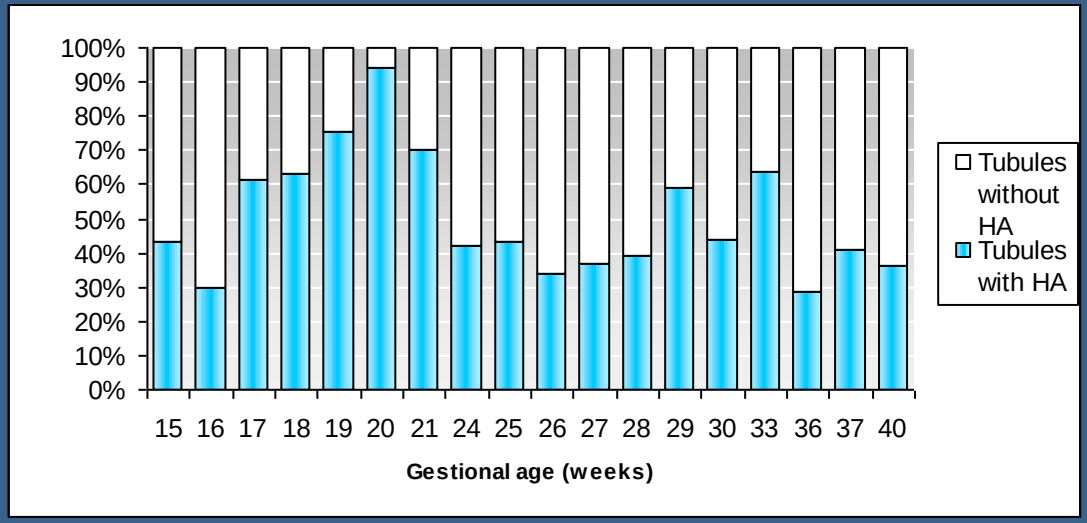

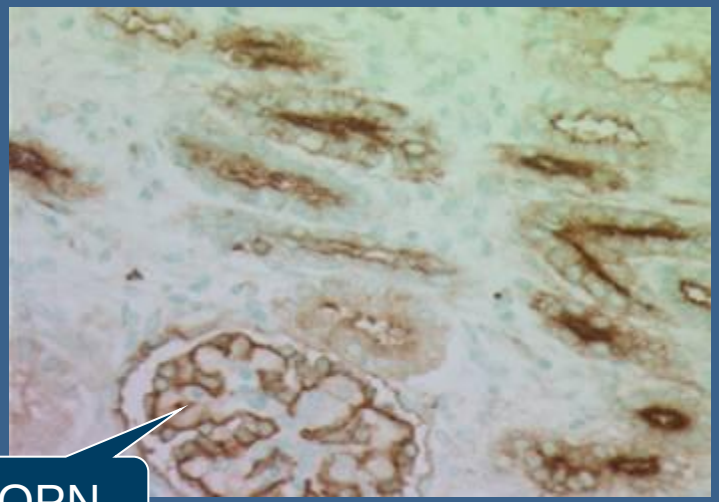

OPN

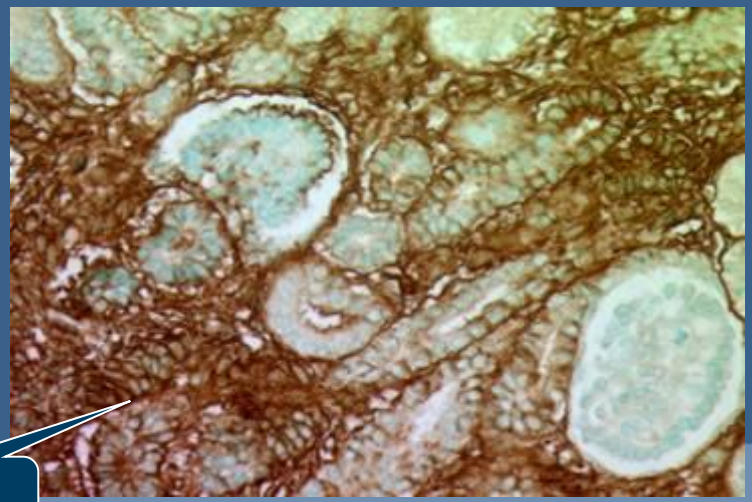

HA

See also: Kist-Van Holthe JE et al: Pediatrics 119: 468-475, 2007

Is nephrocalcinosis in preterms harmful for long term blood pressure and renal function?

Risk factors for chronic allograft nephropathy after renal transplantation: a protocol biopsy study

- Nephrocalcinosis increased from the first biopsy (6%) to the 2nd biopsy (12%), reaching 18% in the 3rd biopsy ($p < 0.05$).
- Calcium deposits localized in the tubular lumen atached to tubular cells

Schwarz A et al

The natural history of chronic allograft nephropathy

Nankivell BJ et al: New Engl J Med 349: 2326-33, 2003

Table 2. Cumulative Kaplan–Meier Estimates of the Prevalence of Histologic Diagnoses, According to the Time after Transplantation.

Histologic Diagnosis	1 Yr	5 Yr	10 Yr
		percent	
Chronic allograft nephropathy			
Banff grade I	94.2	100.0	100.0
Banff grade II or III	24.7	65.9	89.8
Calcineurin-inhibitor nephrotoxicity	76.4	93.5	96.8
Arteriolar hyalinosis	62.0	90.3	100.0
Striped fibrosis	33.2	68.3	87.3
Tubular microcalcification	42.7	67.2	78.5

Pinheiro HS et al: Am J Transplant 5: 323-329, 2005

(serial sections, 300x)

Transplanted kidneys

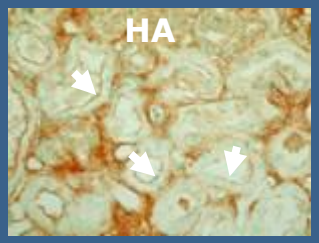

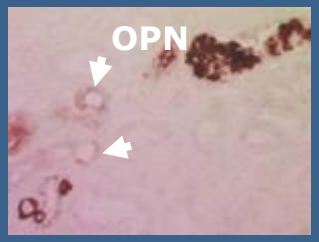

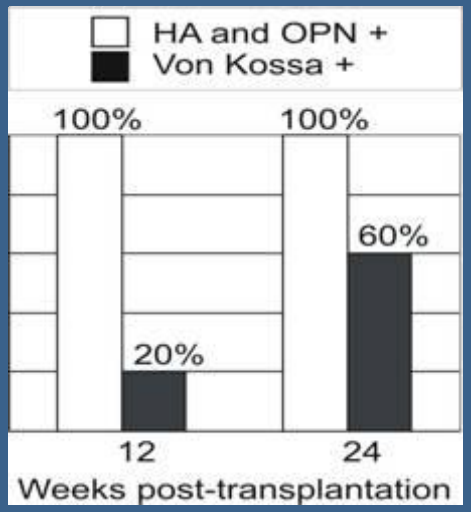

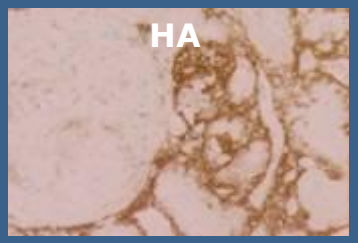

Preterm neonates (week 15-40)

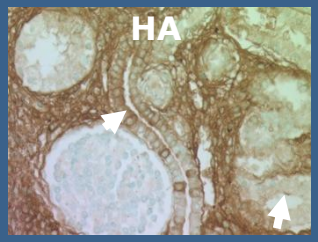

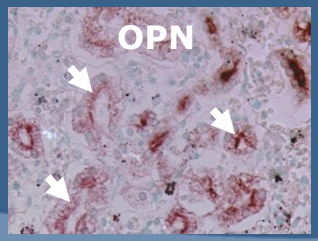

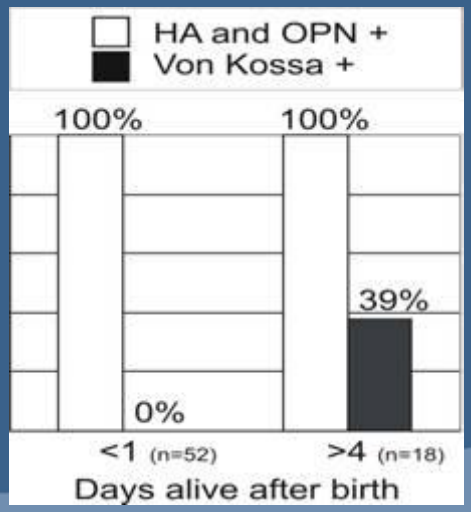

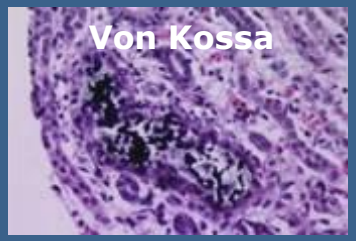

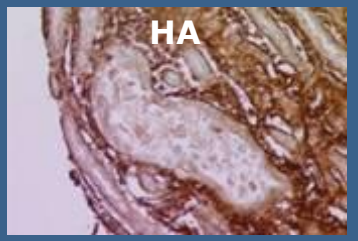



Preconditioning of the distal tubular epithelium of the human kidney **precedes** nephrocalcinosis

Pinheiro et al ..

Early presence of Ca oxalate deposition in kidney graft biopsies is associated with poor long term graft survival
Am. J. Transplant. 5/ 323 /2005

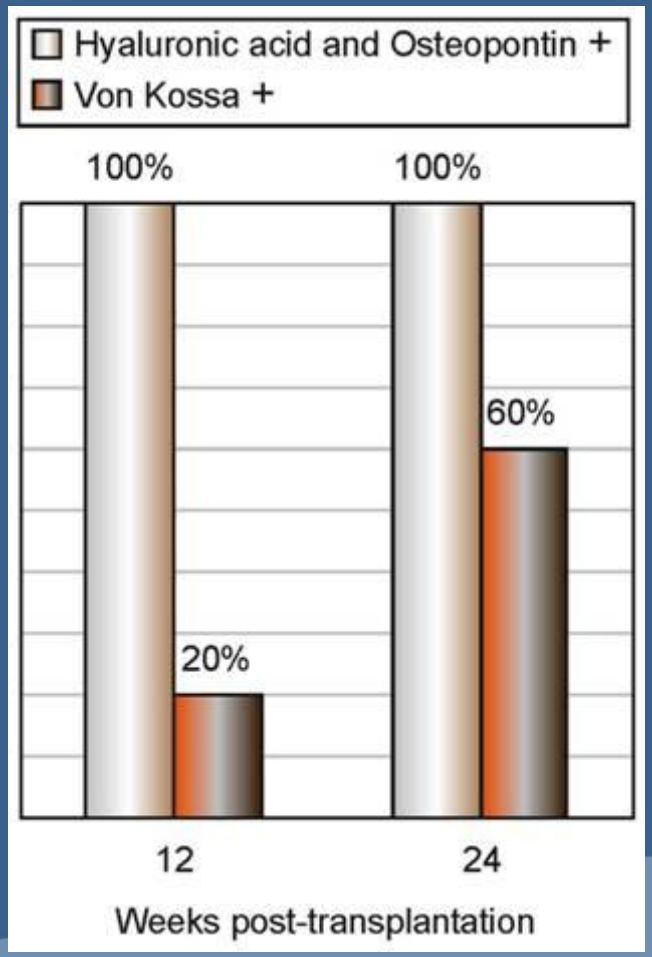

Verhulst A et al: Kidney Int 68: 1643-7, 2005

Summary

- Kidneys of patients with Primary hyperoxaluria,
  Dent's disease
  Acute phosphate nephropathy
  Sarcoidosis
  … express OPN and HA at the luminal side of the tubular epithelium (either with or without crystals).

  → injury/regeneration

- Crystal deposition (calcium oxalate and phosphate) is **confined** to tubules with this modified epithelial phenotype

Our observations in vitro, in vivo (rat) and in the human kidney are all consistent showing that phenotypic changes of the tubular epithelium **precede**, hence represent the first step in, crystal adhesion

Crystal retention before and after ethylene glycol treatment
Fate of crystals

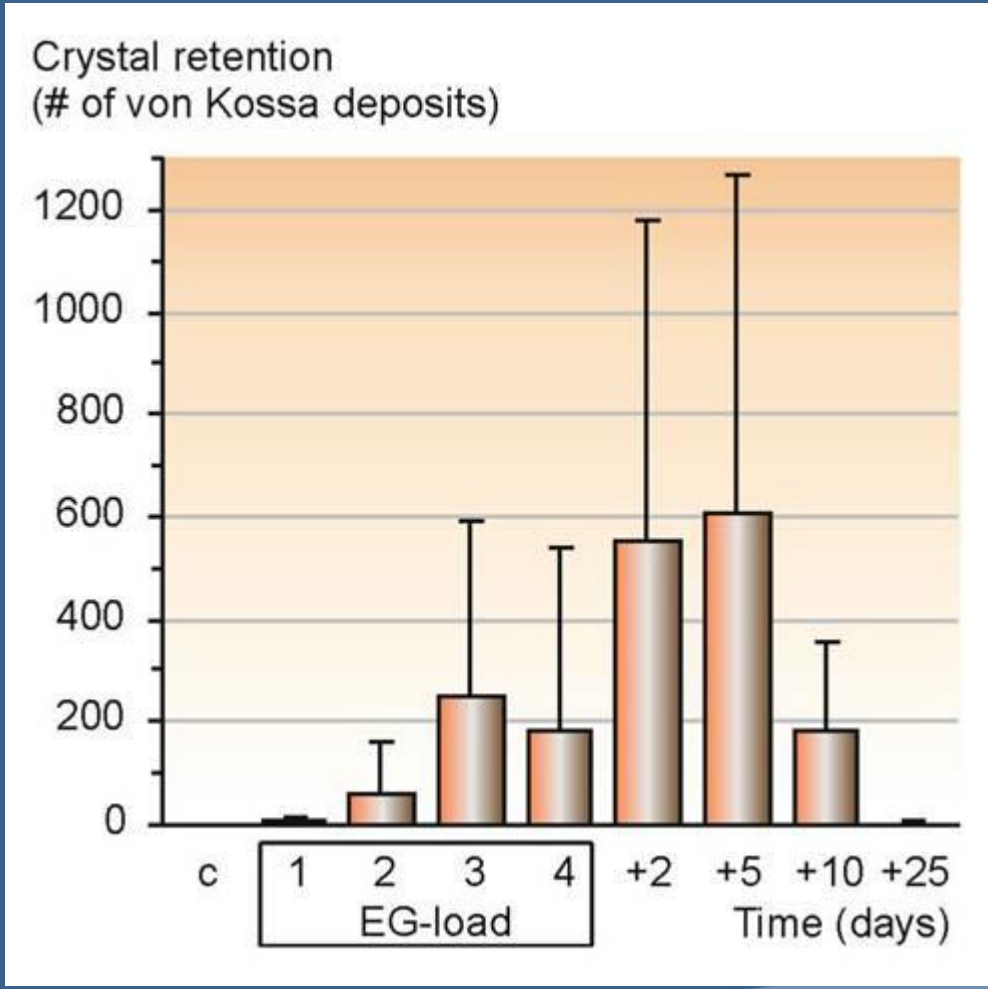

NON ADHERENT and ADHERENT CRYSTALS

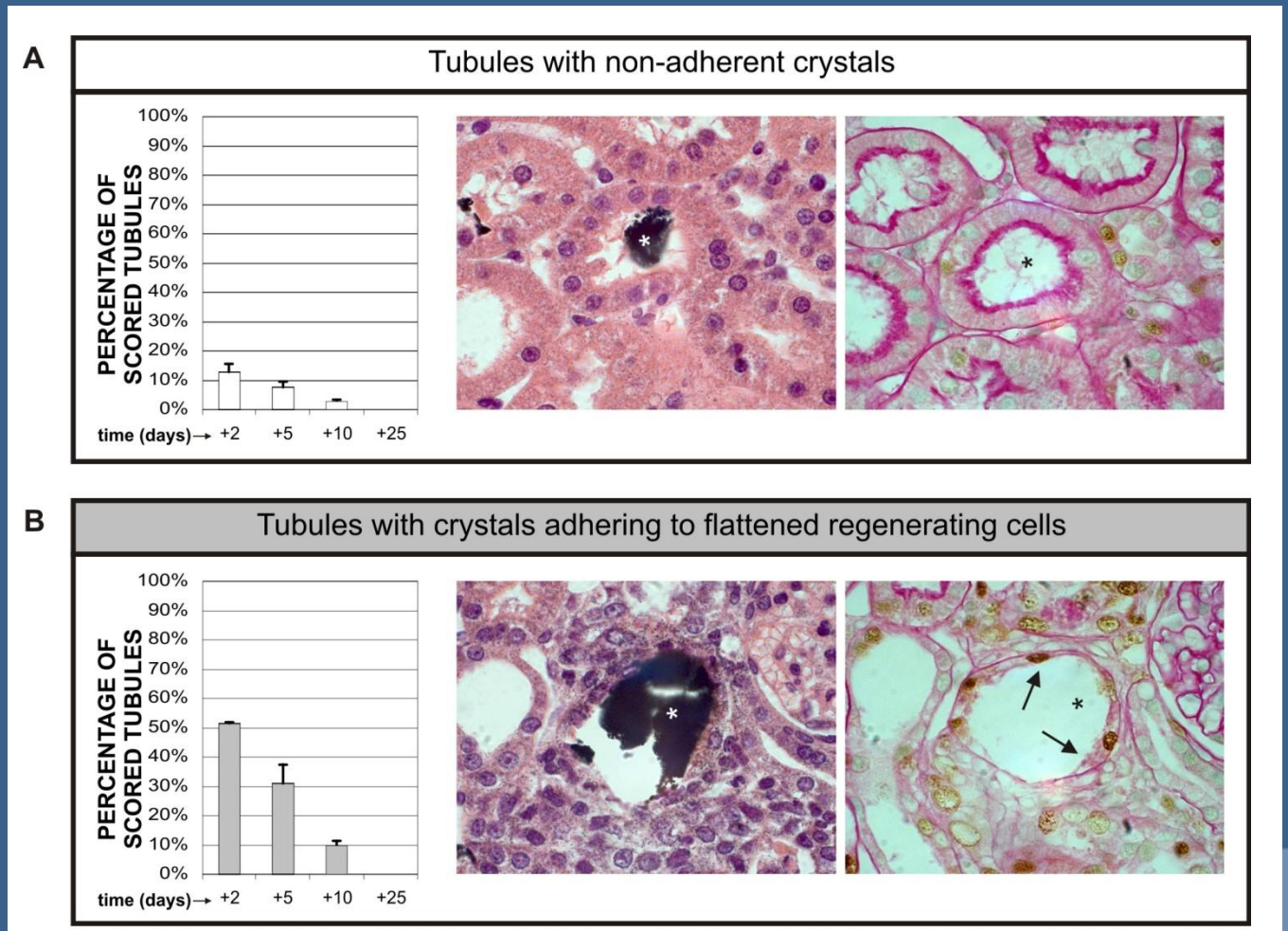

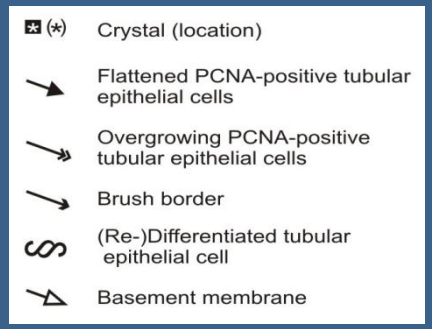

Vervaet B.Kidn. Intern. et al 2008

The tubular epithelium and intratubular nephrocalcinosis: Morphology of crystal containing tubules (qualitative)

Normal tubules

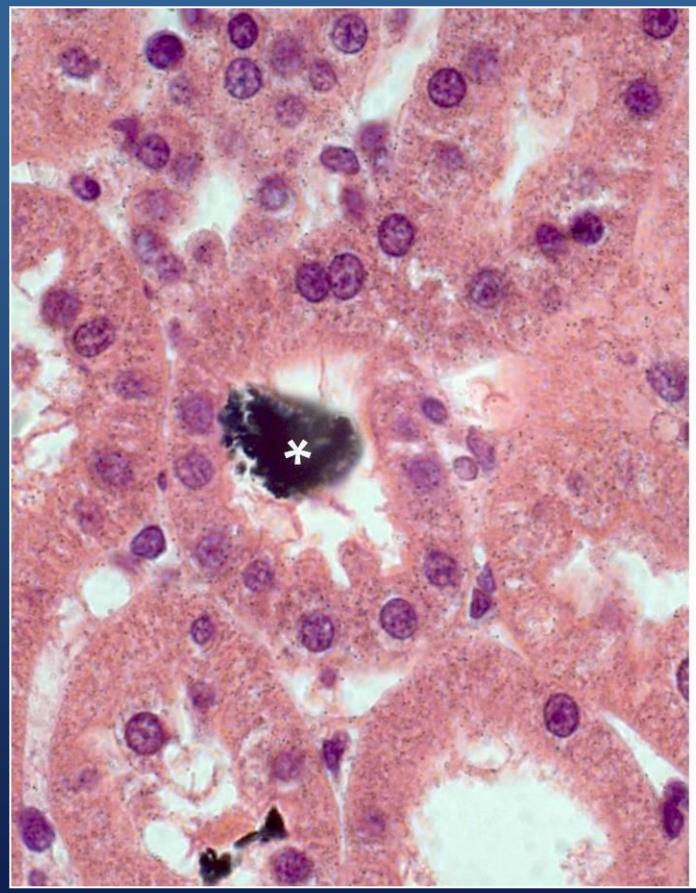

Von Kossa

PAS/PCNA

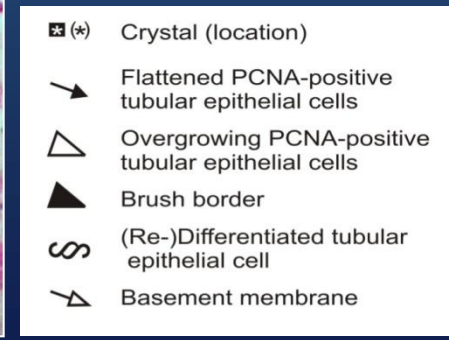

B. Vervaet et al

The tubular epithelium and intratubular nephrocalcinosis: Morphology of crystal containing tubules (qualitative)

Tubules with dedifferentiated cells

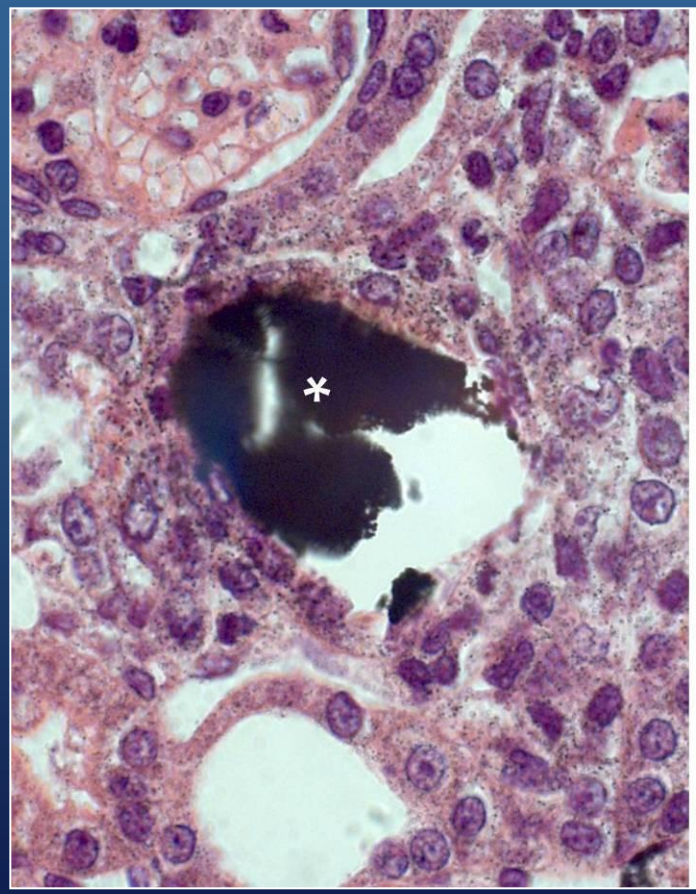

Von Kossa

PAS/PCNA

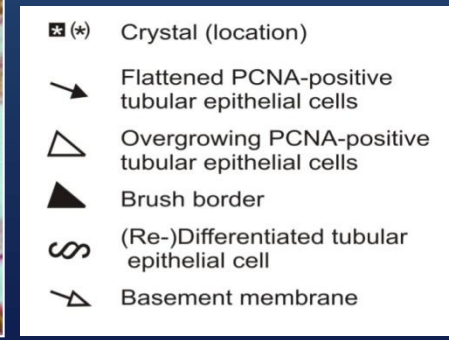

B. Vervaet et al

CRYSTAL OVERGROWTH / ENGULFMENT

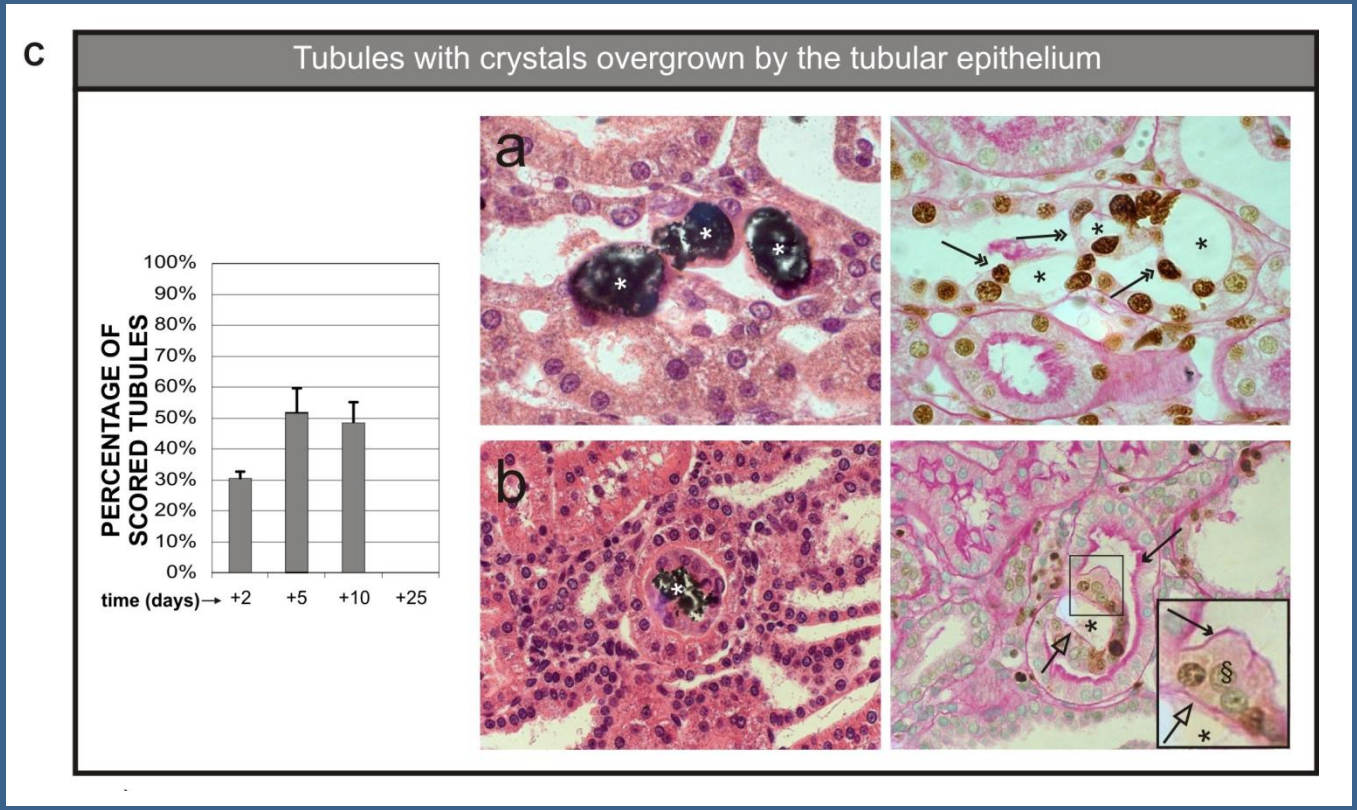

Vervaet B. Kidn. Intern. et al 2008

The tubular epithelium and intratubular nephrocalcinosis: Morphology of crystal containing tubules (qualitative)

Tubules with crystals covered by epithelial cells

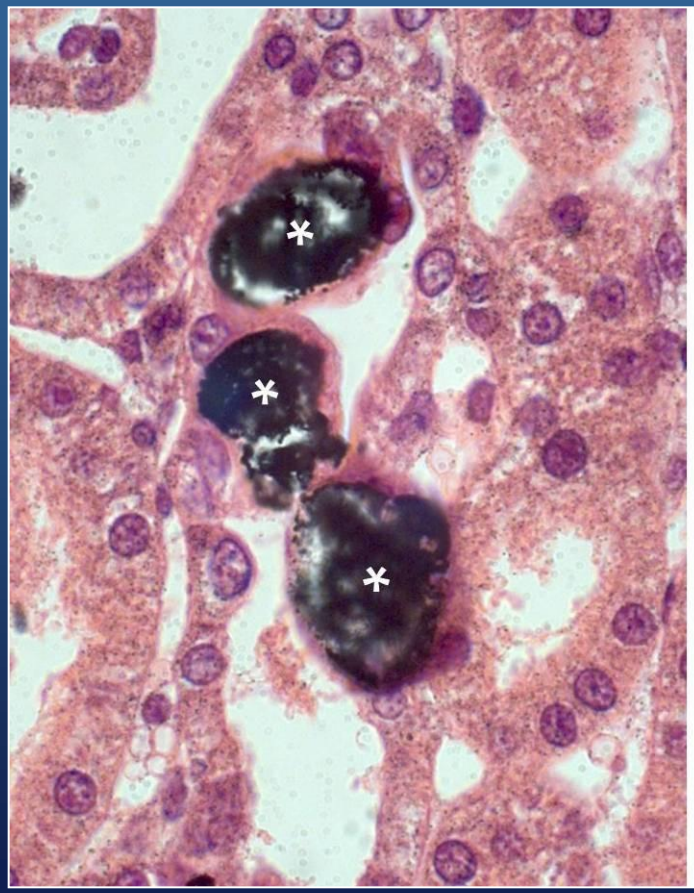

Von Kossa

PAS/PCNA

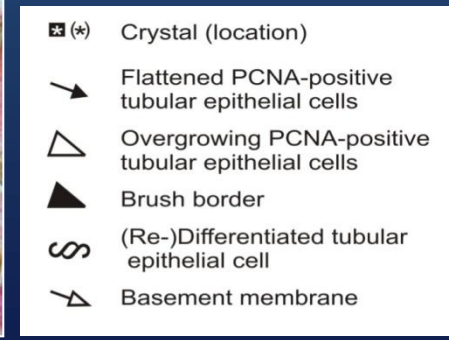

B. Vervaet et al

Stages of epithelial overgrowth after arrest of ethylene glycol treatment

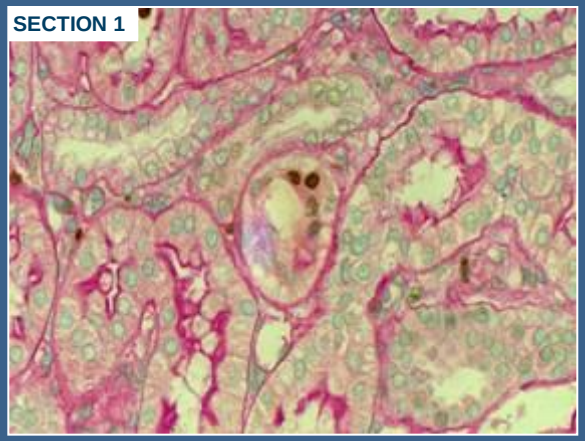

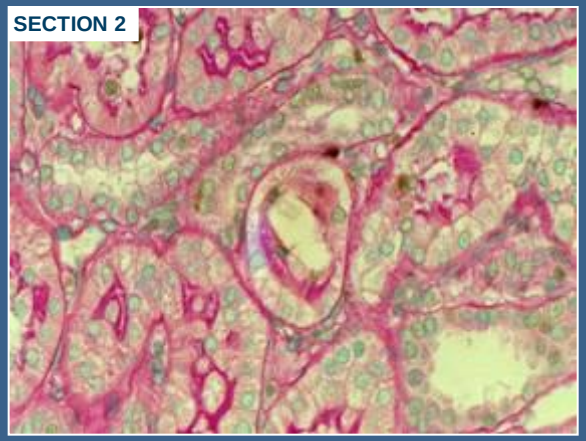

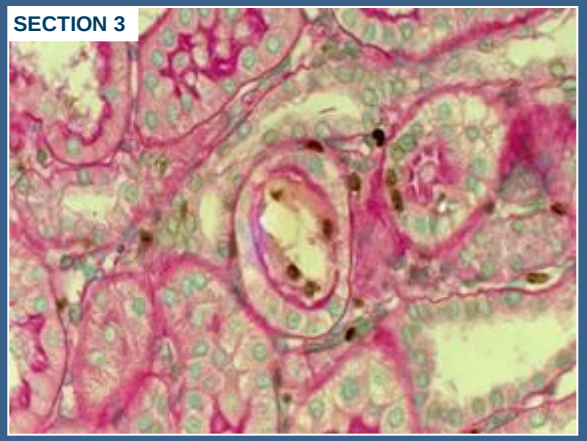

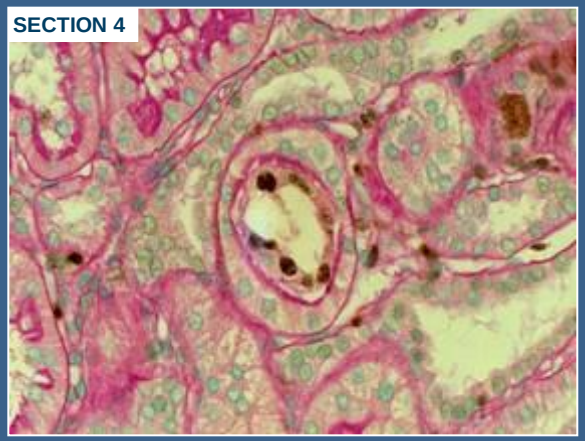

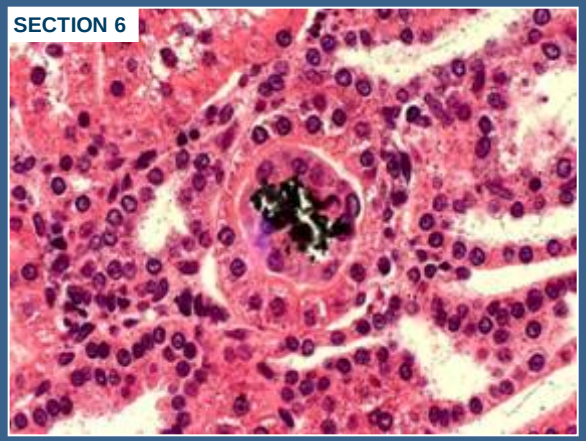

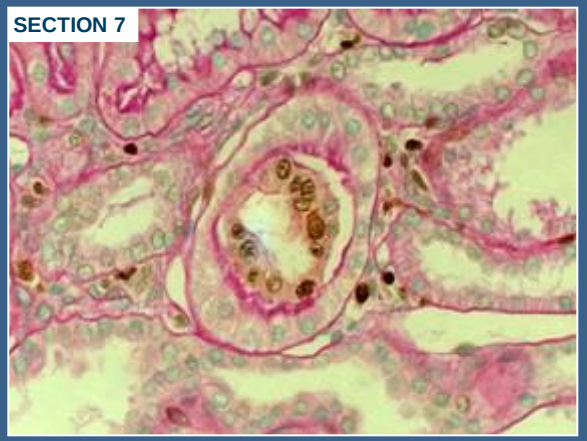

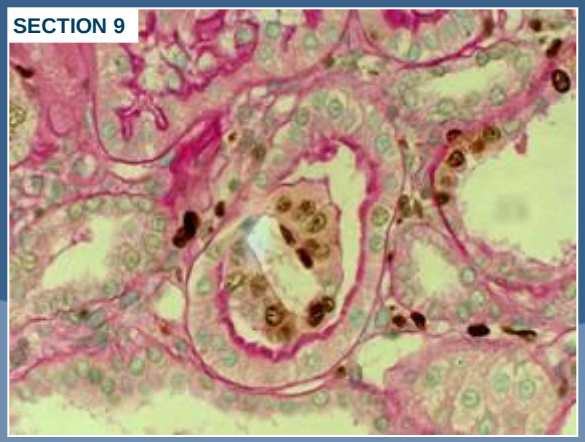

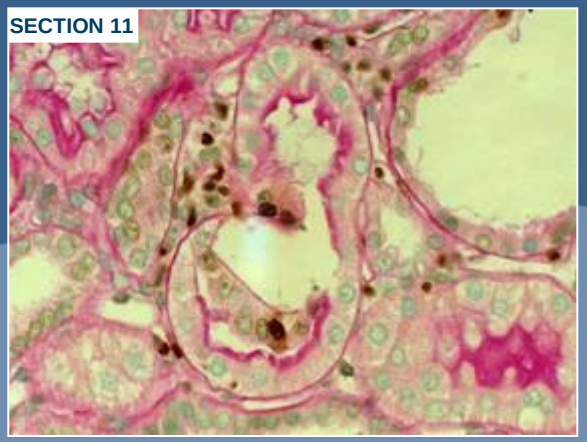

The tubular epithelium and intratubular nephrocalcinosis: Morphology of crystal containing tubules (qualitative)

Tubules with crystals covered by epithelial cells

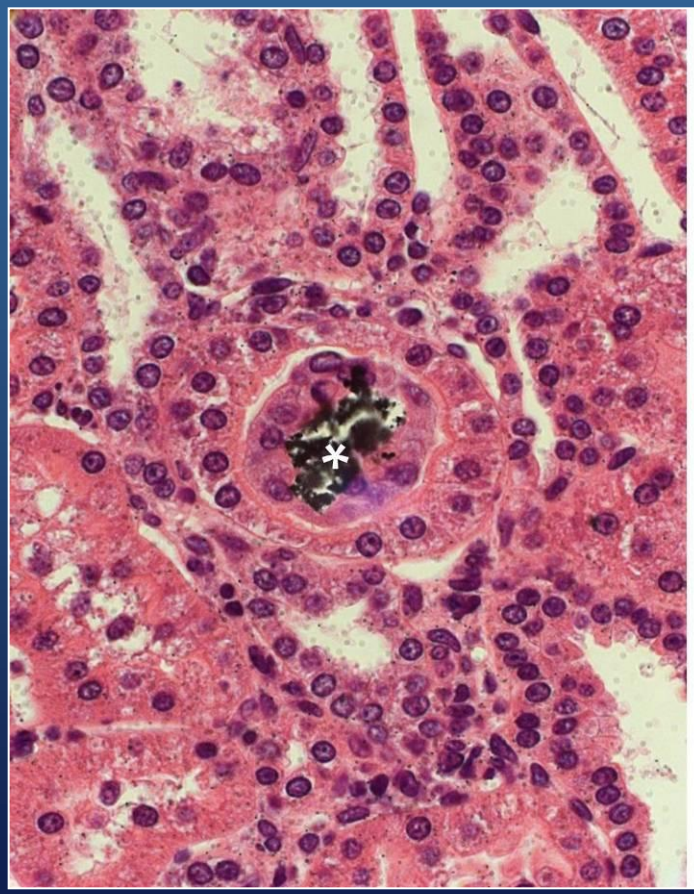

Von Kossa

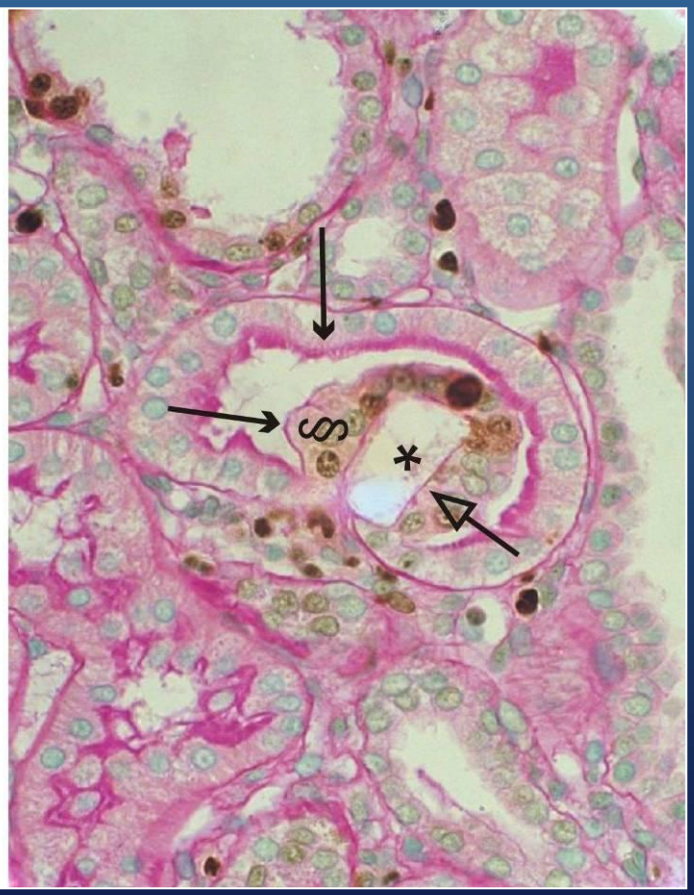

PAS/PCNA

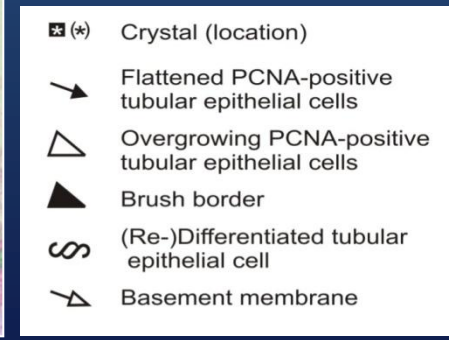

B. Vervaet et al

INTERSTITIAL CRYSTALS

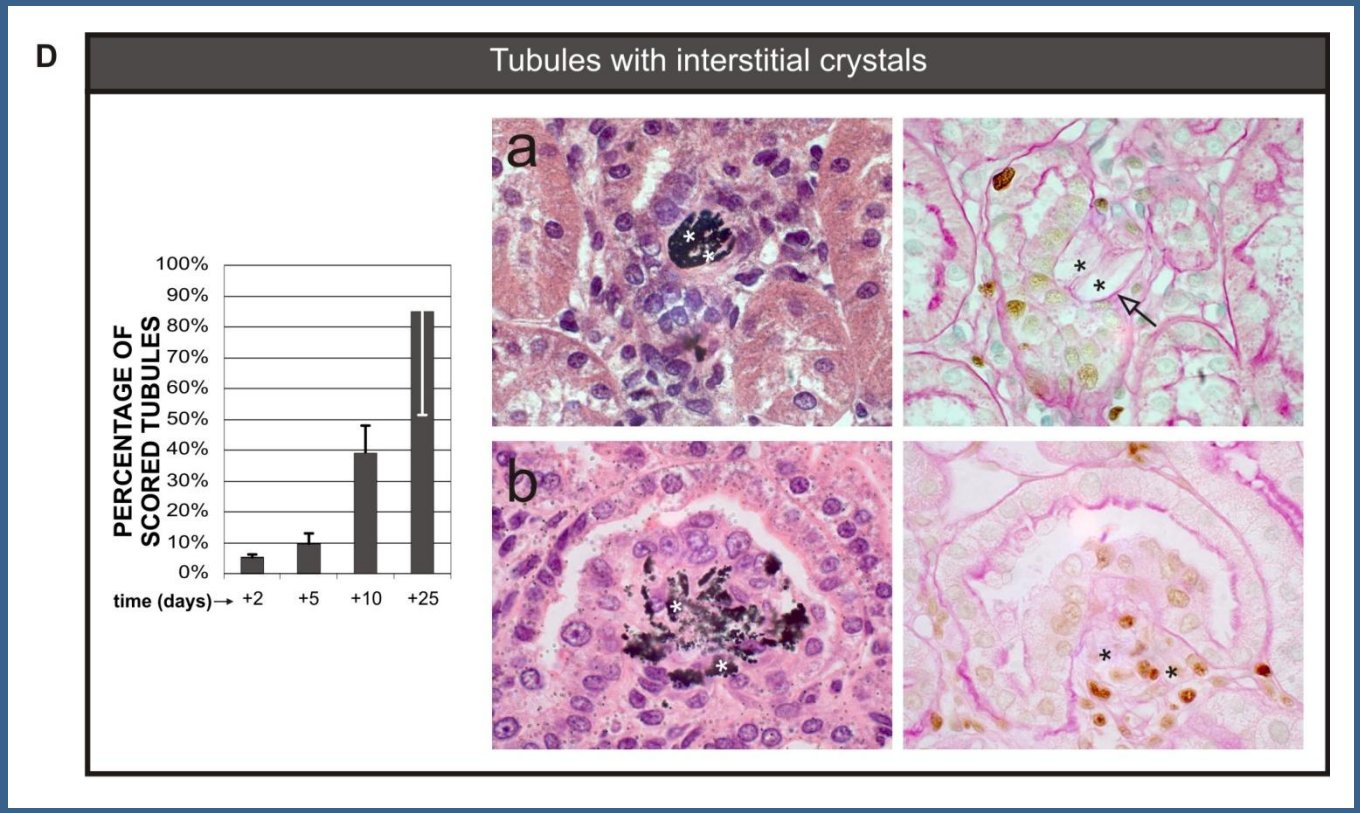

Vervaet B Kidn. Inern. et al 2008

The tubular epithelium and intratubular nephrocalcinosis: Morphology of crystal containing tubules (qualitative)

Interstitial crystals

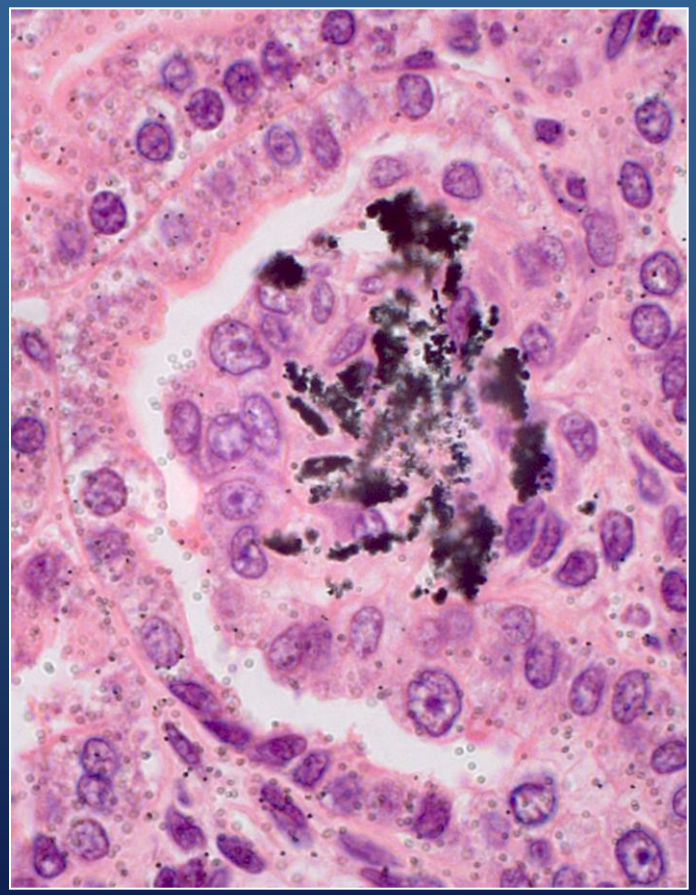

Von Kossa

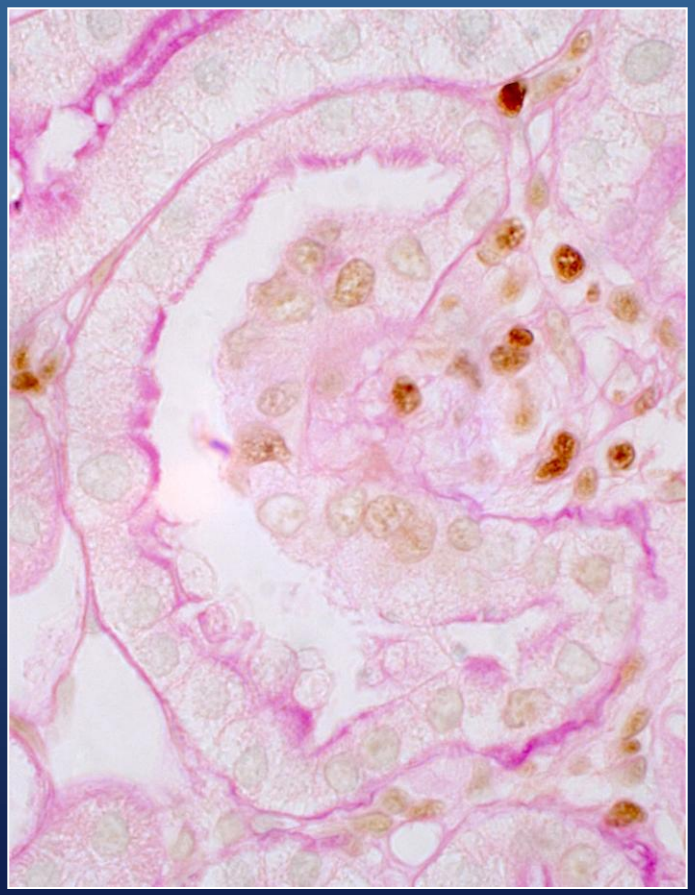

PAS/PCNA

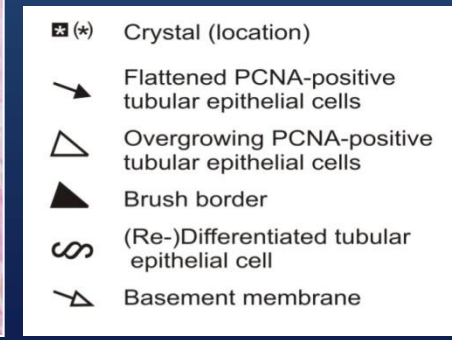

B. Vervaet et al

The tubular epithelium and intratubular nephrocalcinosis: Morphology of crystal containing tubules (qualitative)

Crystals in granuloma

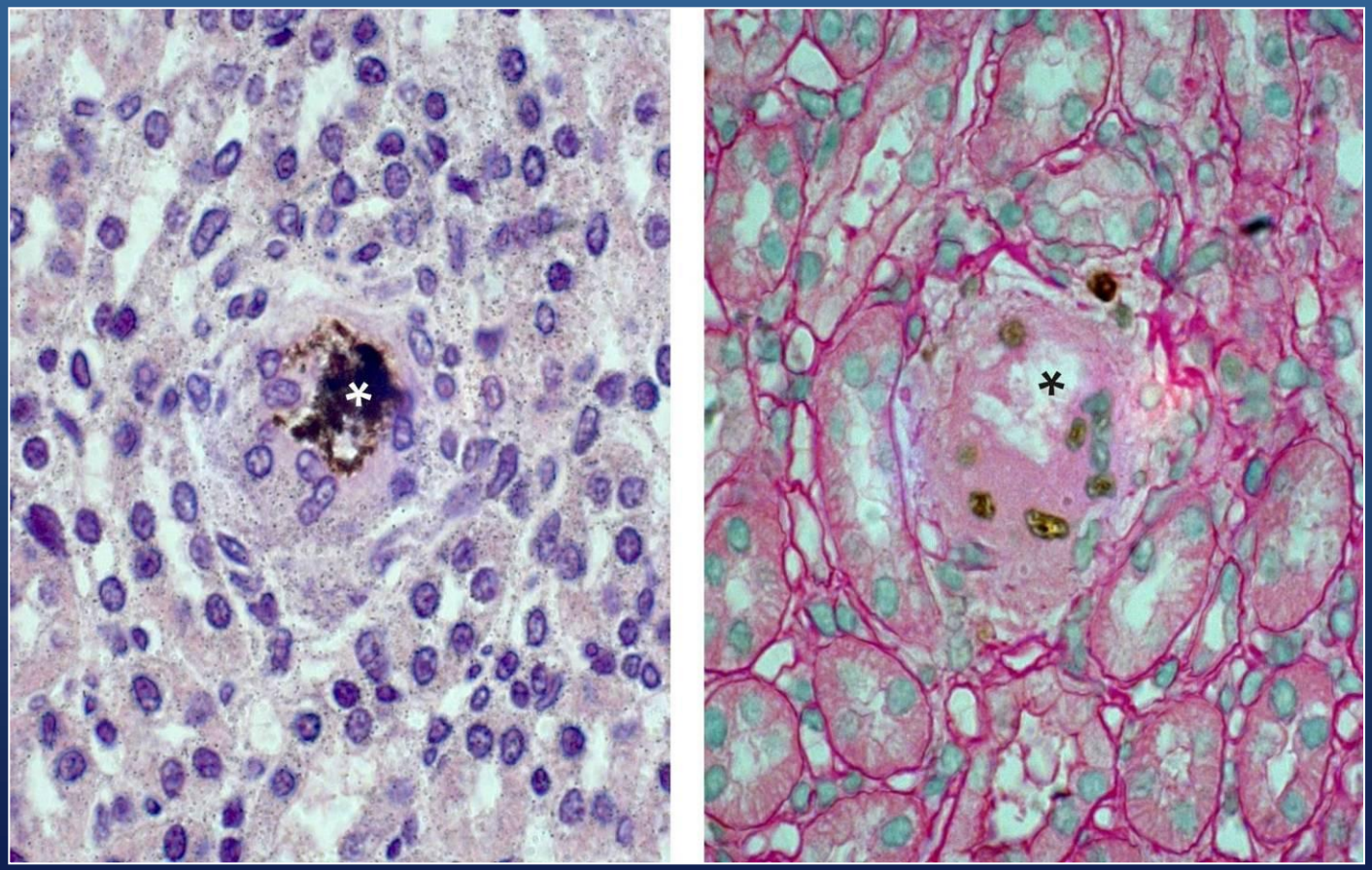

Von Kossa

PAS/PCNA

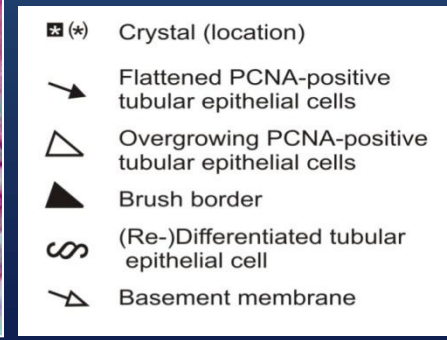

B. Vervaet et al

Handling of crystals in the distal tubule

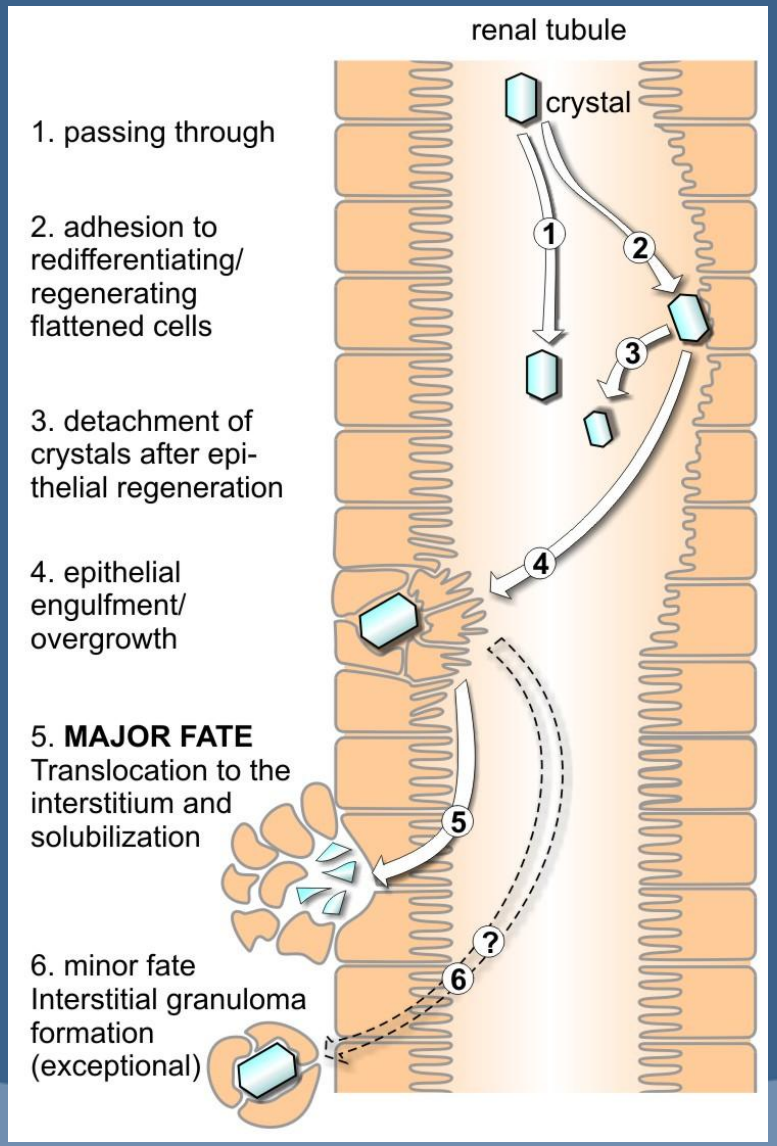

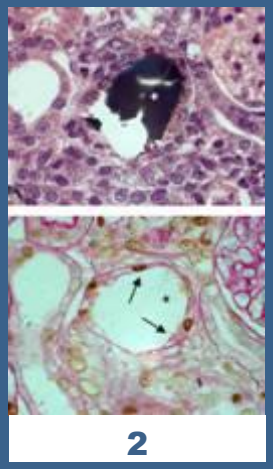

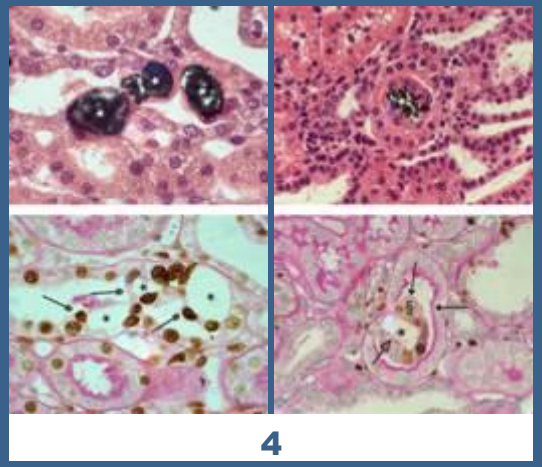

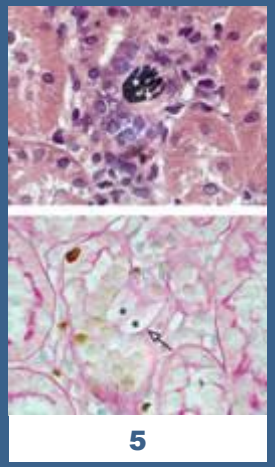

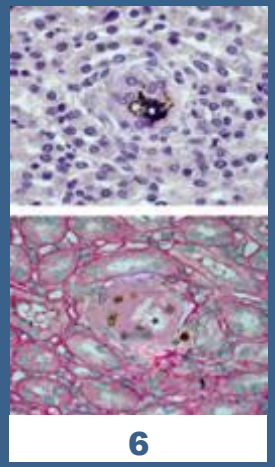

Vervaet B et al. Kidey Int 2008 –

HUMAN KIDNEY BIOPSIES

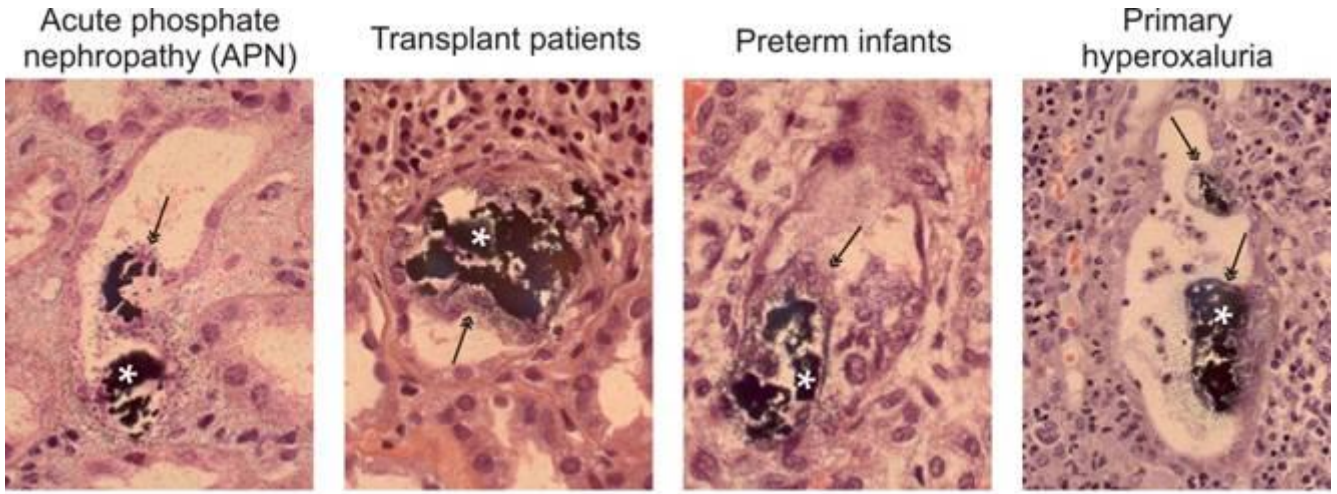

	APN	Transplants	Preterm inf.	Prim. Hyperoxal.
Number of patients	16	10	8	2
Number of biopsies	16	20	8	3
Number of crystal containing biopsies	16	12	8	3
Number of crystal containing biopsies showing overgrown crystals	16	6	7	3
Mean (± SD) percentage of crystals showing overgrowth	24.4 ± 24.3	56.7 ± 24.8	13.5 ± 8.1	No data

Vervaet B. Kidn.Intern.et al 2008

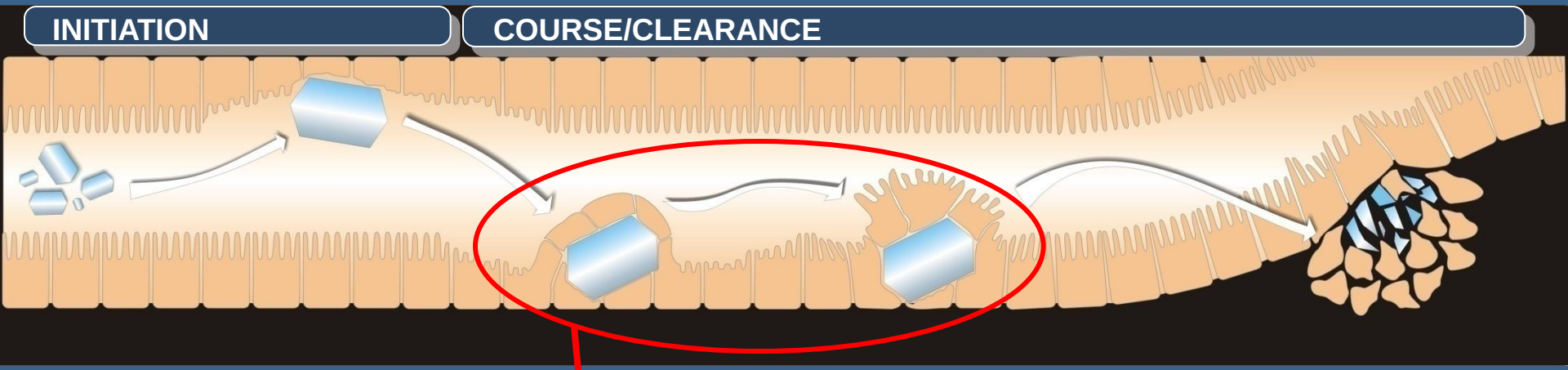

HUMAN

MORPHOLOGY OF CRYSTAL CONTAINING TUBULES IN HUMANS

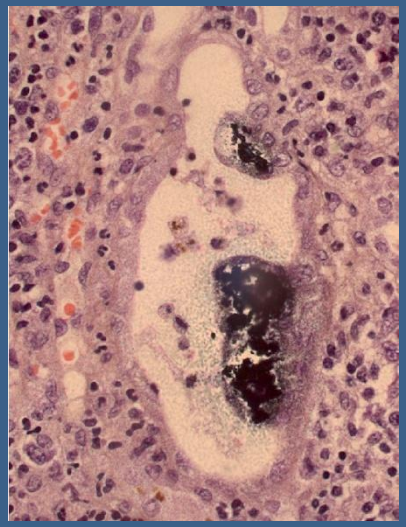

Primary hyperoxaluria

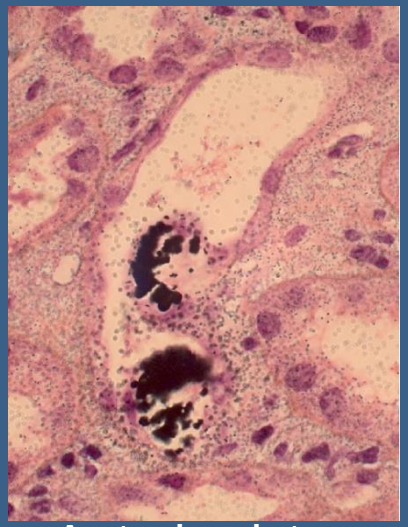

Acute phosphate nephropathy

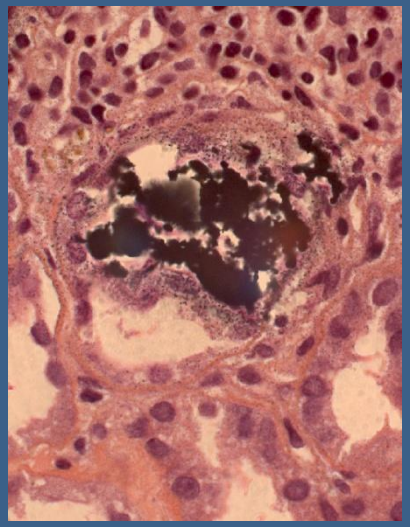

Transplant patients

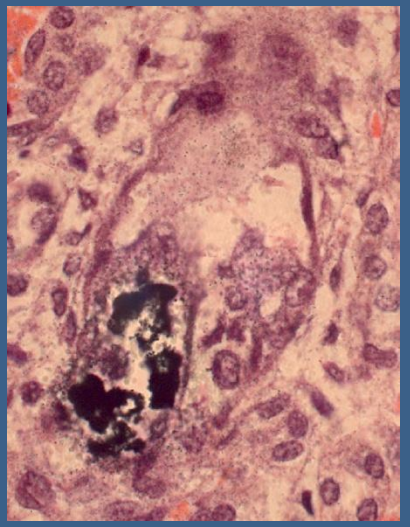

Preterm infants

INITIATION

COURSE/CLEARANCE

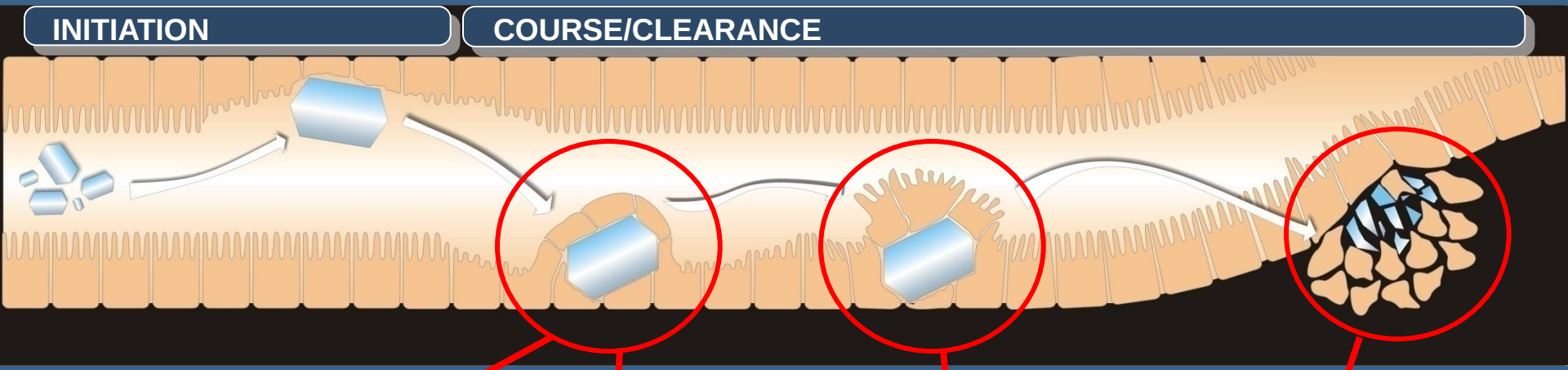

EXTRA OBSERVATIONS

Cystine stone former
(Evan et al. Kidney Int 2006)

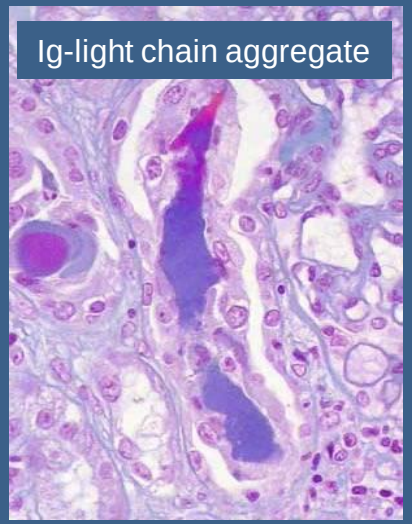

Cast nephropathy

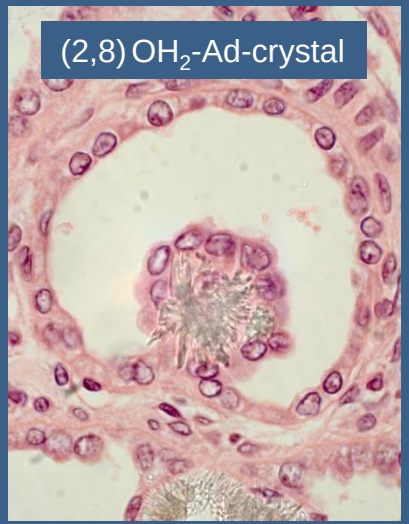

Adenine-treated rat

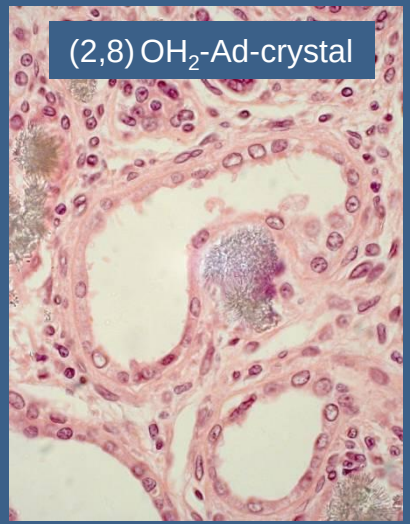

Adenine-treated rat

Representative histopathologic lesions of melamine nephrotoxicity in animals

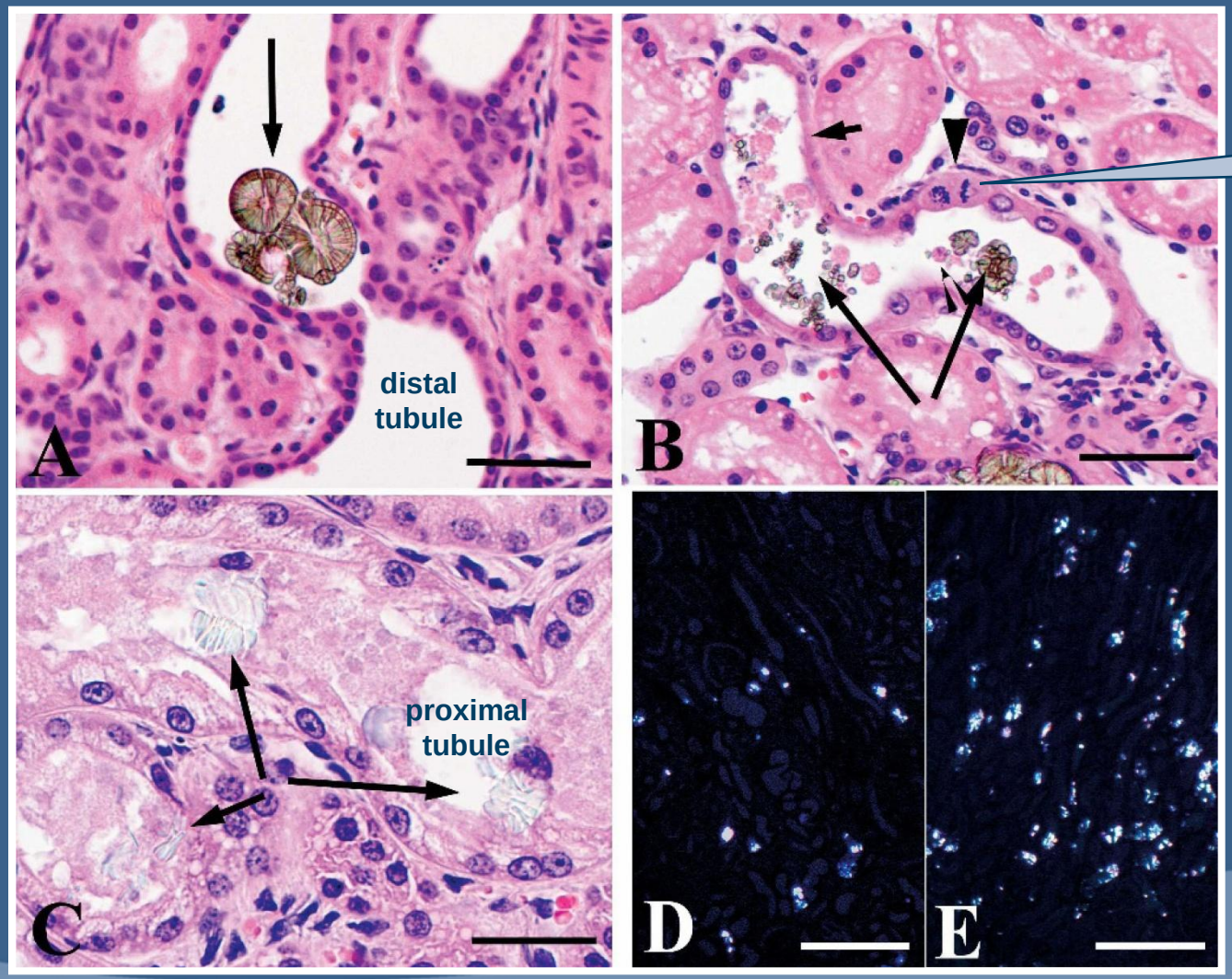

Melamine in renal stones In man

Brown Ca et al: J Vet Diagn Invest 19:525–531, 2007

Representative histopathologic lesions of melamine nephrotoxicity in animals

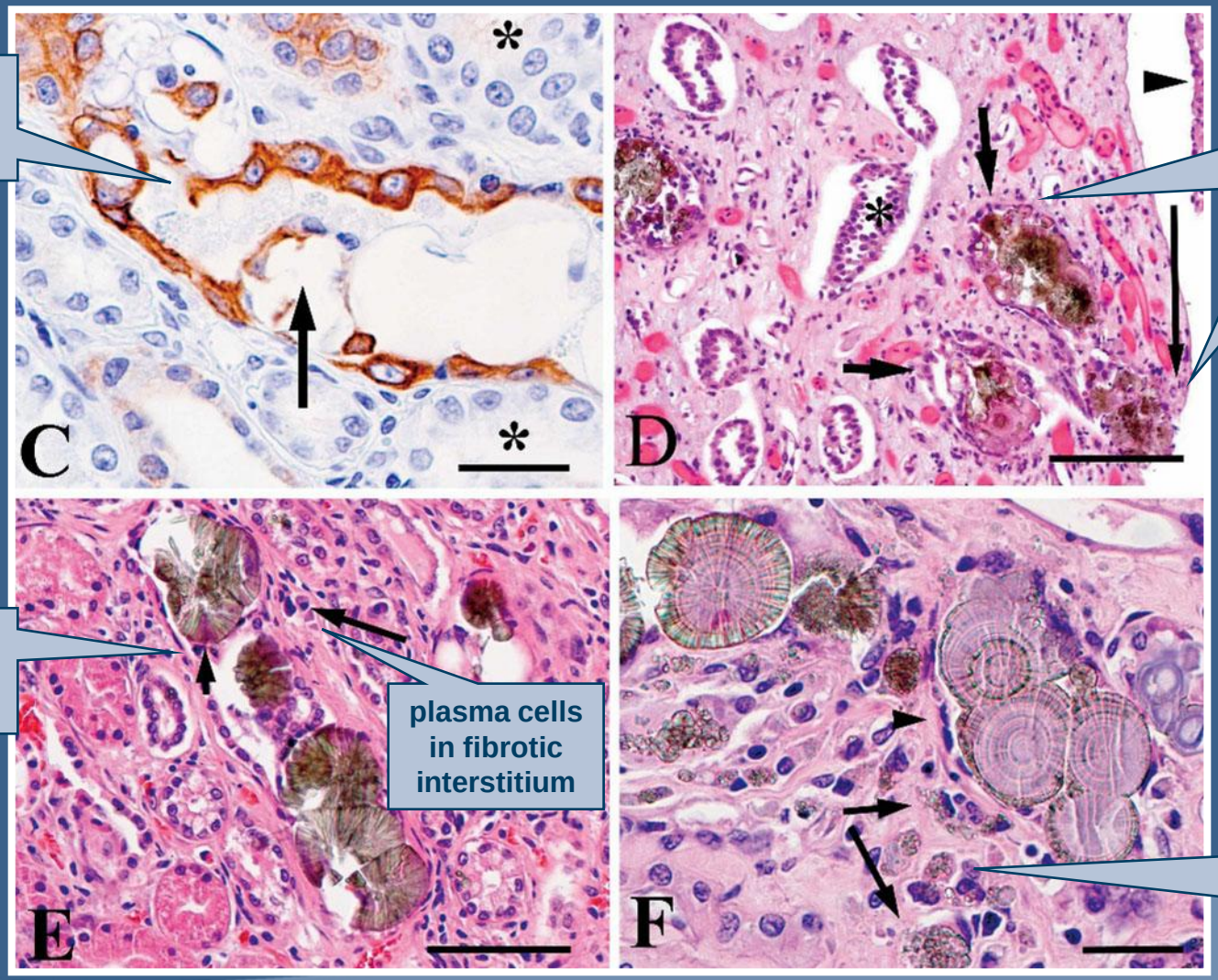

pancytokeratin staining = distal tubule

crystals in collecting ducts and in papillae

epithelial cells cover the crystals

plasma cells in fibrotic interstitium

medullary interstitium epitheloid macrophages

Brown Ca et al: J Vet Diagn Invest 19:525–531, 2007

Conclusions

- Intact epithelium is **anti-adhesive**
- Crystal retention by **regenerating cells**
  luminal expression of HA
  Osteopontin, CD44,Annexin II
- Nucleolin related-protein

- Crystal **fate**
  - passing through
  - adhesion to regenerating cells
  - crystal overgrowth epithel. cells – solubilization?
  - granuloma formation (exeptional)
- Preconditioning of distal epithelium **precedes** nephrocalcinosis
- KIDNEY POSSES A CRYSTAL CLEARANCE MECHANISM THAT UNDER ABNORMAL CONDITIONS CAN BE OVERULED

*:Acidic environment ?

Day +10

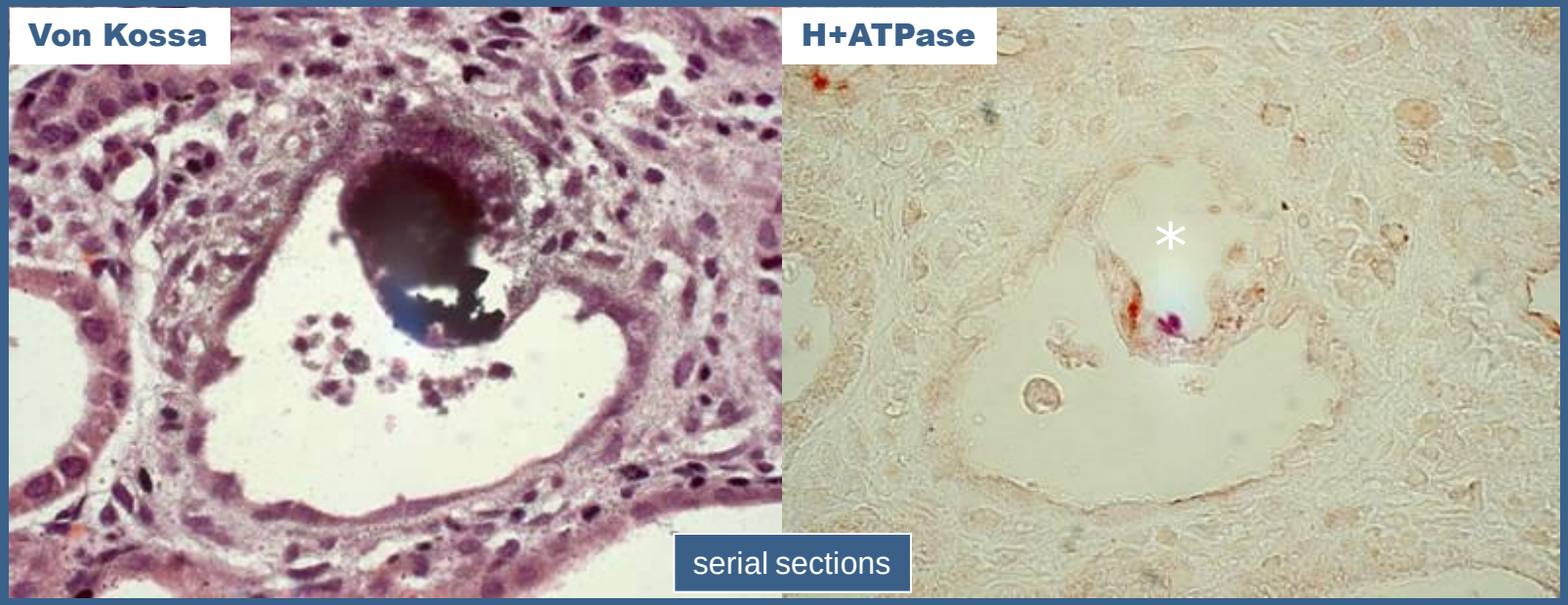

Day +25

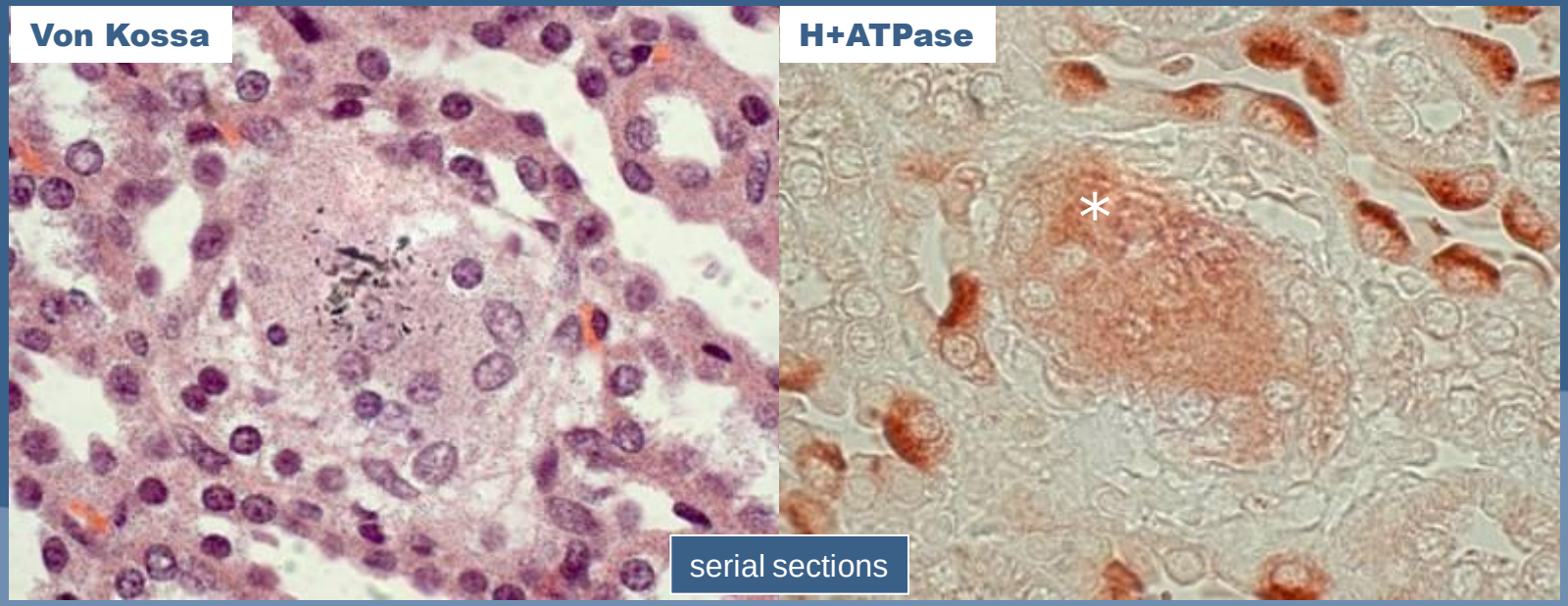

The tubular epithelium and intratubular nephrocalcinosis: Perspectives

CLINICAL

→ Does defective crystal clearance actually adds to the progression of nephrocalcinosis?

BASIC

→ Why do the overgrowing epithelial cells redifferentiate to their original phenotype?

→ What happens to the original epithelium? EMT?

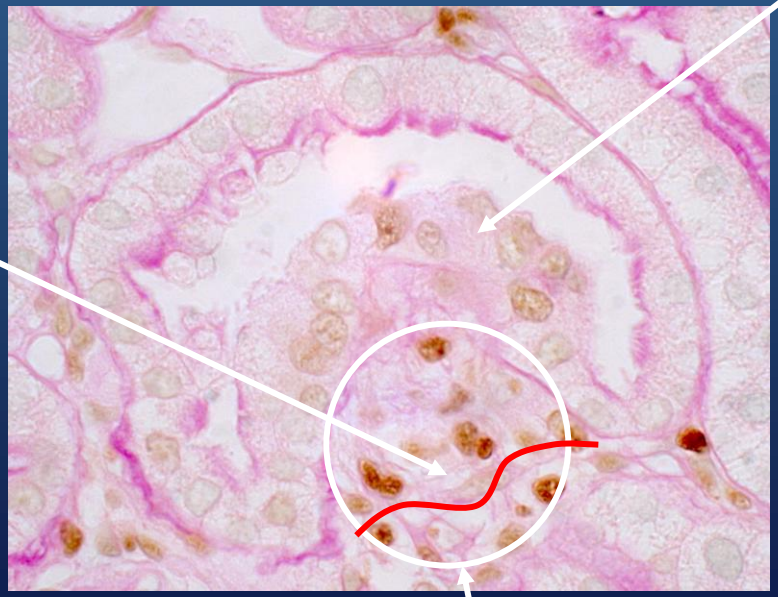

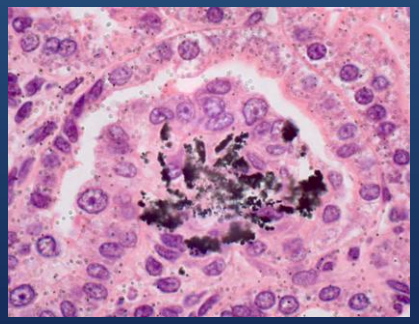

→ Which cells are involved/recruited in crystal clearance?
→ What is the mechanism of crystal clearance? Combination of low pH and proteases?

B. Vervaet et al

The origin and growth of renal calculi (Alexander Randall)

- Renal calculus formation is dependent upon a **preexisting renal lesion,** some form of renal papillary damage antedating the deposition
- The expected lesion is placed upon the **renal papilla,** deposing calcium in the walls and intertubular spaces
- Renal calculi are **growing upon,** and actually adherent to the renal papilla
- The calculus was intimately attached to this calcium deposit
- Stones **from such** calcium plaques, and the salt deposited as a calculus was of **different character than the plaque**
- Calcium plaques are a **natural reparative process** to some form of tubule damage, occurring in much higher incidence than clinical renal stones
- **Unraveling the true etiology** of primary renal calculus is to be sought in an increasing knowledge of the physiology and pathology of the **renal papilla**

Randall A: Annals of Surgery 105: 1009-1027, 1937

- Primary renal calculus is only a symptom, and always originates as a slow crystallization of urinary salts upon a lesion of the renal papilla**. Calcium phosphate, calcium oxalate and uric acid** crystallization, to form renal calculi, has **in each instance been deposited upon a plaque** of calcium salts deposited in the renal papilla.

Randall A: J Urol 44: 580-9, 1940

De novo calcium phosphate crystal formation in basement membrane of loop of Henle:

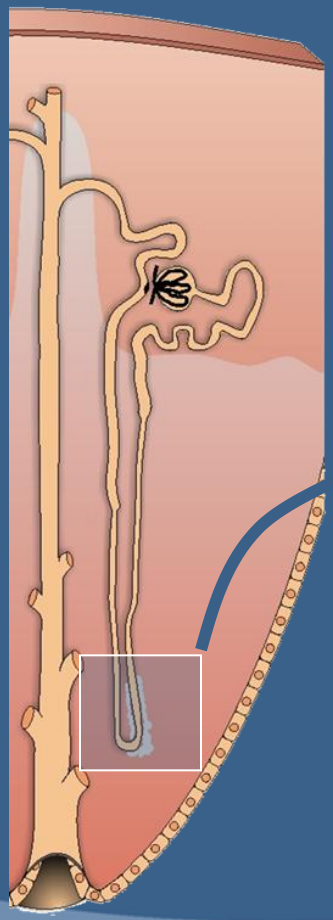

- No intratubular crystals in *idiopathic calcium oxalate stone formers.*
- No intracellular crystals.
- No translocation of crystals.
- Always calcium phosphate.

Evan et al. *Pediatr Nephrol. 2010;25:831-841*
Evan et al. *J Clin Invest. 2003;111(5):607-16*

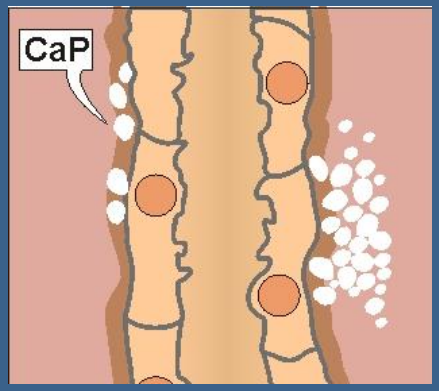

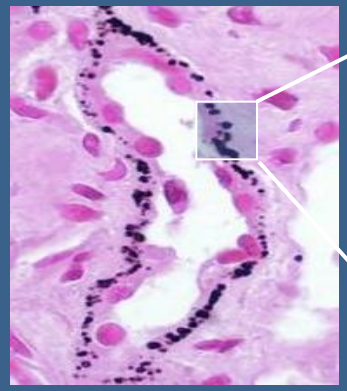

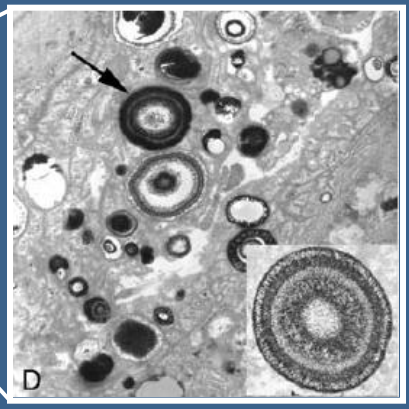

MECHANISM? UNKNOWN

-Interstitial concentration of calcium and phosphate
-Interstitial effect of water conservation
-Changes in interstitial pH

Kidney stone disease:
Accumulation of interstitial crystal deposits as seen in light and TEM images in a papillary biopsy from an **idiopathic calcium oxalate** stone former

Light microscopy revealing extensive accumulation of crystalline deposits shown around the Henle loops and nearby vascular bundles and inner medullary CDs, resulting in the formation of incomplete to complete cuffs of plaque (x1,500)

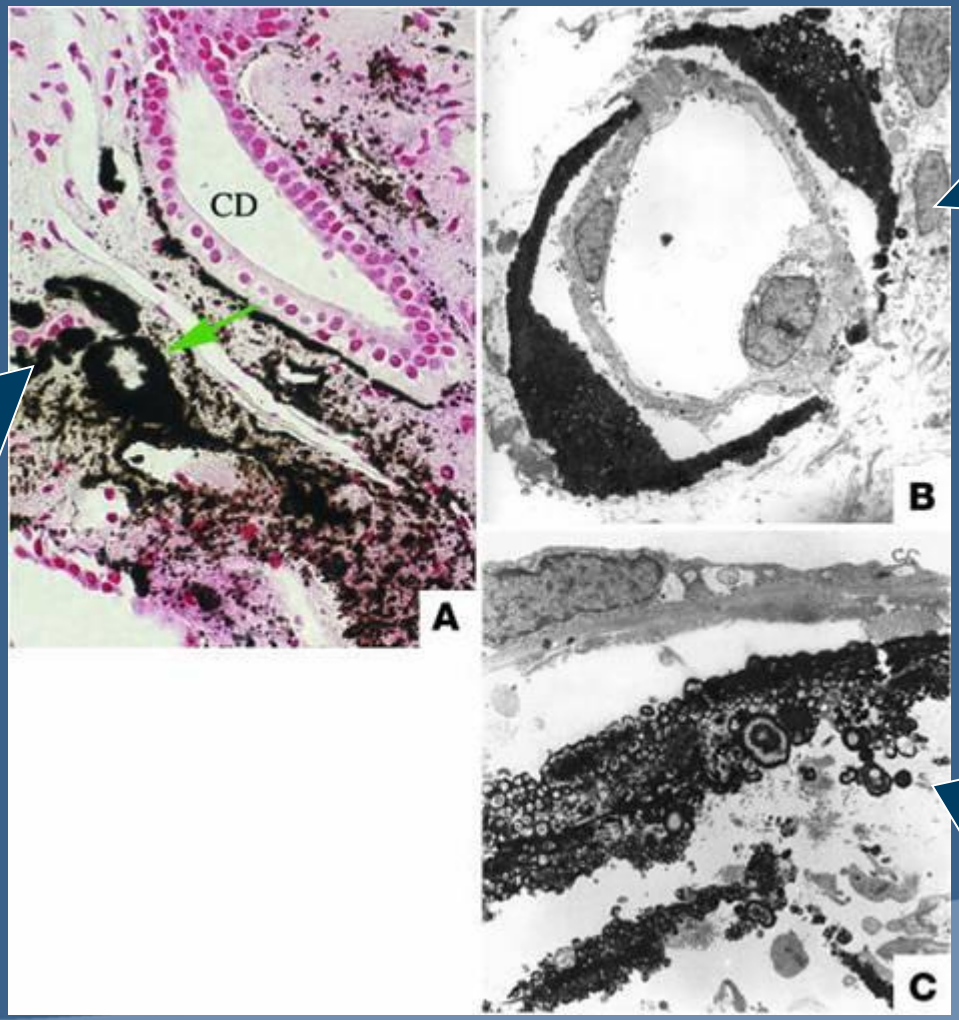

Normal thin Henle loop surrounded by a complete cuff of interstitial plaque (TEM, 13,000x)

hydroxyapatite

Site of plaque located in the interstitial space, away from a tubular wall; single crystal deposits appear embedded in a sea of matrix (TEM, 13,000x)

Suburothelial plaque

Coe FL et al: JCI 115: 2598-2608, 2005

DDW3663

Histopathology and surgical anatomy of patients with **primary hyperparathyroidism** and calcium phosphate stones

Most papillae were normal appearing in patient 1 (a) with small regions of Randall's plaque. Two papillae contained markedly dilated BD with crystalline plugging (b, arrow) and were retracted

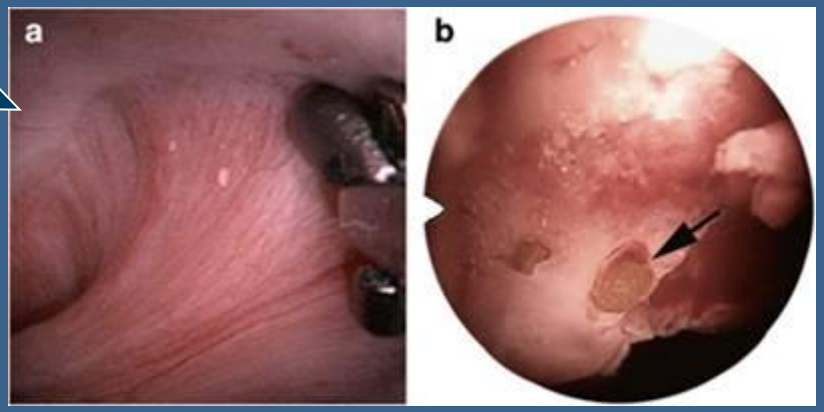

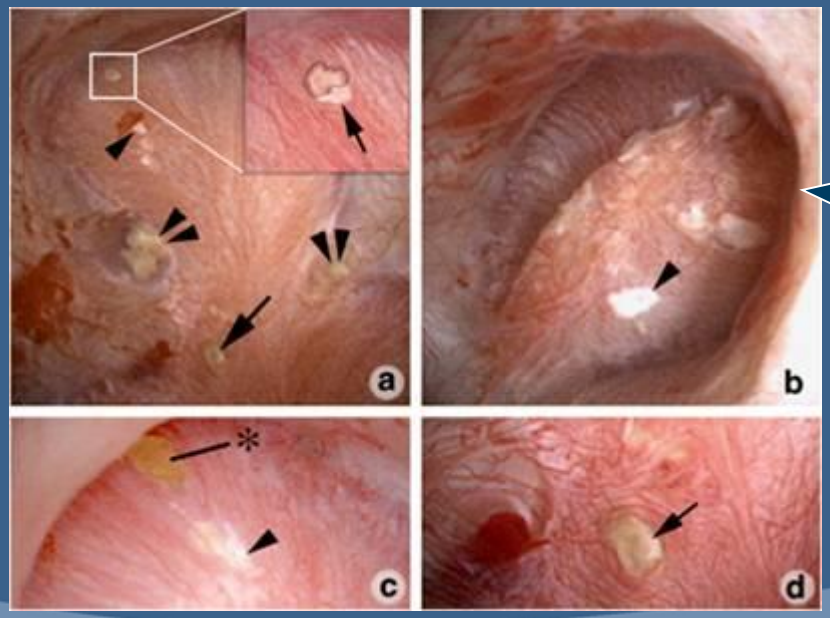

Coexistence of attached stones and BD plugging on the same papillae (patient 2)

The renal papilla from a stone former Is particular to the clinical setting

Evan AP et al: Kidney Int 74: 223-229, 2008

DDW3663

Nephrocalcinosis

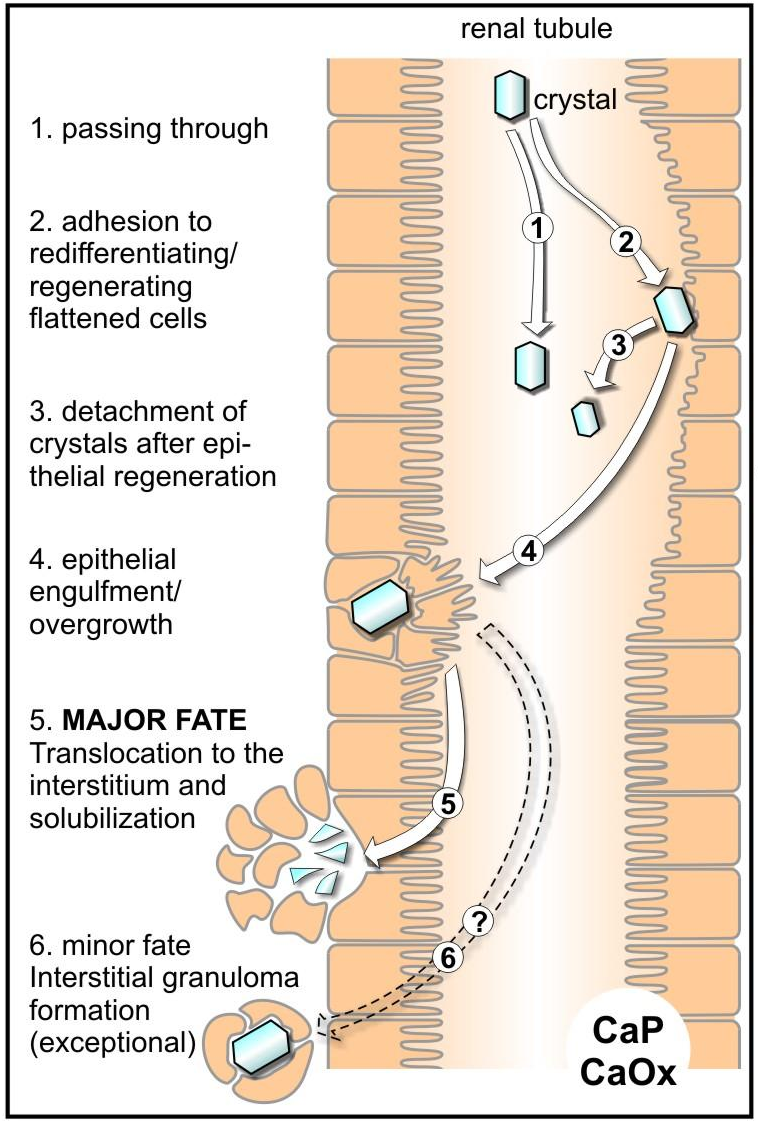

Nephrolithiasis

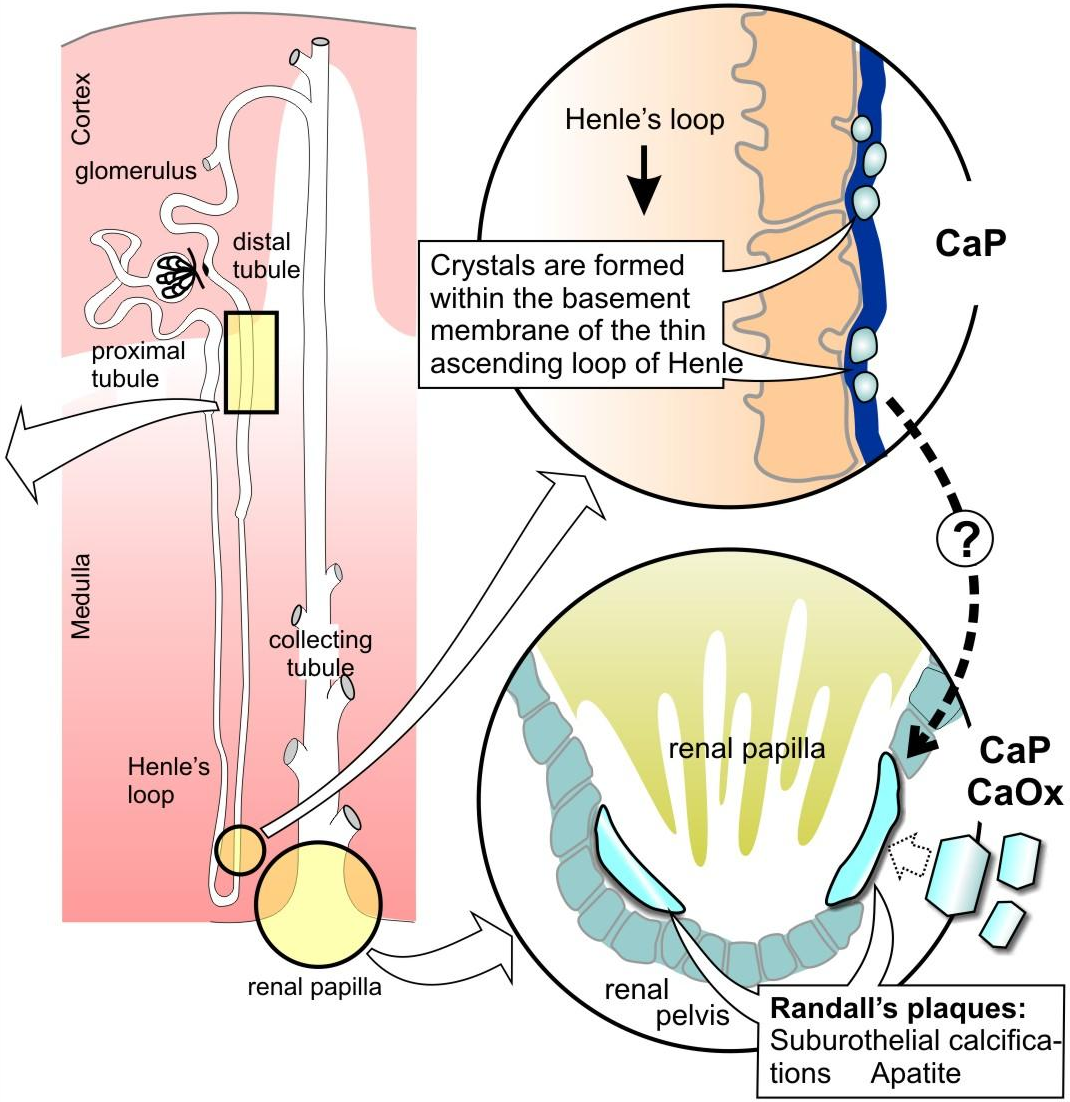

TREATMENT of NEPHROLITHIASIS/CALCINOSIS

- Dietary measures
- fluid intake
- Na restriction
- oxalate restriction and avoidance of Ca restriction

- Thiazide diuretics: decrease of calciuria
- –enhanced reabsorption of Ca in DCT –sodium depletion. -potassium depletion may cause intracell. acidosis and hypocitraturia.

- Potassium citrate

- Purine restriction , Allopurinol,in hyperuricosuric uric acid s

- Probiotics ,oxalobacter formigenes, pyridoxine (glycine formation)
- pH cystine, uric acid stones

- Future ,calcimimetics (polyuria, acidification)….

Treatment of nephrolithiasis

- Fluid intake
  - type of drink seems to matter:
    orange juice, coffee, alcohol, water
    Curham SC et al: Ann Intern Med 128: 534-540, 1998
    Borghi L et al: J Urol 155: 839-843, 1996
- Na^+ restriction
  - reduce urinary calcium – major
  - raising urinary citrate
  - reducing sodium / urate saturation
- Protein restriction
  - reduce sodium intake
  - less acid
  - increase of citraturia

Comparison of two diets for the prevention of recurrent stones in idiopathic hypercalciuria

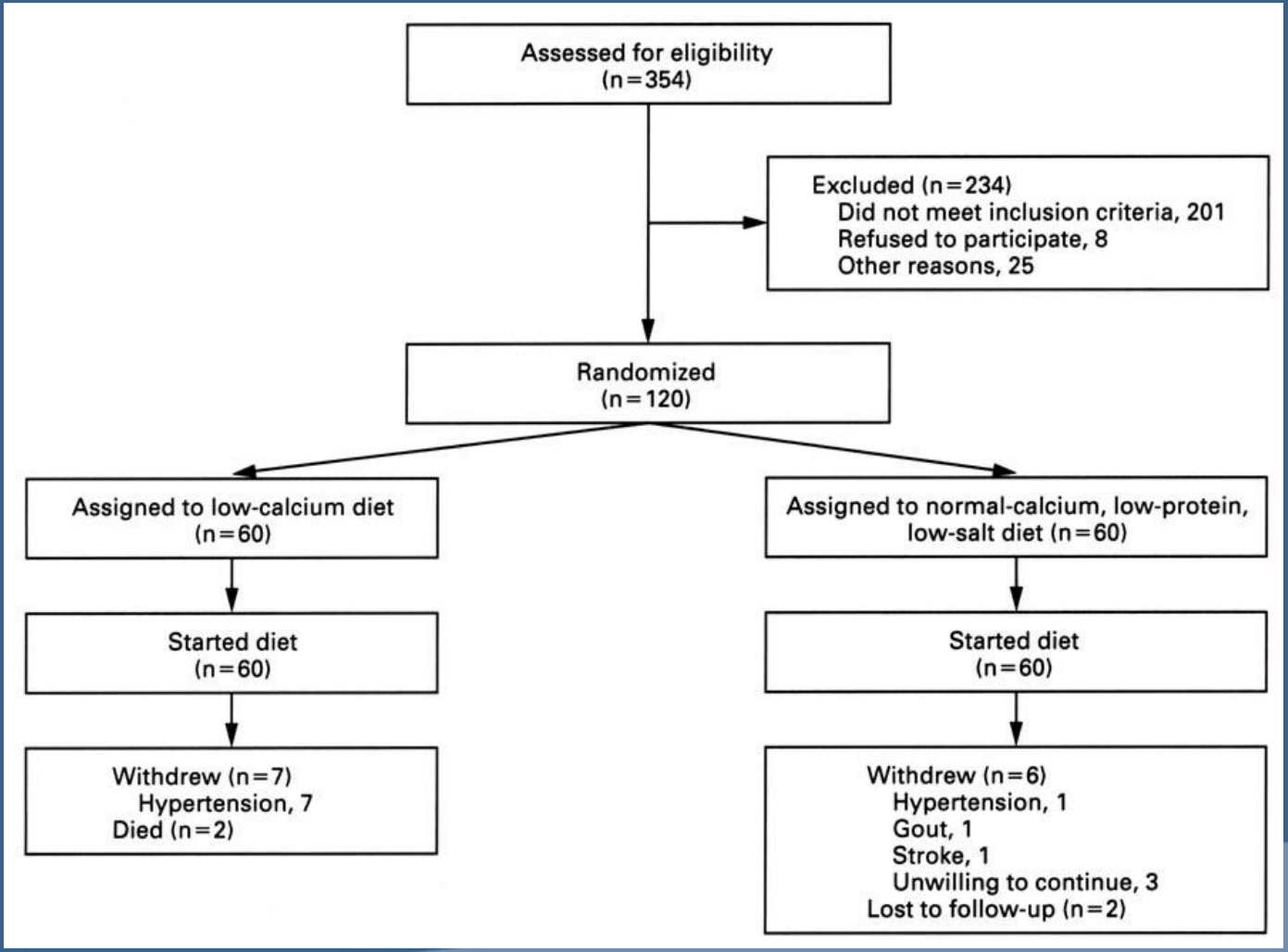

Borghi L et al: New Engl J Med 346: 77-84, 2002

Comparison of two diets for the prevention of recurrent stones in idiopathic hypercalciuria

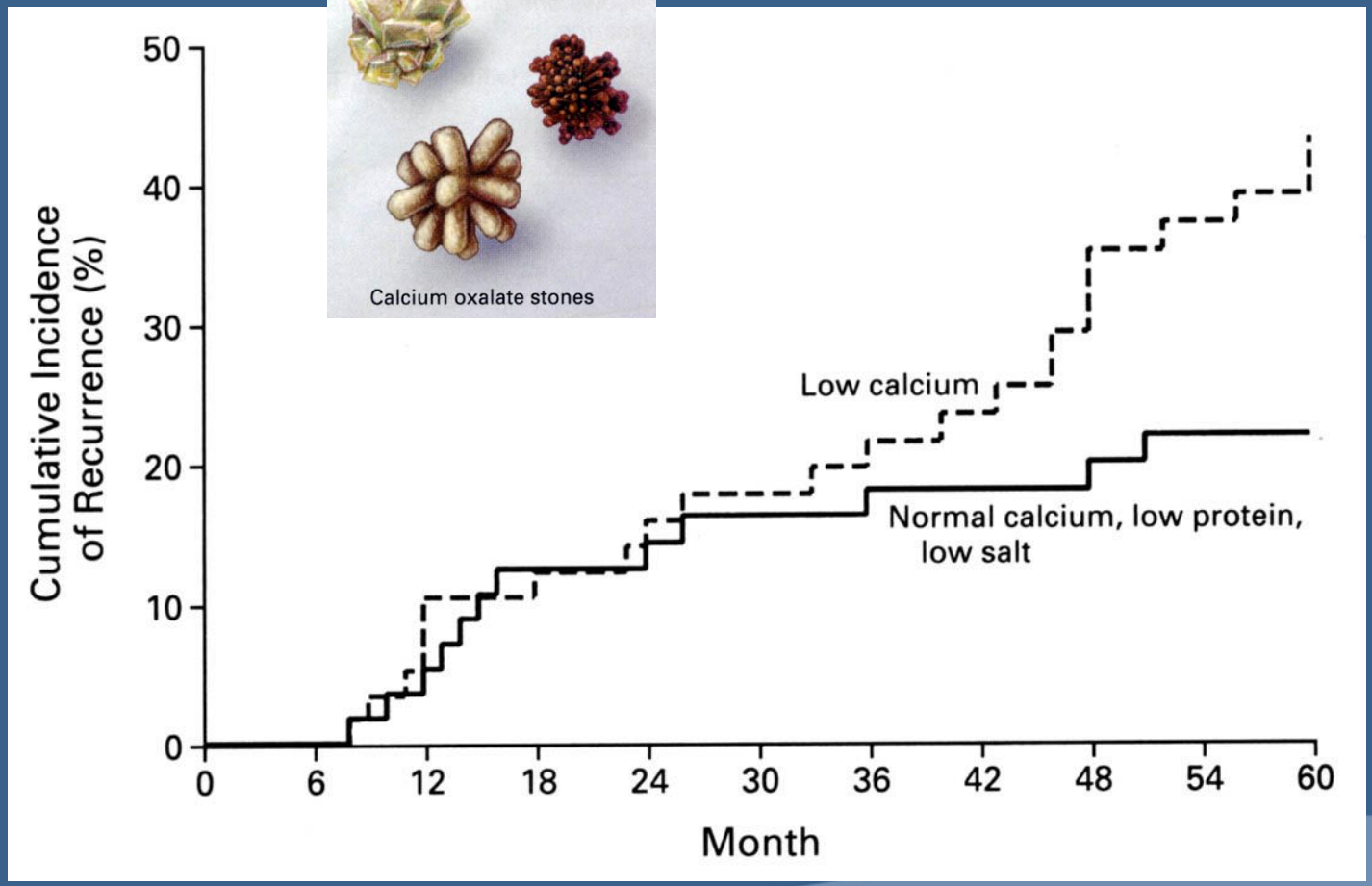

ur. oxalate increased

ur. oxalate decreased

Borghi L et al: New Engl J Med 346: 77-84, 2002

Transport mechanism for Na^+ and Cl^- reabsorption in the early segment of the distal tubule

Impermeable for H_2O
Diluting segment

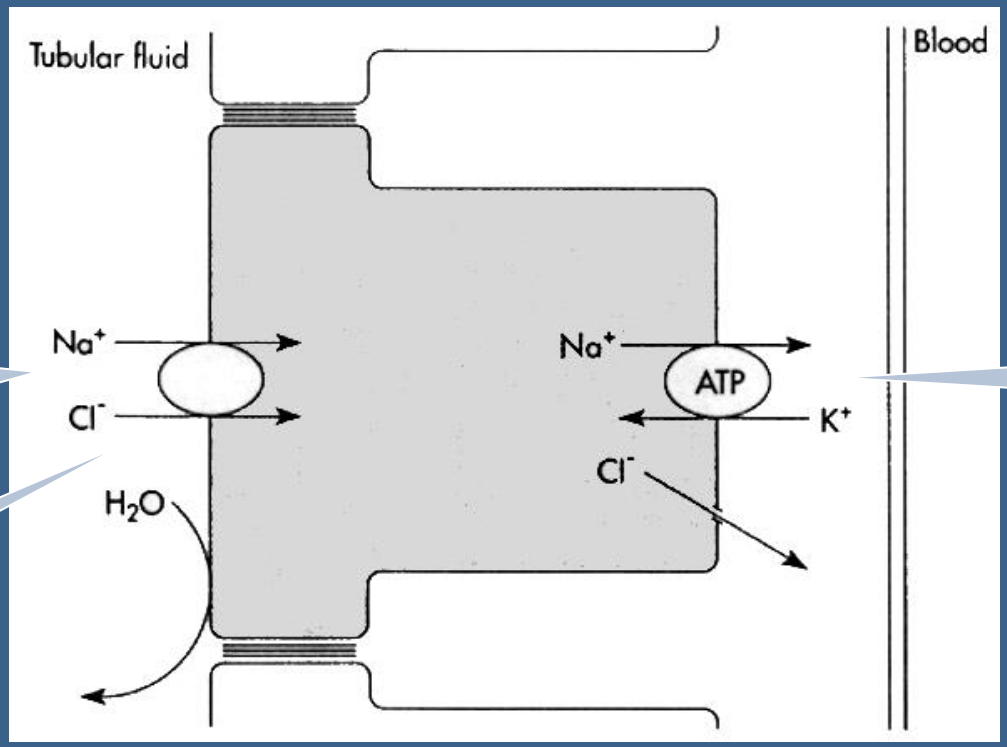

thiazide diuretic

Inhibiting NaCl transport lowers (Cl-) in the DCT cells hyperpolarizing the cell .Steep electric gradient increases Ca++ apical entry.

Stanton BA & Koeppen BM: 'Tubular function' in: *Physiology*, Ed. Berne & Levy, Mosby, 1998

TREATMENT of NEPHROLITHIASIS/CALCINOSIS

- Dietary measures
- fluid intake
- Na restriction
- oxalate restriction and avoidance of Ca restriction

- Thiazide diuretics: decrease of calciuria
- –enhanced reabsorption of Ca in DCT –sodium depletion. -potassium depletion may cause intracell. acidosis and hypocitraturia.

- Potassium citrate

- Purine restriction , Allopurinol,in hyperuricosuric uric acid s

- Probiotics ,oxalobacter formigenes, pyridoxine (glycine formation)
- pH cystine, uric acid stones

- Future ,calcimimetics (polyuria, acidification)….

CITRATE and KIDNEY STONE FORMATION

- Decrease the risk of calcium nephrolith/calcinosis
- Complexes to Ca ions ,urinary supersaturation of CaP/CaOx decrease
- pH dependent ,pH incr. stimulates complex form.
- Direct inhibitory effect on crystallization of Ca salts
- Increase the CaOx aggregation inhibitory activ. of macromolecules (T.H.protein)
- Decrease expression of osteopontin
- Can increase slightly urinary pH …uric acid crystallization

Mechanism of epithelial Ca^{2+} transport

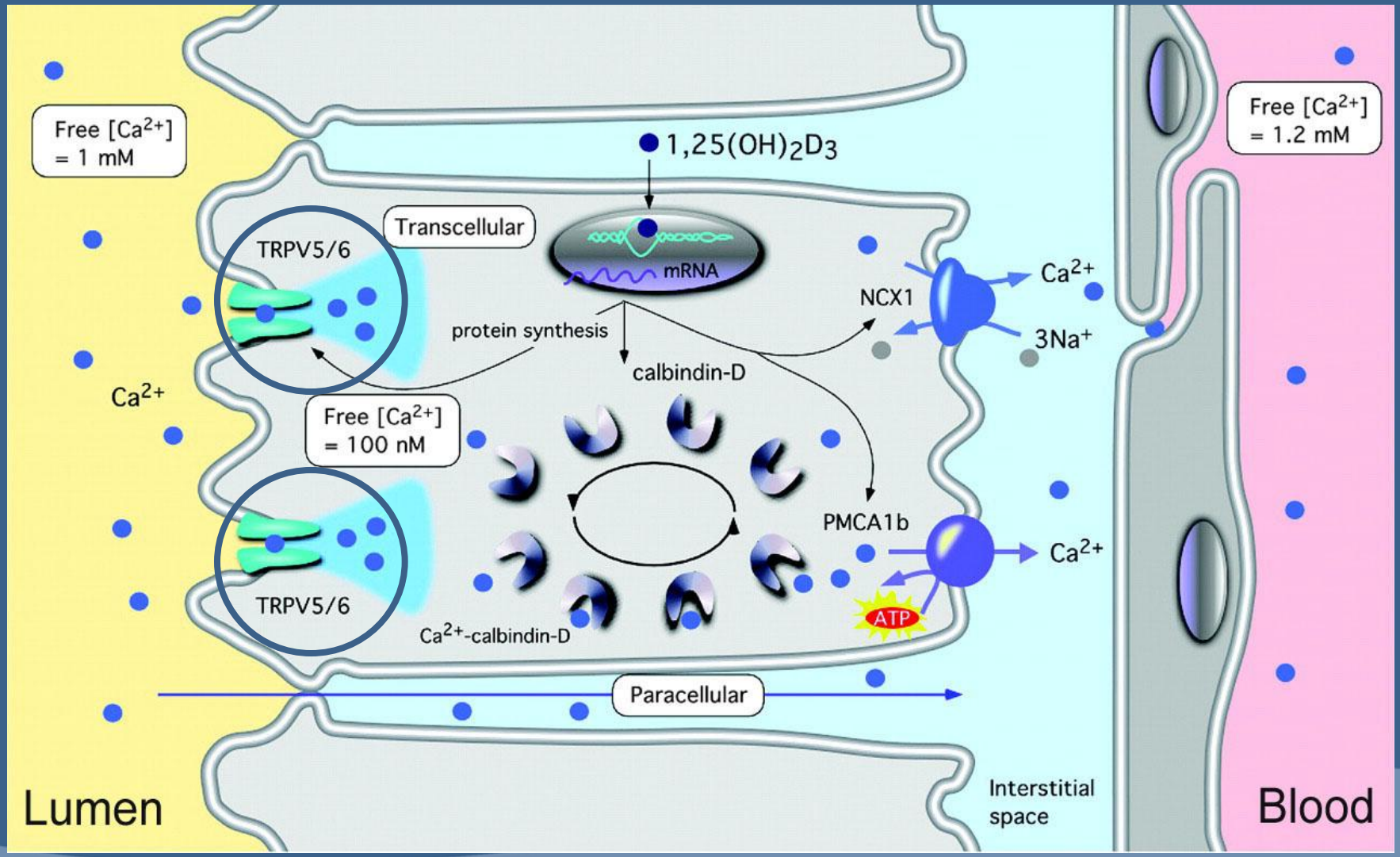

Hoenderop JG et al: Physiol Rev 85: 373-422, 2005

Calcium sensing receptor

The calcium-sensing receptor promotes urinary acidification to prevent nephrolithiasis

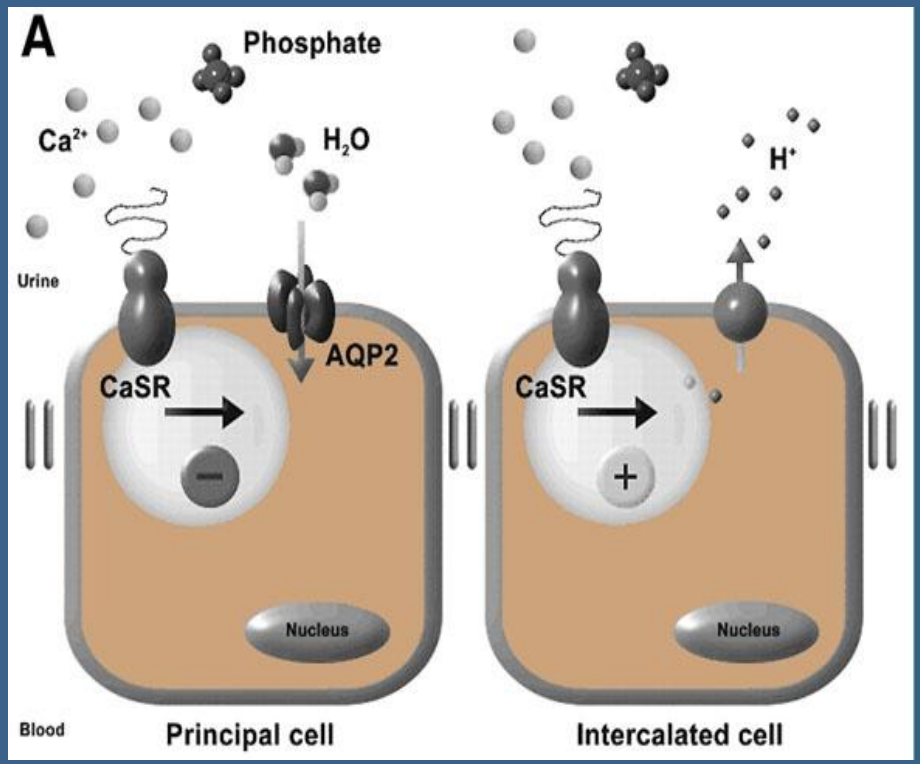

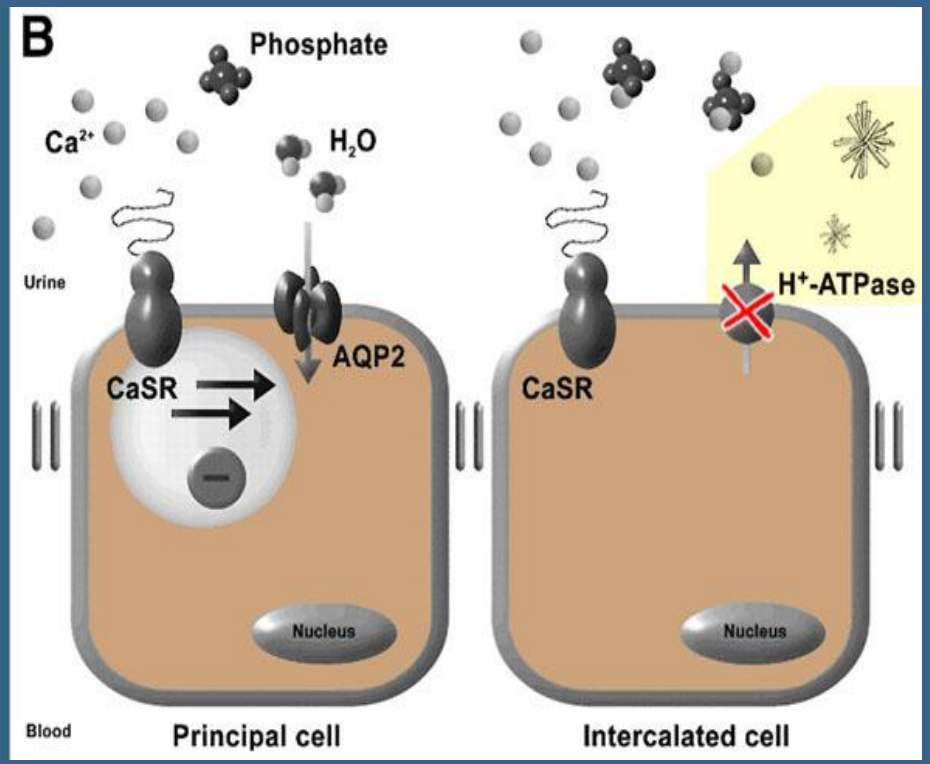

TRPV5-/- mice - AQP2 down regulation
H+ATPase activ. increase

No calcifications

Ablation of Atp6v1b1 leads to absence of H+ ATPase activ and decrease of acidification
in TRPV5-/- mice

calcifications

Renkema K et: JASN 20: 1705-13, 2009

People Involved

30 August 2012

University of Antwerp, Belgium

- BEHETS Geert
- BERVOETS An
- DAMS Geert
- DAUWE Simonne
- DE BEUF Annelies
- DE BROE Marc
- DE WEERDT Dirk
- D'HAESE Patrick
- GERYL Hilde
- HUFKENS Annemie
- LAMBERTS Ludwig
- MARIJNISSEN Rita
- NEVEN Ellen
- PERSY Veerle
- SPAEPEN Gie
- VERBERCKMOES Steven
- VERHULST Anja
- VERVAET Benjamin

FWO
IWT
EC
Univ Antw.

- **ROELS Frank**
  Pathology, Univ. Ghent, Belgium
- **SCHRYVERS Nick, YANG Zhiqing**
  Physics, Univ. Antwerp, Belgium
- **SUSINI J., SALOMÉ M.,**
  European Synchrotron Radiation Facility, Grenoble, France
- **DENTON J.**
  Musculoskeletal Res., Univ. Manchester, UK
- **McLEOD C., COX A.**
  Analytical Sc., Univ. Sheffield, UK
- **BLUST R., SELENS M.**
  Biology, Univ. Antwerp, Belgium

Melamine nephrotoxicity
an emerging epidemic in an era of globalization

FDA's warnings/advisories

- Fresh and Crispy Jacobina Biscuits
- Koala's March Crème filled Cookies
- YILI Brand Sour Milk Drink
- YILI Brand Pure Milk Drink
- Blue Cat Flavoured Drinks
- White Rabbit Candies
- Mr. Brown Mandheling Blend Instant Coffee (3-in-1)
- Mr. Brown Arabica Instant Coffee (3-in-1)
- Mr. Brown Blue Mountain Blend Instant Coffee (3-in-1)
- Mr. Brown Caramel Macchiato Instant Coffee (3-in-1)
- Mr. Brown French Vanilla Instant Coffee (3-in-1)
- Mr. Brown Mandheling Blend Instant Coffee (2-in-1)
- Mr. Brown Milk Tea (3-in-1)
- Infant formula manufactured in China

Bhalla V et al: Kidney Int 75: 774-9, 2009

The calcium-sensing receptor promotes urinary acidification to prevent nephrolithiasis

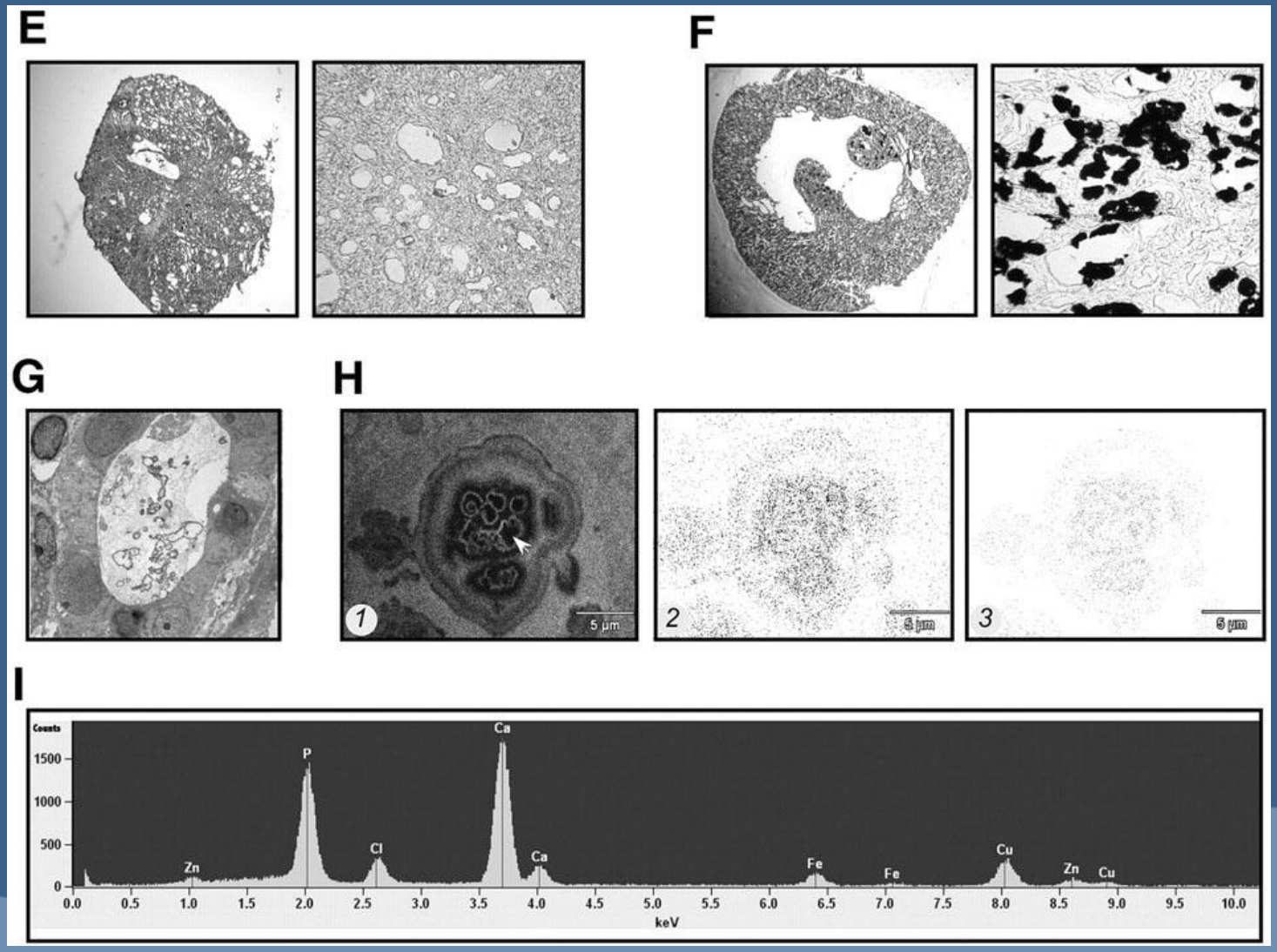

Renkema K et: JASN 20: 1705-13, 2009

Phenotypes of crystal containing tubules before and after ethylene glycol treatment

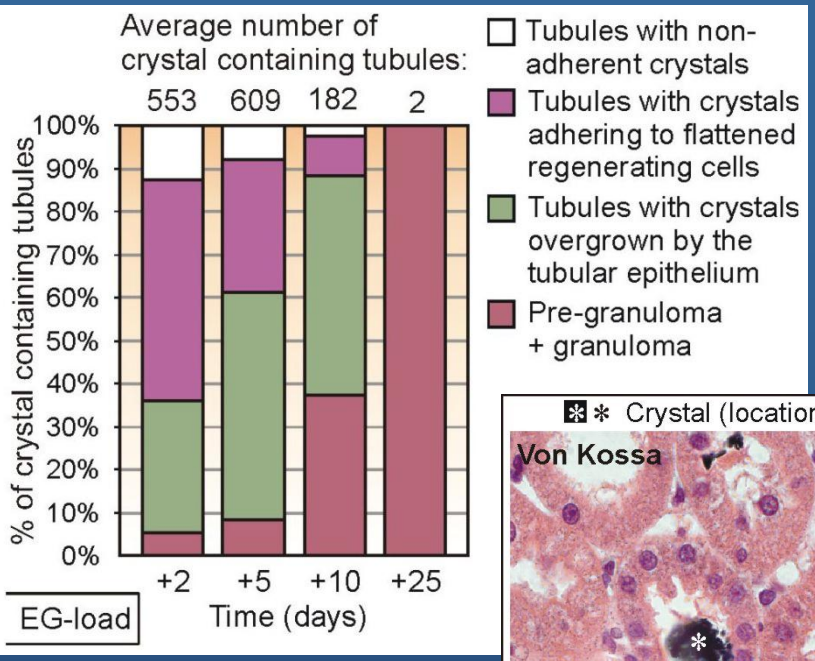

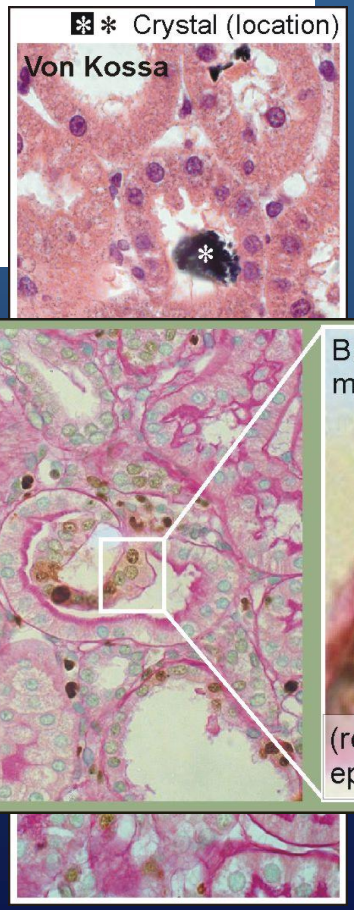

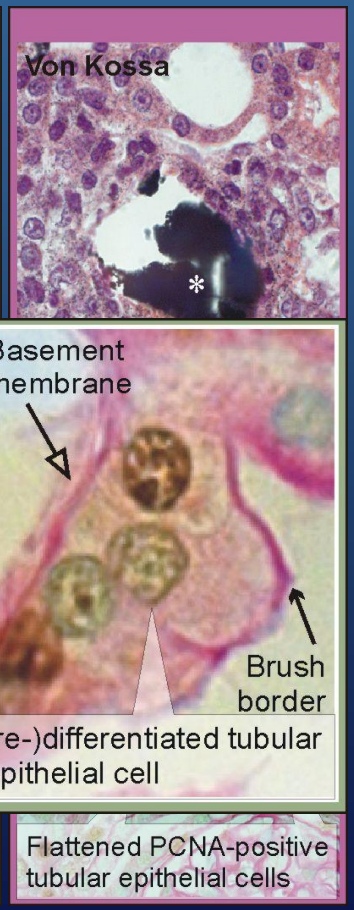

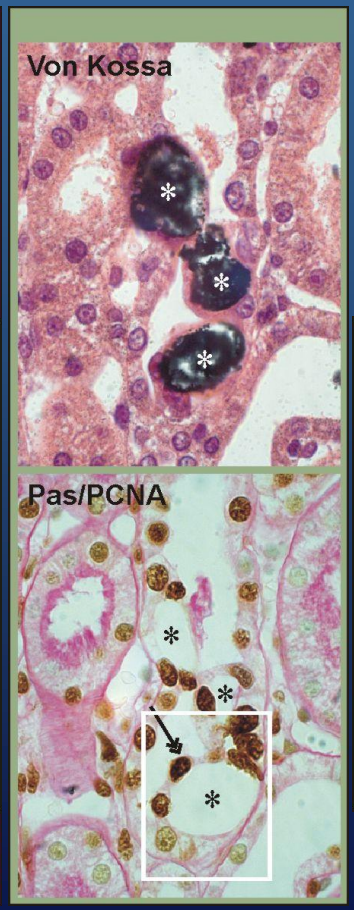

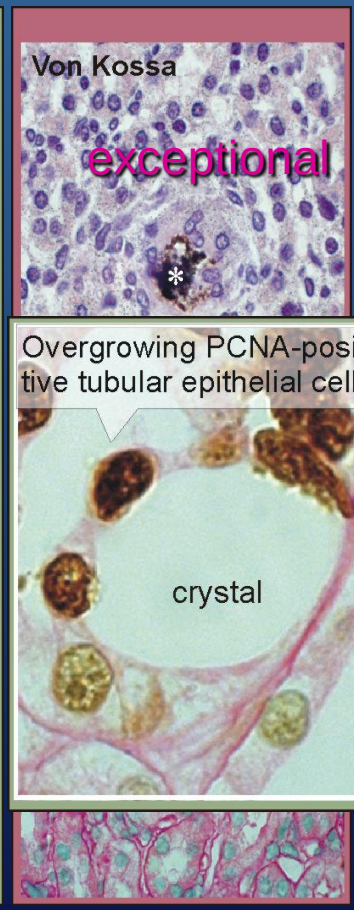

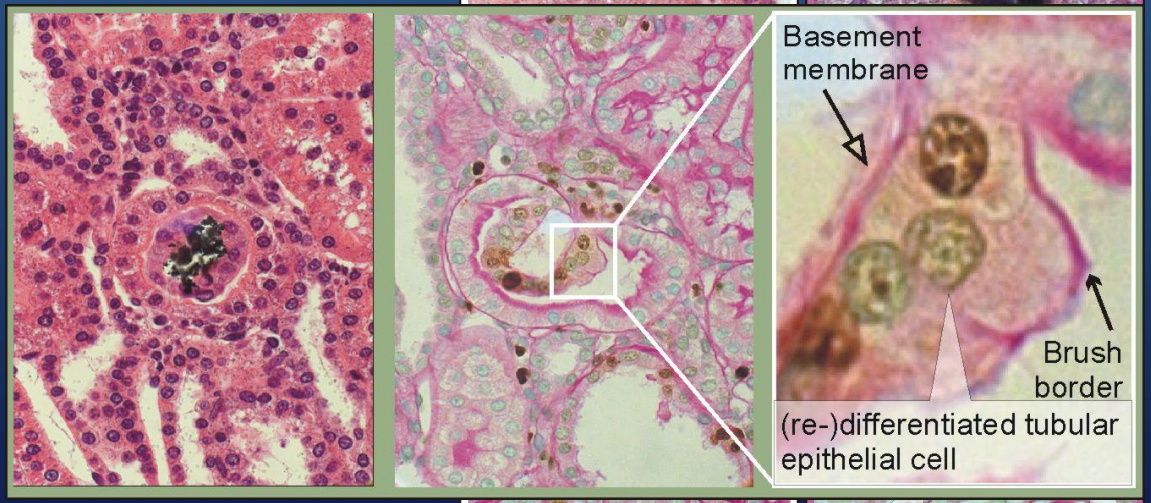

ENTERIC HYPEROXALURIA

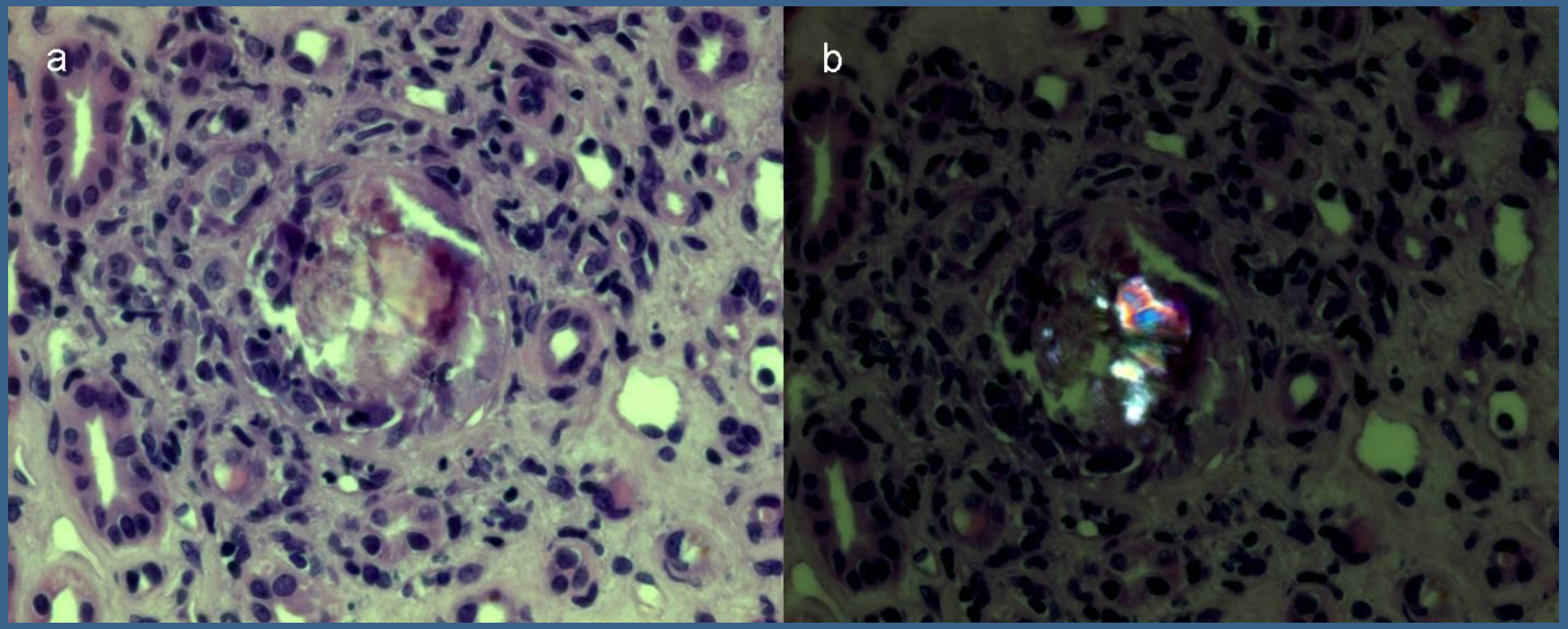

Serum creat 4.5 to 1.7mg/dl
Pipeleers et al 2011 NDT plus

Prof C Tielemans , Octobre 2010

Mechanisms in nephrocalcinosis and nephrolithiasis

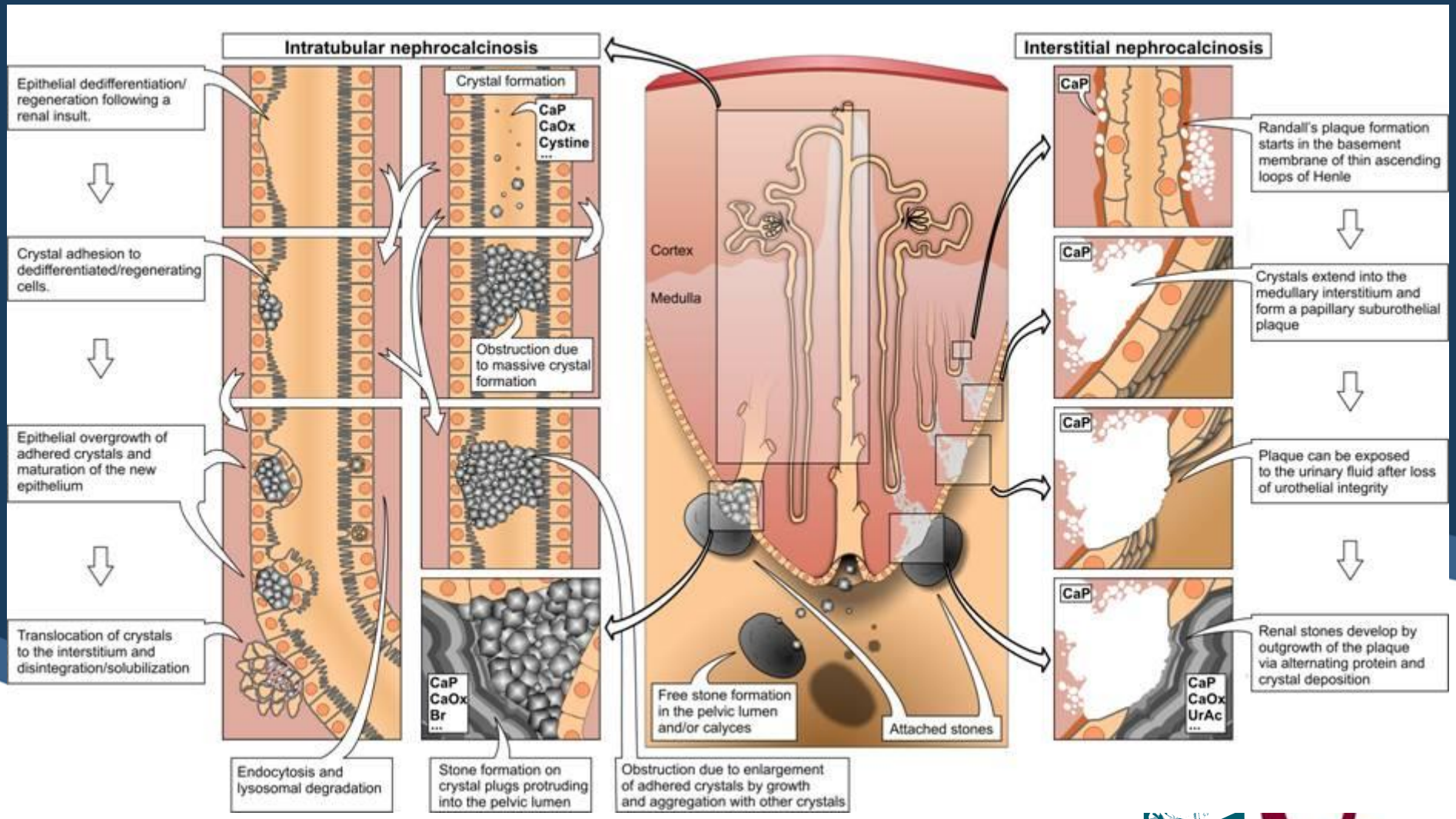

Vervaet et al Nephrol Dial Transplant (2009) 24:2030-35